

A slow growing pelvic actinomyces related abscess in a premenopausal patient mimicking genito-urinary malignancy - Case report and literature review

KREININ ANDREY¹, YAEL YAGEL², ALLA KHASHPER³, BOAZ SHEIZAF¹, DAVID YOHAY¹, ADI Y. WEINTRAUB¹

¹ Department of Obstetrics and Gynecology, Soroka University Medical Center, Faculty of Health sciences, Ben-Gurion University of the Negev, Beer Sheva, Israel.

² Infectious Disease Unit, Soroka University Medical Center, Faculty of Health sciences, Ben-Gurion University of the Negev, Beer Sheva, Israel.

³ Department of Clinical Radiology, Soroka University Medical Center, Faculty of Health sciences, Ben-Gurion University of the Negev, Beer Sheva, Israel.

Abstract: Actinomycosis in the pelvic region is an uncommon diagnosis. This infection in most cases is caused by *Actinomyces israelii*, a gram-positive anaerobic saprophyte bacterium, although other *Actinomyces* pathogens have also been reported. This bacterium is a normal inhabitant of the upper intestinal and genital tracts in humans. Pelvic actinomycosis is difficult to diagnose, and in many cases the preliminary suspicion is of a neoplastic process in the pelvic organs, as this infection may mimic pelvic and abdominal malignancies. We report a rare case of a 52-year-old female patient with a fixed pelvic mass within the vesico-vaginal fascia, located between the urinary bladder, uterine cervix and anterior vaginal wall. The diagnosis and treatment of pelvic actinomyces related inflammatory disease are discussed in this report. Care providers should be aware of this rare infection that is slow growing and may mimic a malignant process, leading to morbidity that can be caused by unnecessary treatment.

Keywords: Actinomyces Israeli; Pelvic abscess; Intrauterine device; Infection.

INTRODUCTION

Actinomyces is a gram positive, non-spore-forming anaerobic microaerophilic rod. *Actinomyces israelii* causes most Actinomyces infections in humans, although other forms such as *Actinomyces Odontolyticus*, *Actinomyces Viscosus*, *Actinomyces Meyeri*, *Actinomyces Gerencseriae*, and *Propionibacterium Propionicum* have also been reported to cause infections in humans¹. *Actinomyces israelii* is a part of oral and genital tract flora with infections being reported in the oral-cervicofacial, thoracic, abdominal, pelvic, central nervous system, musculoskeletal regions as well as causing disseminated disease. Actinomyces infections may also be polymicrobial, although in our case a single agent was suspected to cause the infection. We describe a rare case of a slow growing pelvic abscess, mimicking a uterine cervix malignancy in a premenopausal woman. The patient's history was remarkable for a longstanding neglected intrauterine device (IUD) of 15 years, which was removed two years prior to the diagnosis of an infection with Actinomyces.

CASE REPORT

A 52-year-old woman married and mother of three, was referred to the internal medicine emergency room (ER) due to severe abdominal pain and suspected urinary tract infection with bilateral moderate hydronephrosis that was diagnosed by ultrasound from an outpatient clinic.

During her evaluation in the ER the patient was found to have an elevated C-reactive protein (CRP) – 163 mg/L, leukocytosis $19 \times 10^3/\text{ul}$ and neutrophilia $14 \times 10^3/\text{ul}$. The urinary culture which was obtained two weeks earlier was sterile.

She was admitted to the hospital and an abdominal computerized tomography (CT) scan revealed bilateral hydronephrosis and a cystic or necrotic space occupying lesion located between the uterine cervix and urinary bladder, anterior to the vaginal wall. A thick and enhanced bladder wall was noted, accompanied by significant stranding of the adjacent fat. The origin of the lesion was uncertain, raising possibility of a genito-urinary malignancy (Fig. 1).

With these findings the patient was sent for a gynecological consultation. She complained of lower urinary tract symptoms

consistent with mixed urinary incontinence including stress incontinence, nocturia, frequency, urgency and dysuria that lasted for the past two months. No other complaints were reported by the patient. Her medical history was uneventful.

A gynecological transvaginal ultrasound examination demonstrated a non-cystic mass, which was also palpated through the anterior vaginal wall and measured 39x44 mm. It was mostly hypoechoic with hyperechogenic foci and surrounded by enhanced peripheral blood flow. However, the origin of the lesion was unclear. She was admitted to the gynecological ward. The vital signs were unremarkable: blood pressure 140/78 mm/Hg, temperature: 37.1°C, heart rate: 72 bpm. The laboratory findings were as follows: hemoglobin: 11.7 g/dl, white blood cells: $19.14 \times 10^3/\text{ul}$, neutrophils: $14.17 \times 10^3/\text{ul}$, C-reactive protein: 163.7 mg/dl. Other findings including the tumor markers such as CEA, CA 19-9, CA15-3, CA 125, were within normal limits.

Due to these findings the patient underwent a gynecologic oncologist consultation including a colposcopy. The uterine cervix appeared to be normal.

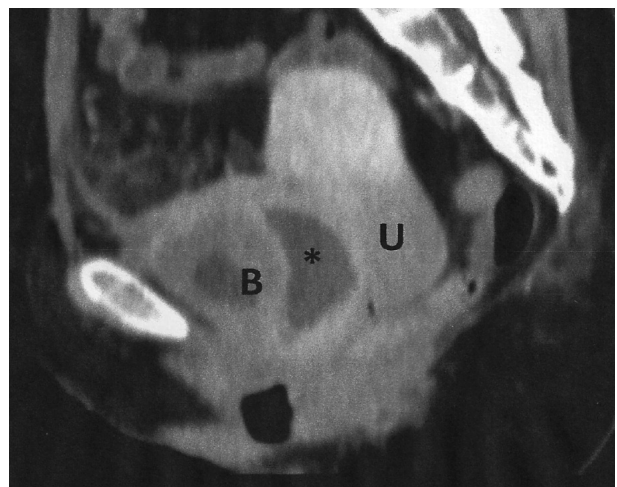


Figure 1. – The CT scan revealed necrotic mass (*) between urinary bladder (B) and uterine cervix (U), surrounded by fat stranding. The bladder wall is markedly thickened.

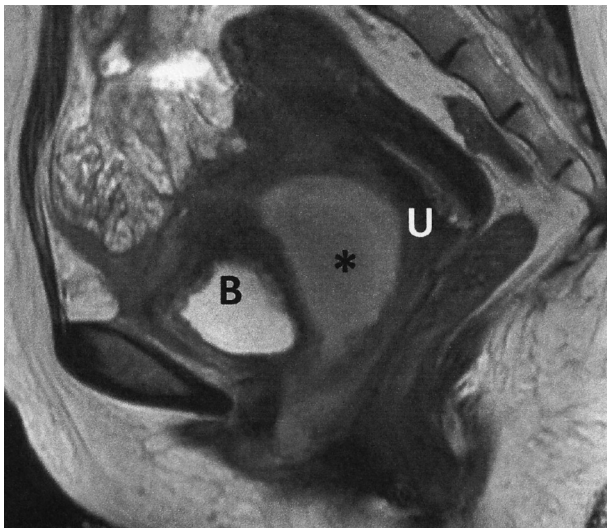


Figure 2. – A sagittal T2 weighted MRI shows the abscess (*) between urinary bladder (B) and uterine cervix (U). Uterine cervix is unremarkable.

Further evaluation included a cystoscopy which showed normal mucosa of the urinary bladder with no signs of malignant invasion. However, extrinsic compression probably due to the pelvic mass was noticed.

An abdominal MRI was performed. The study showed similar findings to those demonstrated on CT and ultrasound of a necrotic pelvic mass, localized behind the urinary bladder and anterior to the uterine cervix that was compatible with an abscess (Fig. 2). Significant inflammatory changes were seen in the urinary bladder walls, pelvic fat and adjacent small bowel loop. Small bowel perforation or another intestinal pathology such as Meckel's diverticulum were also suggested as possible explanations for the abscess formation. The uterine cervix was ruled out as a possible origin of the mass.

General surgeon consultation indicated that the possibility of gastrointestinal involvement was of low probability and assumed that the findings most probably originate from the genitourinary system due to marked urinary symptoms.

A decision was made to perform a CT guided aspiration of the abscess. During the procedure about 50 ml of pus were aspirated and sent to bacteriology (Fig. 3) and histopathology. After the drainage the patient reported a marked improvement in her symptoms. The patient was afebrile during the entire hospitalization period. She was discharged with a recommendation for antibiotic treatment for pelvic inflammatory disease and to continue follow up in the outpatient clinic.

Bacteriologic analysis of the abscess fluid was sterile, however the histopathologic findings showed branching filament formation consistent with Actinomyces infection and Actinomyces like bacterial colonies. During repeated anamnesis when asked specifically about an IUD, the patient reported that two years prior to admission, she had removed an IUD which was inserted 22 years earlier. A pathological specimen, sent from the uterine cavity at the time of extraction, revealed bacterial colonies compatible with Actinomyces, and antibiotic treatment was prescribed, but the patient did not take it. We do not have the information about the type of IUD. A repeated pelvic ultrasound revealed a collection of 30 ml.

Due to these findings suggestive of a slow growing abscess with Actinomyces together with an infectious disease specialist and consultant gynecologists the patient was readmitted for further treatment with intravenous antibiotics.

She was given three weeks of IV Penicillin G, 24 million units, divided every 4 hours. The patient continued antibiotic

treatment in the gynecologic unit. After 4 days of treatment, there was a decline in leucocyte count to the normal range: $10.38 \cdot 10^3/\text{ul}$, neutrophils: $7.23 \cdot 10^3/\text{ul}$. Other laboratory findings were also within normal limits. The patient's vital signs appeared normal: blood pressure 138/83 mm/Hg, temperature: 36.8°C , heart rate: 64 bpm, and the patient reported marked improvement in her urinary complaints. A PICC Line was inserted and the patient continued the treatment until it was stopped after she developed marked eosinophilia. The antibiotic treatment was changed to oral amoxicillin 500 mg, every 6 hours. The patient's symptoms resolved completely shortly after beginning treatment, and eosinophil levels decreased to near-normal values.

DISCUSSION

We report a rare case of Actinomyces abscess which was located in the vesicovaginal fascia, between the urinary bladder, uterine cervix and anterior vaginal wall, in a 52-year-old patient that two years previously had a neglected IUD removed.

The genus Actinomyces consists of several species such as Actinomyces Odontolyticus, Actinomyces Viscosus, Actinomyces Meyeri, Actinomyces Gerencseriae, and Actinomyces Israelii – which is the most common isolate in human disease. These bacteria are gram-positive, non-spore-forming bacteria, most of which grow at anaerobic conditions and tend to form branching filaments¹.

Actinomycotic disease is a rare diagnosis especially in developed countries. The overall annual incidence being 1: 100,000 to 1: 300,000, and due to unknown reasons, the rate is threefold higher in men. Most cases are seen in adolescents and middle-aged adults².

Actinomycotic infection may be associated with IUD usage. Chatwani and Amin - Hanjani³ in their study including 1,520 women with IUD, showed that the colonization rate increases with the duration of IUD use, reaching an overall colonization rate of 11.4%. The authors suggested that patients with IUD should undergo annual cytological smears³. Likewise, other data show that the incidence of IUD-associated pelvic actinomycosis is 1.65% to 11.6% of IUD users and infection is more common in women who have had an IUD for more than four years⁴.

Actinomyces israelii is a saprophyte found in various organs and in particular situations such as in mucosal lesion or in areas with a low oxygen level it becomes pathogenic. This

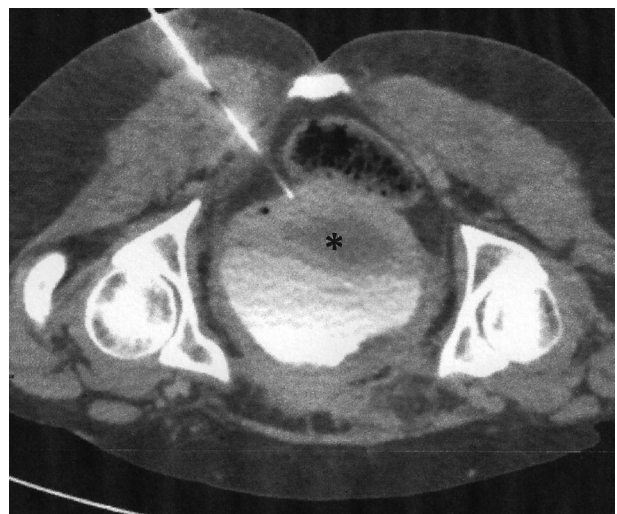


Figure 3. – CT scan obtained during imaging guided abscess drainage showed the needle placed into the abscess (*), avoiding damage of the rectum and major pelvic neuro-vascular structures.

condition allows the penetration of actinomyces through the mucosa and initiates an inflammatory process leading to the formation of abscesses and pseudo tumors. The abscesses tend to grow slowly and become symptomatic when they apply pressure on adjacent structures, form fistulas or perforate⁴.

Apart from IUD, some predisposing events for abscess formation may include previous bowel surgery and endoscopic manipulation, perforated gastric ulcers, loss of gallstones after laparoscopic cholecystectomy, trauma, diverticulitis, pancreatitis and immunocompromised patients⁴.

Actinomycosis abscess has been reported to affect the colon, ileum, ovaries, vulva, liver, abdominal wall, pancreas, greater omentum, retroperitoneum, kidney and abdominal wall⁴. However, to the best of our knowledge, this is the first report of an actinomyces abscess in the vesicovaginal fascia or the uterine cervix⁴.

The disease is characterized by an infiltrative and granulomatous inflammation, which may result in multiple abscesses, and sinuses that contain Sulphur granules. However, this is not always a pathognomonic sign, because other species such as *Staphylococci*, *Nocardia*, *Aspergillus* and *Streptomyces* can also form Sulphur granules⁵.

The differential diagnosis, in patients who present with an abdominal or pelvic mass depends on the patient's gender and age and includes: ovarian lesions, leiomyoma, ectopic pregnancy, pelvic inflammatory disease, appendicitis, diverticulitis, inflammatory bowel disease, and tuberculosis. A diagnosis of a malignant tumor of various structures is also frequently made. The ileocecal site is the most frequently affected in patients with abdominal actinomycosis⁵. The involvement of the vesicovaginal fascia located between the urinary bladder, uterine cervix and anterior vaginal wall, in this case made a diagnosis of genito-urinary malignancy even more reasonable.

Imaging findings of actinomycosis may vary greatly. Lesions may be single or multiple, and they may look like tumors, sometimes with foci of necrosis, or may present as abscesses. This behavior of the pathogen makes it very challenging to reach the correct diagnosis prior to an invasive intervention and as most cases of actinomycosis are based on tissue diagnosis⁶.

Preoperative diagnosis aided by aspiration or biopsy of the lesion as was done in our case, may avoid surgical intervention and unnecessary morbidity in patients affected by actinomyces. Actinomyces is a slow growing pathogen and in many cases the bacteriologic analysis is uninformative. In our case there were no positive cultures from aspirated pus, however histopathologic findings, which were positive for branching filaments consistent with Actinomyces infection and Actinomycosis like bacterial colonies, as well as a history of neglected IUD helped us in reaching the correct diagnosis.

In such cases an antibiotic treatment rather the operative approach is required.

The cornerstone of the treatment for actinomycosis is prolonged antimicrobial treatment with penicillin. The recommended antibiotic regimen is Penicillin G (18-24 million units/day) for 2-6 weeks. After several weeks of parenteral penicillin treatment, a prolonged treatment with amoxicillin for a 6-12-month period is advised, with or without surgical drainage for bulky disease⁵.

Where penicillin allergy exists, treatment with tetracycline, clindamycin, or doxycycline has been reported⁵.

In cases, when there is no benefit, and general health conditions continue to deteriorate after a week of antibiotic treatment or it is not possible to exclude a potential malignancy, surgery may also be required.

In the case presented here, the combination of a long-standing IUD heavily colonized with Actinomyces, together with a probable mucosal damage caused by the traumatic extraction of an

IUD, gave the pathogen an ability to cause an infection outside the uterine cavity. The long interval between IUD removal and the development of symptoms, points out to the unique infectious clinical syndrome caused by this organism. This highlights the importance of thorough history taking and specific questioning regarding long standing IUD presence in all patients with unexplained sub-acute symptoms and abnormal findings on pelvic imaging. The issue of whether to treat asymptomatic women with a histological finding of actinomyces colonies in the presence of IUD is still debatable, but in the presence of symptoms of endometritis – IUD removal and a short course of penicillin treatment is recommended. In our case, the patient had no clinical symptoms of endometritis at the time of IUD removal and the first evidence of actinomyces infection appeared two years later. We believe that antibiotic treatment given in the presence of actinomyces to prevent deterioration to a more serious infection is still a matter of clinical judgment, taking into account the time elapsed from the insertion of the IUD, and the traumatic potential of the extraction procedure.

In fact, pelvic actinomycosis is a rare chronic suppurative disease caused by Actinomycosis israelii and related species, that may result in an infiltrative mass lesion, which is often indistinguishable from malignancy at the beginning of the patient's evaluation.

In the majority of cases, a high index of suspicion is needed in order to reach a diagnosis. The diagnosis should be supported by a thorough anamnesis, imaging, bacteriology and histopathological findings, as in some cases only imaging and bacteriological findings are not enough.

The most challenging task for the management of actinomycosis is to reach a correct diagnosis before surgical intervention, as an accurate preoperative diagnosis is rare. However, if the diagnosis is promptly achieved, the gold standard treatment is based on prolonged high - dose antibiotic therapy, in particular penicillin, rather than a surgical approach.

DISCLOSURE STATEMENTS

There was no conflict of interest, informed patient consent was obtained.

REFERENCES

1. Russo TA. Agents of actinomycosis. Principles and Practice of Infectious Diseases. Mandell GL, Bennett JE, Dolin R, eds. 4th Ed. New York, NY: Churchill Livingstone; 1995: 2280-2288.
2. Sehoul J, Stypin JH, Schlieper U et al. Actinomycotic Inflammatory Disease and Misdiagnosis of Ovarian Cancer. A Case Report. Anticancer Research 2006; 26: 1727-1732.
3. Chatwani A, Amin-Hanjani S. Incidence of actinomycosis associated with intrauterine devices. J. Reprod Med 1994; 39: 585-587.
4. Acquaro P, Tagliabue F, Confalonieri G et al. Abdominal wall actinomycosis simulating a malignant neoplasm: Case report and review of the literature. World J Gastrointest Surg 2010; 2 (7): 247-250 ISSN 1948-9366 (online) © 2010 Baishideng.
5. McFarlane MEC, Coard KCM. Actinomycosis of the colon with invasion of the abdominal wall: An uncommon presentation of a colonic tumor. International Journal of Surgery Case Reports 2010; 1: 9-11.
6. Uehara Y, Takahashi T, Yagoshi M et al. Liver Abscess of Actinomyces israelii in a Hemodialysis Patient: Case Report and Review of the Literature. 2010 The Japanese Society of Internal Medicine.

Correspondence to:

Andrey Kreinin
Rager blvd, 151 - Beer Sheva 84101 - Israel
E-mail: dr.kreinin@gmail.com