

Acknowledgment: This paper is reprinted by permission of the ANZJOG journal.
Aust. NZ J Obst. Gynaecol 1996; 36: 3: 351-354

Severe chronic pelvic pain in women may be caused by ligamentous laxity in the posterior fornix of the vagina

PETER P. PETROS, D Med Sc, FRCOG, FRACOG, CU

Department of Gynaecology, Royal Perth Hospital, Western Australia

Summary: The aim was to prospectively study the relationship between pelvic pain of otherwise unknown origin and laxity in the posterior vaginal fornix. Twenty-eight patients with negative laparoscopy findings, lower abdominal pain and laxity in the posterior ligamentous supports of the uterus underwent surgical approximation of their uterosacral ligaments. At 3-month review, 85% of patients were cured, and at 12 months, 70%. Nonorganic pelvic pain has frequently been attributed to psychological factors. However, the results suggest that this may be a T12-L1 sympathetic pain referred to the lower abdomen, perhaps due to the force of gravity stimulating pain nerves unable to be supported by the lax uterosacral ligaments in which they are contained. It was concluded that laxity in the posterior ligaments of the vagina should first be excluded before referring patients with pelvic floor discomfort or pain for psychiatric care.

Key words: Chronic pelvic pain; Uterosacral ligaments; Surgical cure.

INTRODUCTION

Historically, laxity in the ligamentous supports of the uterus has been described as a cause of pelvic pain¹. However, opinions have varied, ranging from strongly delivered negation² to qualified acceptance³. In more recent years, pelvic pain without a commonly recognized organic cause has almost universally been attributed to psychological factors⁴. This concept has gained such widespread acceptance amongst practitioners, that surgical correction of a retroverted uterus has virtually disappeared from the operating lists of gynaecological surgeons. Sacral pain, lumbosacral backache, low abdominal pain, often unilateral, dyspareunia and postcoital ache²⁻⁶ are principal symptoms of such a condition, worsening during the day, and relieved by lying down, or by inserting a ring pessary^{3,6}. In these circumstances, ventrosuspension^{1-3,6} or hysterectomy^{3,6} may give good results.

Anecdotal reports (unpublished data) from patients cured of severe chronic pelvic pain following correction of uterovaginal prolapse and/or enterocele suggested that pelvic pain of hitherto unknown origin was frequently surgically correctable, and therefore may not have been primarily of psychological origin. The common factor in all instances appeared to be correction of laxity in the posterior ligamentous supports of the vagina.

The aim of this study was to prospectively trace the fate of low abdominal pain and deep dyspareunia after surgically tightening the ligamentous supports of the posterior vaginal fornix.

PATIENTS, MATERIALS AND METHODS

The study consisted of 28 patients, all of whom were referred with symptoms of pelvic pain. The mean age was 43 years (range 20-76), mean parity 3.1, (range 0-8). A routine history was taken, (including a structured questionnaire completed by the patient), and pelvic examination performed. In particular, the following specific symptoms were noted pain in the lower abdomen relieved on lying down, pain on deep penetration with intercourse, 'tiredness and irritability at the end of the day'.

Exclusion criteria. Known causes of pelvic pain such as chronic pelvic inflammatory disease, or endometriosis were excluded by prior laparoscopy.

Inclusion criteria for surgery. Lax ligamentous supports, specifically, the presence of uterosacral ligaments separated by more than 5 cm, with an enterocele 'bulge' of vaginal tissue in between protruding 2.5 cm or more on straining; alternatively, descent of the uterus by more than 5 cm on pulling gently on the cervix with a tenaculum; reproduction of the patient's lower abdominal pain by palpating the cervix.

Operation

All 28 patients studied had a posterior fornix repair (figure 1) performed as a day procedure, mainly under local analgesia, with the assistance of intravenous midazolam (dosage 5- 12 mg) administered by an anaesthetist. The patient was placed in the lithotomy position. The corners of the posterior fornix on each side of the uterosacral ligaments approximately 4cm below the posterior lip of cervix were gently grasped by Littlewood forceps without applying pressure. Using a long needle with a shield over the point, the operation site was infiltrated with 5-10 mL of 0.5% lignocaine with 1/200,000 adrenalin. Under tension from the forceps, a full thickness 5 cm horizontal vaginal incision was made between the tips of the forceps using a scalpel. The points of long-handled scissors were inserted into the incision, stretching it in an anteroposterior plane. If possible, the uterosacral ligaments were identified, approximated in the midline, followed down posteriorly and further approximated with No 1 Vicryl. The needle point was frequently used to locate the often deeply set ligaments, pulling them to the midline, along with the vaginal epithelium which was approximated side to side i.e. vertically. No vaginal tissue was excised.

Care was taken not to create excessive tension, so as not to cause postoperative pain to the patient. If an enterocele or high rectocele were present, they were appropriately repaired at the same time. A 0.5 x 0.5 cm biopsy of the uterosacral ligament was performed in 12 patients. With this operation the vaginal axis remains unchanged. Excess

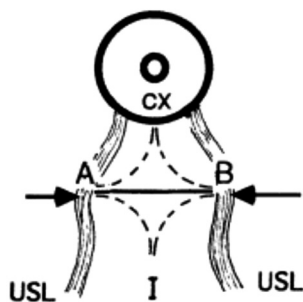


Figure 1. – Surgical correction of laxity in the posterior vaginal fornix. A full thickness transverse incision (solid line) is made in the vagina at the apex of the enterocele bulge, between A and B, the borders of the uterosacral ligaments (USL), 4-5 cm below the cervix (CX). The vagina is separated from the underlying tissues anteroposteriorly (broken lines) without entering the enterocele sac, and the incision further opened out by insertion of a Sim's speculum between the cervix (CX) and introitus (I). The uterosacral ligaments are automatically tightened by approximating A to B, and by suturing them and the horizontal vaginal incision vertically between the cervix and introitus. No tissue is excised.

TABLE 1. Details Assessed in Questionnaire.

Questionnaire	YES	NO
Do you have deep pain on intercourse?	()	()
Do you have a pain down at the bottom of your spine?	()	()
Do you have a pain down at the bottom of your abdomen?	()	()
Do you feel tired and irritable at the end of the day?	()	()

width (vaginal prolapse, enterocele) is converted to length. The process is one of anatomical restoration, not alteration.

Postoperative assessment

No patients were lost from the study. The post-operative assessment was performed, using the questionnaire (Table 1), personal interview, and examination, immediately post-operatively, at 3 months, and 12 months.

Notes on methodology

Initially, a subjective analogue scale of 1-10 was considered and commenced. However, difficulties were experienced in putting this into effect, principally because preoperatively the character of the pain was such, that it varied considerably from time to time as concerns intensity. On discussing this with the initial group of patients, it was concluded that the criterion for cure should be all-or none. This appeared to work very well, as pain relief from a successful operation was immediate and dramatic.

RESULTS

Description of lower abdominal pain

In its acute state of manifestation, the pain was invariably severe, frequently one-sided, situated low in the right or left iliac fossa, usually relieved on lying down, frequently relieved by insertion of a ring pessary, and reproducible on palpating the cervix and displacing it posteriorly with the patient in the supine position. Although the pain was chron-

ic in nature, it varied considerably from time to time as concerns intensity. Six patients (two of whom were nulliparas) entered the study through casualty as emergency pain becoming sufficiently acute at time as to seek emergency care. Almost all patients complained of tiredness and irritability by the end of the day. A ring pessary considerably relieved the symptoms in approximately half of the patients, but on occasions, if the pessary was too small, it fell out, or no effect was noted: if too large, the symptoms frequently worsened.

Description of deep dyspareunia

This symptom was not often volunteered. The pain only occurred on deep penetration, or in specific positions. Frequently the patient complained of a constant lower abdominal pain the day after intercourse. Again, palpation of the cervix generally reproduced the pain experienced during intercourse.

Surgical results

At laparoscopy, varicosities were frequently seen in the region of the uterosacral ligaments, and also, broad ligament. After posterior fornix repair, cure, where effected, was instant and dramatic. The cure rate for lower abdominal pain at 3 months was 85%, and at 12 months 70%. Almost all patients returned to normal activities within days of the operation, with no specific instructions other than to avoid heavy lifting and intercourse for 6 weeks. Approximately 50% of patients who were cured of their low abdominal pain also reported cure of their low sacral backache.

Histology

Histological examination typically demonstrated the presence of smooth muscle, collagen, elastin, and nerve endings, both myelinated and unmyelinated in all specimens examined.

DISCUSSION

This pain was described by patients as intolerable, and was almost invariably associated with a lack of gross laparoscopic findings. Many stated that they were almost suicidal after interminable attacks of pain. The results confirm that laxity in the posterior vaginal fornix may be associated with pelvic pain and dyspareunia^{1,3,6}, and that such pain is potentially curable with a minor surgical procedure, undoubtedly a preferable alternative to hysterectomy. Occurrence of this condition in nulliparas indicates that such laxity may occur congenitally. Recurrence of symptoms appeared to be associated with recurrence of laxity i.e. it is possible that surgical failure may have been partly due to the damaged quality of the tissues being repaired. Subsequent cure of pain in some of these patients following sacropexy (unpublished data) appeared to confirm the hypothesis of this type of pelvic pain being caused by laxity in the posterior ligamentous supports of the vagina. Cure of similar pain in patients with prior hysterectomy has also been achieved using similar surgical methods (unpublished data).

A hypothesis for pathogenesis of the pain

The nerve fibres in the uterosacral ligaments are visceral fibres. A visceral innervation incorporating fibres from T12-L1 and S2-4 adequately explains anatomical distribution of the pain. It is hypothesized that stretching of lax ligaments by gravity may stimulate the nerve endings within these tissues, and cause pain. Lying down would relieve

such pressure, and the associated pain, as noted in this study. A ring pessary may work by providing mechanical support for the ligaments, and therefore, the nerve endings contained within. Findings of pelvic congestion are explained as follows: the uterus is normally supported by the cardinal and uterosacral ligaments, possibly assisted by contraction of the pelvic floor muscles. It is hypothesized that where the supporting ligaments are lax, the force of gravity acting on the uterus could cause congestion by 'kinking' of the pelvic veins within these tissues, preventing outflow, thereby causing congestion.

Psychological aspects

The improvement in patients' sense of well-being and psychological state was immediate and obvious. Given the high surgical cure rate in this study, 'functional' or psychological causation^{2,4} is most likely a secondary, not a primary manifestation, *at least in the 70% of patients cured by this procedure*. Chronic pain may cause tiredness and irritability⁶, decreasing libido and creating marital stress and depression, all of which, in another context, could be interpreted as psychological associations, or even causes.

It is recommended that laxity in the posterior ligaments of the vagina should first be excluded before referring patients with severe chronic pelvic pain or dyspareunia for psychiatric care.

ACKNOWLEDGEMENTS

I wish to thank Mrs Carole Yelas for her assistance in preparation of this manuscript, specialist incontinence nurse Margaret Young for assistance in gathering and com-

piling the data, and Professor Byron Kakulas for the histology, and advice concerning the neuropathology of this condition.

REFERENCES

1. Martius H as quoted by Nijs P. Psychological aspects of pelvic pain experience. In *Chronic Pelvic Pain in Women*, Springer - Verlag Berlin ED Renner M, 1981: 24-37.
2. MacLeod D, Howkins J (Eds). Remote results of gynaecological operations. In *Bonney's Gynaecological Surgery*, 7th Ed 1961. Bailliere. Tindall and Cassell, London. 648-658.
3. Te Linde RW, Mattingly RF. *Operative Gynecology*. 4th Ed, Eds Te Linde RW, Mattingly RF JP Lippincott Company, Phil 1970; 469-533.
4. Beard R, Reginald P, Pearce S. Psychological and somatic factors in women with pain due to pelvic congestion. *Br J Obstet Gynaecol* 1988; 245: 413-421.
5. Beard R, Reginald P, Wadsworth I. Clinical features of women with chronic lower abdominal pain and pelvic congestion. *Br J Obstet Gynaecol* 1988 95: 153-161.
6. Hastwell GB. Psychogenic pelvic pain or the Occult Prolapse Syndrome. *Med J Aust*, 1986; 144: 405-407.

Correspondence to:
pp@kvinno.com