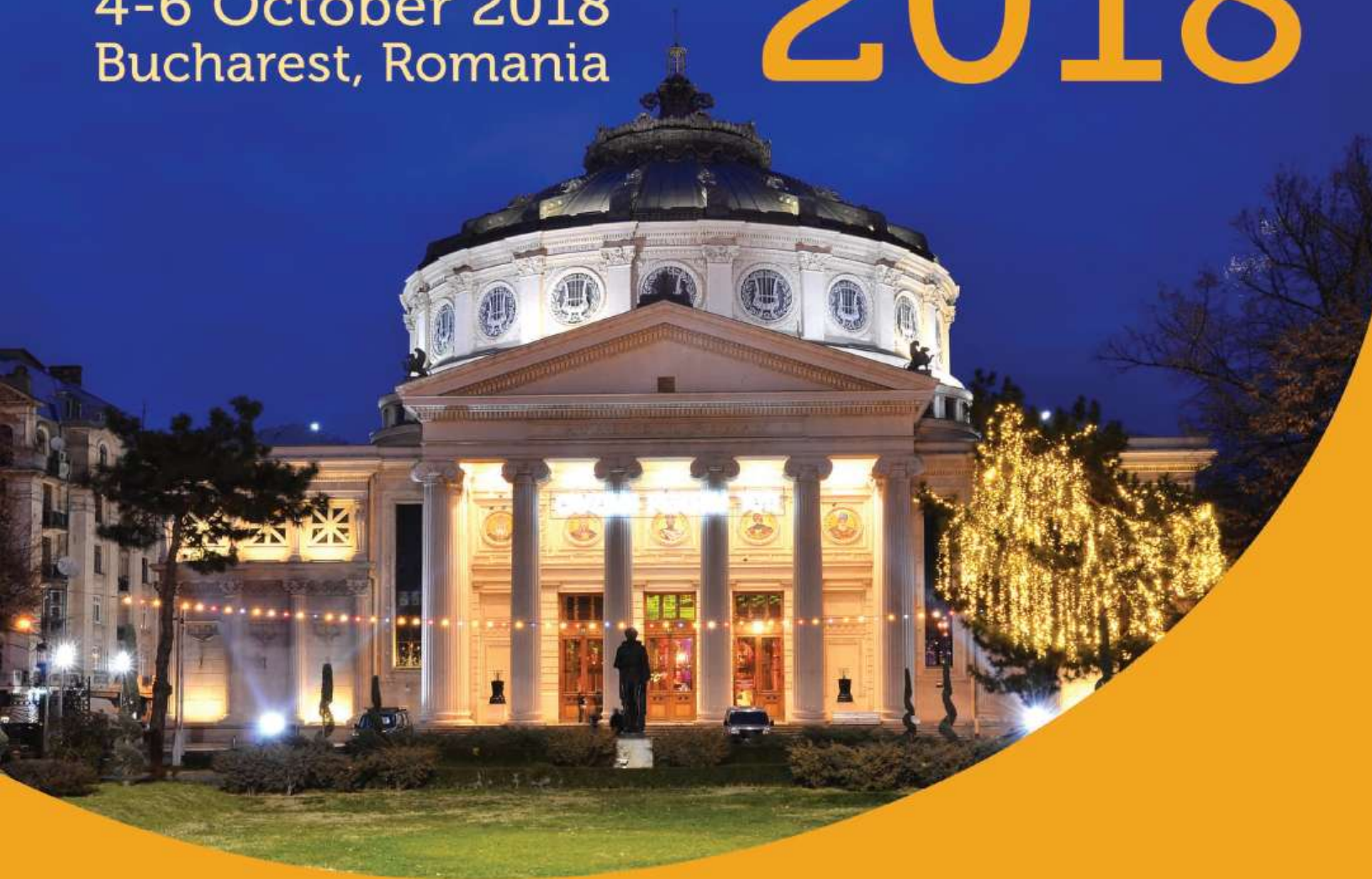



# THE INTERNATIONAL SOCIETY OF PELVIPERINEOLOGY CONGRESS

4-6 October 2018  
Bucharest, Romania

# 2018



## Abstracts Book

## **ISPP Organizing Committee**

Prof. Dr. Akın Sivaslıoğlu (Turkey)  
President of the International Society of Pelviperineology

## **Local Organizing Committee**

Prof. Dr. Elvira Brătilă (Romania)  
Congress President  
President of the Romanian Society of Urogynecology

Prof. Dr. Monica Cîrstoiu (Romania)  
Vice-president of the Romanian Society of Urogynecology

## **International Faculty**

Burghard Abendstein (Austria)  
Erkut Attar (Turkey)  
Nida Bayık (Turkey)  
Liedl Bernhard (Germany)  
Elvira Brătilă (Romania)  
Petre Brătilă (Romania)  
Gheorghe Bumbu (Romania)  
Eray Caliskan (Turkey)  
Emanuel Delorme (France)  
Giuseppe Dodi (Italy)  
Bruce Farnsworth (Australia)  
Christian Funfgeld (Germany)  
Klaus Goeschen (Germany)  
Oscar Horky (Australia)  
Ates Karateke (Turkey)

Hansjorg Keller (Germany)  
Yakup Kumtepe (Turkey)  
Naama Marcus-Braun (Israel)  
Sidi Muctar (Germany)  
Andrei Muller Funogea (Germany)  
Menahem Neuman (Israel)  
Jorge Neymer (Germany)  
Peter Petros (Australia)  
Leila Salimova (Russia)  
Giulio Santoro (Italy)  
Akın Sivaslıoğlu (Turkey)  
Tolgay Tüyan İlhan (Turkey)  
Peter Von Theobald (France)  
Adi Weintraub (Israel)  
Carl Zimmerman (USA)

# ISPP Abstracts Book Summary

Single incision mini-slings: fact or myth? .....	8
Nida Bayık .....	8
Rethinking vaginal native tissue surgery .....	8
Adri Niemwondt .....	8
Tethered vagina.....	8
Klaus Goeschen .....	8
A standardized international training program is much needed for the future of the urogynecology profession.....	8
Joerg Neymeyer .....	8
The elevation angle of the vagina (EAV) following different pelvic reconstructive procedures .....	9
Neymeyer Joerg, Weintraub AY, Weinberger S, Moldovan DE, Kornienko K, Schlomm T .....	9
Postpartum recovery from pelvic floor dysfunction symptoms during pregnancy .....	10
Adi Weintraub.....	10
Investigation of chronic pelvic pain and painful retroverted uterus.....	10
Peter von Theobald, Julie Eggermont, Anca Birsan .....	10
Should we all go for laparoscopic sacrocolpopexy if we want to use mesh for pelvic organ repair?.....	10
Peter von Theobald, Julie Eggermont, Anca Birsan .....	10
Three-dimensional endoanal ultrasound in obstetric anal sphincter injuries .....	10
Giulio A. Santoro .....	10
Applied and ultrasound anatomy of the pelvic floor.....	11
Giulio A. Santoro .....	11
Fecal incontinence .....	12
Sidi Muctar.....	12
The role of hysterectomy in pelvic organ prolapsus surgery .....	12
Eray Çalışkan .....	12
To mesh or no-mesh surgery in pop treatment?.....	13
Salimova Leila Ya, Shalaev O.N. ....	13
The role of the posterior Compartment of the vagina for defecation disorders .....	13
Burghard Abendstein .....	13
Single Incision Vaginal Tape for Lateral Detachment Repair. A Pilot Study and The Description of The Method.....	13
Balint Farkas <sup>1</sup> , Miklos Szakacs <sup>1</sup> , Christian Goepel <sup>1</sup> .....	13
Vaginal Sacropexy Achieved By Eight Tension-Free Fixing Arms Mesh- Preliminary Results .....	14
Christian Goepel <sup>1</sup> , Miklos Szakacs <sup>1</sup> , Balint Farkas <sup>1</sup> .....	14

Experimental work on a new vaginal single port robot .....	14
Peter von Theobald, D. Coen, M. Neuman .....	14
Pelvic organ prolaps using a six tension free strap low weight transvaginal mesh: long term retrospective monocentric study of 311 patients .....	15
Emanuel Delorme .....	15
Bilateral plication of the puborectalis muscles: a novel surgical concept for treating vulvovaginal widening.....	15
Emanuel Delorme .....	15
Concepts to treat urethral stricture disease .....	16
Hansjörg Keller, Jörn Beier .....	16
Long-term results of the urethroplasty using oral mucosa graft: a series of more than 1000 consecutive patients .....	16
Anna-Maria Barta-Kelemen Mikhail Borisenkov, Jörn Beier, Hansjörg Keller.....	16
Surgical repair of recurrent bladder neck obstruction after radical prostatectomy via a perineal approach.....	17
Hansjörg Keller, Jörn Beier .....	17
Radical perineal prostatectomy and extended perineal pelvic lymph-node- dissection via the same incision.....	18
Hansjörg Keller, Jörn Beier .....	18
Radiofrequency in gynaecology.....	18
Oscar Horky .....	18
Long lasting symptom cure by pelvic floor surgery depends on successful longlasting prolapse repair ..	18
Bernhard Liedl, A. Yassouridis, S. Sutherland, J. Lukban, JP Roovers, E Stanford .....	18
Closing the gap between the conservative and the surgical therapy of the genital laxity: the radiofrequency approach.....	19
Andrei Müller-Funogea .....	19
Sacrocolpopexy : Advantages and disadvantages - a systematic literature review.....	20
Dumitrașcu Mihai Cristian, Albu Ruxandra Andreea. Fodoroiu Răzvan, Nenciu Cătălin George, Nenciu Adina, Gorgoi Corina Oana, Cîrstoiu Monica Mihaela .....	20
Excess of vaginal tissue in POP: a bond between the use of mesh versus native tissue repair in POP reconstructive surgery .....	21
Serban Nastasia, Roxana Bohiltea, Elvira Bratila, Monica Carstoiu, Manuela Cristina Russu.....	21
Sequential versus concomitant surgery in cystocele with stress urinary incontinence .....	21
Diculescu Doru, Fulga Florescu, Todea Cezarin, Ciortea Razvan, Malutan Andrei, Bucuri Carmen, Pop Daria, Rada Maria, Iuhas Cristian, Mocan-Hognogi Radu.....	21
Transperineal intrapartum ultrasound. What is the aim? .....	21
Dominic Iliescu <sup>1,2</sup> , Stefania Tudorache <sup>1</sup> , Roxana Dragusin <sup>1,2</sup> , Ciprian Patru <sup>1,2</sup> .....	22

Haemorrhoids in females – a consequence of impaired blood flow associated with pelvic organ prolapse? .....	22
Traian Enache .....	22
The place of hysterectomy in the management of uterine prolapse: Is it actually necessary? Pros and Cons .....	22
Pirtea Laurentiu, Balint O., Secosan C., Grigoras D.....	22
Laparoscopic promonto hysteropexy - the six points technique .....	23
Pirtea Laurentiu, Balint O., Secosan C., Grigoras D.....	23
Laparoscopic lateral suspension using a mesh in the treatment for pelvic organ prolapse, an alternative method for vaginal hysterectomy.....	23
Dumitrașcu Mihai Cristian <sup>1</sup> , Fodoroiu Răzvan <sup>1</sup> , Nenciu Cătălin George <sup>1</sup> , Nenciu Adina <sup>1</sup> , Albu Ruxandra Andreea <sup>1</sup> , Pariza George <sup>1</sup> , Cîrstoiu Monica Mihaela <sup>1</sup> .....	23
Chronic pelvic pain, incontinent pelvic vein relationship.....	23
Liana Ples <sup>1,2</sup> , Mircea Octavian Poenaru <sup>1,2</sup> , Octavian Gabriel Olaru <sup>1,2</sup> , Anca Daniela Stanescu <sup>1, 2</sup> .....	23
The genitourinary syndrome of menopause.....	24
Corina Grigoriu, Corina Neamtu, Madalina Musat, Rares Simu, Steluta Georgescu-Mariutan, Diana Munteanu, Luciana Oprea, Mircea Ichim, Alice Lavinia Balaceanu.....	24
Single incision sling (mini-sling) for treatment of stress urinary incontinence: 2 years experience of Erciyes University.....	24
Iptisam Ipek Muderris.....	24
A rare case report: Meckel–Gruber syndrome. Case report.....	25
Iptisam Ipek Muderris.....	25
Management of proctologic complications in obstetrics. ....	25
Tomasz Koscinski .....	25
Iliococcygeal fixation as an alternative vaginal surgical technique for anterior compartment repair .....	25
Derya Kilic <sup>1</sup> , Tolga Guler <sup>1</sup> , Akin Sivaslioglu <sup>2</sup> .....	25
The tissue fixation system for very elderly patients under local anesthesia on the outpatient basis.....	27
Yuki Sekiguchi.....	27
What equipments will remain among energy exposure treatments for genital area .....	27
Yuki Sekiguchi, Ryoko Nakamura, Noriko Ninomiya and Yukari Usugisawa.....	27
In-Vitro Anticandidiasis Effect of the Komboucha Extract on Candida Albicans Isolates From Vaginnal Secretion .....	28
Fasie Valeria <sup>1</sup> , Robu Silvia <sup>1</sup> Mardare Nela <sup>1</sup> Diaconu Camelia <sup>1</sup> .....	28
Considerations on the in vitro inhibitor effect of komboucha on pseudomonas aeruginosa isolates from the urethral and periurethral area in women .....	29
Fasie Valeria <sup>1</sup> , Robu Silvia <sup>1</sup> Mardare Nela <sup>1</sup> Diaconu Camelia <sup>1</sup> .....	29
Positive inhibitive action of komboucha extract on E.Coli isolated from perivaginal and vaginal tract ....	29

Fasie Valeria <sup>1</sup> , Robu Silvia <sup>1</sup> Mardare Nela <sup>1</sup> Diaconu Camelia <sup>1</sup> .....	29
Development of POP-related Symptoms, Quality of Life, Anatomical Results and Side Effects after Cystocele Correction with an Improved Titanized Mesh .....	30
C. Fünfgeld <sup>1</sup> , T. Cadenbach-Blome <sup>2</sup> , M. Mengel <sup>3</sup> , M. Grebe <sup>4</sup> and F. Pauli <sup>5</sup> .....	30
Sacrocolpopexy: Advantages and disadvantages - a systematic literature review.....	31
Dumitrașcu Mihai Cristian, Albu Ruxandra Andreea. Fodoroiu Răzvan, Nenciu Cătălin George, Nenciu Adina, Gorgoi Corina Oana, Cîrstoiu Monica Mihaela.....	31
Combination of slings and site-specific fascial POP repair. Multicenter study.....	32
Boris Slobodyanyuk1, YULia Dobrokhotoval, Svetlana Kamoeva2, Alexander Slobodyanyuk3, Valentina Dimitrova4, Sergey Apressyan4.....	32
Vaginal reconstruction and laparoscopic Kapanji suspension is a good option for advanced apical POP in young patients .....	33
Alexander Slobodyanyuk 1, Boris Slobodyanyuk 2, YULia Dobrokhotova 2. ....	33
Initial experience of Restorelle® direct fix anterior mesh in treatment of pelvic organ prolapse .....	33
Jill Cheng Sim Lee, Shu Qi Tan, Jolene Sin Se Peh, How Chuan Han .....	33
Transperineal ultrasound as a complementary tool in the assessment of urinary incontinence in women .	34
Rada Maria Patricia 1 , Ciortea Răzvan 1 , Măluțan Andrei Mihai 1 , Oancea Mihaela 1, Mocan-Hognogi Radu 1, Bucuri Carmen Elena 1, Mihu Dan 1 .....	34
Predisposing factors for uterine fibroid .....	35
Duca Oana Monica, Lupu Mary-Nicoleta, Matei Madalina, Aurel Nechita.....	35
Innovative vaginal cones with vibrating ball inside in pelvic floor dysfunction .....	35
Federico Villani <sup>2</sup> , E. Moratti <sup>2</sup> , B. Minopoli, A. Guglielmino, L. Arduini, A. Fatuzzo, A.L. Tataru, C Furuu. ....	35
Application of titanium mesh in reconstructive surgery of POP .....	37
Svetlana Kamoeva, Anton Kazantsev <sup>1</sup> , Alexander Alekhin <sup>1</sup> , Boris Slobodyanyk <sup>2</sup> , Yulia Dobrokhotova <sup>2</sup> , Tatiana Ivanova1, Ekaterina Panova1. ....	37
Perspectives of Pelvic Minority in Croatia - Croatian Pelvic Society .....	38
Rajko Fureš <sup>1,4</sup> , Damir Hodžić <sup>4,5</sup> , Jadranka Šanjug <sup>1,4</sup> , Ivica Balagović <sup>1,4</sup> , Tonći Visković <sup>1,4</sup> , Martin Gredičak <sup>1,4</sup> .....	38
Midurethral sling TOT procedure for the treatment of stress urinary incontinence – our experience.....	39
Mircea Octavian Poenaru <sup>1,2</sup> , Braicu Flavia <sup>2</sup> , Anca Daniela Stanescu <sup>1,2</sup> , Liana Ples <sup>1,2</sup> .....	39
Transvaginal versus transperineal ultrasound in the evaluation of the cervix after cerclage.....	39
Olaru Octavian Gabriel <sup>1,2</sup> , Romina Marina Sima <sup>1,2</sup> , Liana Ples <sup>1,2</sup> .....	39
What else can be done in preventing stress urinary incontinence?.....	40
Corina Grigoriu, Steluta Mariutan-Georgescu, Mirela Mihaila, Lucica Visan, Diana Munteanu, R. M. Grigoriu.....	40
Recurrent stress urinary incontinence after primary surgical treatment .....	40
Corina Grigoriu, Corina Parau, Lucica Visan, Diana Munteanu, Mihai Grigoriu .....	41

Bladder Pain Syndrome / Interstitial Cystitis (BPS/IC), a multidisciplinary approach .....	41
Andrei Manu-Marin .....	41
QoL after Cystocelerepair .....	41
C. Fuenfgeld <sup>1</sup> , M. Grebe <sup>2</sup> , B. Henne <sup>3</sup> , J. Kaufhold <sup>4</sup> , M. Mengel <sup>5</sup> , M. Stehle <sup>1</sup> , D. Watermann <sup>6</sup> .....	41
1 Klinik Tett nang, Tett nang, Germany .....	41
Tissue fixation system (TFS) sling operation to repair pelvic organ prolapse in women of 80 years and older .....	42
Hiromi Inoue .....	42

## **Single incision mini-slings: fact or myth?**

*NIDA BAYIK*

*drnidaergin@gmail.com*

Stress urinary incontinence is a common complaint occurring up to one third of women worldwide. Therefore, anti-incontinence surgeries are popular. Mid-urethral slings (namely tension-free vaginal tape (TVT) and trans-obturator tape (TOT)) provides success rates approximating 80-90% with some co-morbidities like severe bleeding, bladder perforation, urethral erosion or chronic thigh/groin pain with varying frequencies. The single incision mini-slings are designed with shorter length and penetration depth to have fewer side effects with similar efficacy. In this presentation, the efficacy of single incision mini-slings will be discussed comparing to the standard slings as well as their side effects comparing to the standard slings.

## **Rethinking vaginal native tissue surgery**

*ADRI NIEMWONDT*

*nieuwoudt@gmail.com*

With the current controversy surrounding the usage of synthetic materials in vaginal surgery, one need to take a step back and rethink native tissue surgery. The native tissue surgery of yesteryear which prompted the substitution of the vaginal wall fascia by synthetic materials was because the fascia and native tissue were disrespected in surgery, as is the underlying defects in the fascial support. With Tissue Guided Regenerative (TGR) surgery a step into the future is taken: the tissue guides the surgeon to the defect present, which in turn direct the surgeon to the specific repair of this native tissue that is needed. All this is done following regenerative surgical principles which will lead to minimal scar tissue formation and good regeneration of native tissue back to the pre-injury state, utilizing residential mastcells. In this lecture the theory is brought into practise with surgical video demonstrations and result obtained through 10 years of meticulous research through surgical auditing into technical aspects of TGR surgery.

## **Tethered vagina**

*KLAUS GOESCHEN*

*klaus.goeschen@googlemail.com*

The tethered vagina syndrome is an iatrogenic condition caused by scar-induced tightness in the bladder neck area of the vagina. The classical symptom is commencement of uncontrolled urine leakage as soon as the patient's foot touches the floor on getting out of bed in the morning. This situation is somewhat similar to "motor detrusor instability", and so is considered as being incurable. 1990 Petros described a new strategy for treatment. The first step is to free all scar tissue from urethra and bladder neck, the second to increase the tissue in the bladder neck area of vagina, thereby restoring elasticity.

## **A standardized international training program is much needed for the future of the urogynecology profession**

*JOERG NEYMEYER*

*Charite University Medical Center, Berlin, Germany*

*joerg.neymeyer@web.de*



Charite, Berlin Germany, is a place where leading scientists, academicians and doctors come together to learn from each other to get and give advice and share their experience and proficiency.

We have created a unique fellowship program that includes lectures and master classes for professionals in the field of pelvic floor reconstructive medicine. The program focuses on the major breakthroughs and challenges in the field of pelvic floor medicine and reconstructive surgery.

The program has accepted professionals from obstetrics and gynecology, urology, urogynecology, and colorectal surgery. This fellowship is a hands-on surgical program incorporating academic debate and research.

## The elevation angle of the vagina (EAV) following different pelvic reconstructive procedures

NEYMEYER JOERG, WEINTRAUB AY, WEINBERGER S, MOLDOVAN DE, KORNIENKO K, SCHLOMM T

Charite University Medical Center, Berlin, Germany

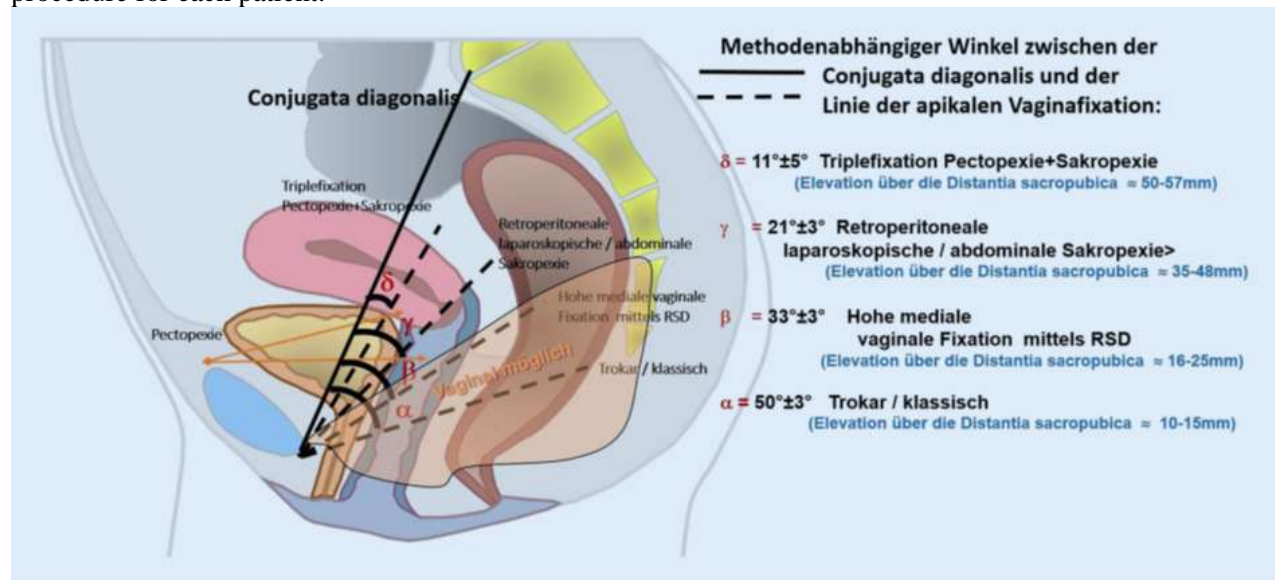
joerg.neymeyer@web.de

**Objective** – To compare the anatomical elevation angle of the vagina (EAV) following four different pelvic floor reconstructive procedures

**Methods** – A postoperative MRI was performed following four different pelvic reconstructive procedures: classical sacrospinous fixation, high medial sacrospinous fixation, laparoscopic sacrocolpopexy and triple fixation sacropectopexy. Postoperative MRI of 30 patients from each of the four procedures were evaluated and the vaginal angle from the pelvic diagonal conjugate was measured. A lower EAV is represented by larger angle from the pelvic diagonal conjugate.

**Results** - The classical sacrospinous fixation had the lowest EAV, followed by high medial sacrospinous fixation, laparoscopic sacrocolpopexy and triple fixation sacropectopexy respectively.

**Conclusion** – We were able to objectively demonstrate that different pelvic floor reconstructive procedures result in different EAV. This information may be significant for properly tailoring the type of procedure for each patient.



## **Postpartum recovery from pelvic floor dysfunction symptoms during pregnancy**

*ADI WEINTRAUB*

*Soroka University Medical Center, Beer Sheva, Israel  
adiyehud@bgu.ac.il*

Pelvic floor dysfunction (PFD) symptoms in pregnancy and the postpartum period are a common occurrence. The presence of PFD symptoms in basically young and healthy women is a major public health concern affecting women's quality of life. Despite their frequent occurrence, many aspects of the pathophysiology of PFD symptoms in association with pregnancy, delivery and the puerperium remain uncertain. Some observations tend to suggest a deleterious, yet reversible, effect of pregnancy. In the current talk I will address symptoms during pregnancy and their postpartum recovery with a special focus on gestational diabetes, the second stage of labor and breast feeding.

## **Investigation of chronic pelvic pain and painful retroverted uterus**

*PETER VON THEOBALD, JULIE EGGERMONT, ANCA BIRSAN*

*CHU Reunion, France  
vonthobald@gmail.com*

In a consultation dedicated to chronic pelvic pain, more and more patients are referred for suspicion of endometriosis. Among this population, one of the most forgotten diagnoses is the painful retroverted uterus (PRU) that may mimic endometriosis and can also be related to previous surgery of the uterosacral ligaments. The authors detail the clinical and complementary investigations that may lead to the diagnosis of PRU and the surgical or non-surgical treatments that may be suggested.

## **Should we all go for laparoscopic sacrocolpopexy if we want to use mesh for pelvic organ repair?**

*PETER VON THEOBALD, JULIE EGGERMONT, ANCA BIRSAN*

*CHU Reunion, France  
vonthobald@gmail.com*

Since FDA alerted urogynecologists against vaginal mesh surgery, many pelvic surgeons went back to autologous tissue repair in POP surgery. Amazingly, despite a rather high complication rate, LSCP is still politically correct and even more and more indicated. The authors compare the complication rates and the specific indications of both vaginal and laparoscopic mesh surgery in order to try to answer the title question.

## **Three-dimensional endoanal ultrasound in obstetric anal sphincter injuries**

*GIULIO A. SANTORO*

*Colorectal and Pelvic Floor Unit, Dep.of General Surgery,  
Regional Hospital, Treviso, Italy  
giulioasantoro@yahoo.com*

Faecal incontinence (FI) affects all age groups of adults and both sexes. It is often distressing and embarrassing, lowers quality of life and a sense of health and well-being, and interferes with social interactions and intimacy. Faecal incontinence increases risk of skin damage, such as inflammation and dysfunction of epidermal skin layers and pressure injury. Conservative treatment of FI is recommended in the absence of acute traumatic anal sphincter rupture or a major defect in the external anal sphincter confirmed by endoanal ultrasonography (EAUS). Patients with these problems should be referred for surgical evaluation initially. Reduction of FI severity, such as its frequency, is a goal of therapy for many individuals when complete cure may not be attainable. Endoanal ultrasound is established as an important part of a colorectal diagnostic work-up and has been recommended as the gold standard investigation to identify anal sphincter injury by the International Urogynecological Association, International Continence Society, International Consultation on Incontinence. It allows the morphological assessment of the anal canal, differentiating between incontinent patients with intact anal sphincters and those with sphincter lesions (defects, scarring, thinning, thickening, and atrophy) due to obstetric anal sphincter injuries (OASIS). OASIS is a term used to define trauma to the perineum during vaginal childbirth that includes third- (injury to perineum involving the anal sphincter complex) and fourth-degree tears (injury to perineum involving the anal sphincter complex and anal epithelium). Three-dimensional (3D) ultrasound is a simple, well-tolerated and non-expansive technique that provides measurement of length, thickness, area of sphincter defect in the sagittal and coronal planes and volume of sphincter damage. US imaging is also useful to evaluate the result of sphincteroplasty and to detect residual anal sphincter defects after repair. There is evidence to suggest that 3D-EAUS performed after vaginal birth and before the tear has been repaired could lead to improved primary repair of the internal and external anal sphincter resulting in reduced rates of FI and improved quality of life for women. EAUS may also have a role in the management of subsequent pregnancies after OASIS.

## **Applied and ultrasound anatomy of the pelvic floor**

*GIULIO A. SANTORO*

*Colorectal and Pelvic Floor Unit, Dep. of General Surgery, Regional Hospital, Treviso, Italy  
giulioasantoro@yahoo.com*

The pelvic organs rely on 1) their connective tissue attachments to the pelvic walls and 2) support from the levator ani muscles that are under neuronal control from the peripheral and central nervous systems. The term “pelvic floor” is used broadly to include all the structures supporting the pelvic cavity rather than the restricted use of this term to refer to the levator ani group of muscles. The pelvic floor consists of several components lying between the peritoneum and the vulvar skin. From above downward, these are the peritoneum, pelvic viscera and endopelvic fascia, levator ani muscles, perineal membrane, and superficial genital muscles. The support for all these structures comes from connections to the bony pelvis and its attached muscles. The pelvic organs are often thought of as being supported by the pelvic floor, but are actually a part of it. The pelvic viscera play an important role in forming the pelvic floor through their connections with structures, such as the cardinal and uterosacral ligaments. The female pelvis can naturally be divided into anterior and posterior and lateral compartments. The genital tract (vagina and uterus) divides the anterior and posterior compartments through lateral connections to the pelvic sidewall and suspension at its apex. The levator ani muscles form the bottom of the pelvis. The organs are attached to the levator ani muscles when they pass through the urogenital hiatus and are supported by these connections. There are three major components of the levator ani muscle. The iliococcygeal portion forms a thin, relatively flat, horizontal shelf that spans the potential gap from one pelvic sidewall to the other. The pubovisceral (also known as the pubococcygeus) muscle attaches the pelvic organs to the pubic bone while the puborectal muscle forms a sling behind the rectum. The lesser known subdivisions of the levator are pubovaginal, puboanal and the puboperineal muscles. The opening between the levator ani muscles through which the urethra, vagina, and rectum pass is the levator hiatus. The portion of the levator hiatus ventral to the perineal body is referred to as the urogenital hiatus and it is through this that

prolapse of the vagina, uterus, urethra and bladder occurs. The urogenital hiatus is bounded anteriorly by the pubic bones, laterally by levator ani muscles, and posteriorly by the perineal body and external anal sphincter. The baseline tonic activity of the levator ani muscle keeps the hiatus closed by compressing the urethra, vagina, and rectum against the pubic bone, pulling the pelvic floor and organs in a cephalic direction. This continuous muscle action, similar to the external anal sphincter, closes the lumen of the vagina much as the anal sphincter closes the anus. This constant action eliminates any opening within the pelvic floor through which prolapse could occur and forms a relatively horizontal shelf on which the pelvic organs are supported. Damage to the levators resulting from nerve or connective tissue damage will leave the urogenital hiatus open and result in prolapse.

## **Fecal incontinence**

*SIDI MUCTAR*

*muctar.sidi@gmail.com*

We analyzed the relationship between the Longitudinal Anal Muscle and the Sacro- Uterine- Ligament for the Fecal Incontinence.

Investigators who looked for the LAM couldn't identify it for both, as an anatomical unit or as a downwards traction force on the Rectum, as it is mentioned in the integral theory?

The rectovaginal fascia could be in return the anatomical unit that pushes the rectum downwards. The rectovaginal fascia lies over the muscle Ileococcygeus and extends both sides to the arcus tendineus fascia muscle.

On the basis of this anatomical understanding, we present a new surgical method that supports the sphincter Ani for Fecal incontinence.

## **The role of hysterectomy in pelvic organ prolapsus surgery**

*ERAY ÇALIŞKAN*

*Bahcesehir University School Of Medicine, Istanbul, Turkey*

*dreraycaliskan@yahoo.com*

The most commonly performed surgical procedure for uterine prolapse is hysterectomy, and 15% to 18% of all hysterectomies are performed for POP, making POP the third most common reason for hysterectomy overall and the leading indication in postmenopausal population. The subject is reviewed under different subheadings: Anatomical Considerations, presence of Concomitant Diseases, Evidence of Harm after hysterectomy, Total/Subtotal Cost, the concept of Prophylactic Hysterectomy and Oophorectomy, patients perception about hysterectomy, the prevalence of incidental concomitant cancer, Impact of Primary Disease on Incontinence or Prolapsus, Effects on operative complications, Long Term Outcome and Recurrence With or Without Hysterectomy, Future research targets. Prolapse surgery must consider the cost-benefit analysis, success, complication rate and morbidity of the procedure, both immediately and over the long-term. Long-term data on uterine preserving procedures are limited and the subsequent need for hysterectomy in the surgical correction of POP is not known (Grade C). Uterine preserving techniques appear to be a promising option in women with POP, particularly in those with future desire of fertility. Hysterectomy lowers the risks of uterine or cervical malignancy and postmenopausal bleeding, and thus, the surveillance or therapeutic costs for these situations. Careful patient selection is a crucial step prior to considering uterine conservation in women with pelvic organ prolapse and women with abovementioned diseases should not be candidates for uterine preserving procedures.

## **To mesh or no-mesh surgery in pop treatment?**

*SALIMOVA LEILA YA, SHALAEV O.N.*

*leilasal@mail.ru*

Objective: to compare non-mesh and mesh technologies in POP treatment.

Methods: in seven years we have been operated 470 women with POP stage more than II with complience. All women were operated by vaginal route using non-mesh technologies (n=270) and TVM (n=250).

Conclusions: Anatomical results of the mesh and non-mesh surgery are comparable if compare pathogenetic operation. Complications of these operations are the similar. Mesh-complication are equalized with recurrence of prolapse after non-mesh surgery.

Surgical algorithm is allows us to make an alternative choice in surgery after the complex diagnosis and assessing suboptimal results of POP treatment.

## **The role of the posterior Compartment of the vagina for defecation disorders**

*BURGHARD ABENDSTEIN*

*burghard.abendstein@vlkh.net*

Anatomically we speak of an anterior, middle and posterior compartment of the female pelvic floor. This presentation focuses particularly in the posterior compartment defects of the vagina, related symptoms and potential anatomical approaches for treatment.

According to the Integral Theory, posterior compartment defects of the vagina, particularly the anterior rectocele, are related with symptoms of urge, frequency, nocturia, pain and fecal incontinence. Obstructed defecation is another dysfunction based on anatomical defects in the posterior compartment.

The first part of the presentation will deal with symptoms and treatment of fecal incontinence, the second part will focus on obstructed defecation.

Traumatic, stress receptor related or neural reasons are very well accepted causes for fecal incontinence. However, in 50% of fecal incontinence the pathomechanism is widely unclear. A musculo-elastic theory has been developed in order to explain these poorly understood cases. This musculo-elastic theory tries to explain the importance of intact fascial and ligamentous connective tissue structures in order to maintain fecal continence. In various studies this theory has been challenged and based on that therapeutic strategies have been elaborated. The importance of the musculo-elastic theory will be explained.

The same structures play an important role for normal defecation. It will be demonstrated that the reconstruction of the uterosacral ligaments together with the repair of the rectovaginal fascia is a valid therapeutic strategy for the treatment of obstructed defecation.

The presentation will give the theoretical background and the clinical studies, which explain the relation of the posterior compartment of the vagina and fecal incontinence as well as obstructed defecation. Moreover, it will point out its impact for treatment strategies.

## **Single Incision Vaginal Tape for Lateral Detachment Repair. A Pilot Study and The Description of The Method**

*BALINT FARKAS<sup>1</sup>, MIKLOS SZAKACS<sup>1</sup>, CHRISTIAN GOEPEL<sup>1</sup>*

*<sup>1</sup> Vivantes Humboldt Clinic, Pelvic Floor and Incontinence Centre, Berlin, Germany*

*dr.balint.farkas@gmail.com*

Introduction and Hypothesis: Although several surgical techniques are aimed to stabilize the lost integrity at DeLancey Level II, none of them seemed to be optimal. Despite vaginal surgical approaches utilizing

synthetic meshes has been well established, and widely debated, our aim was to establish an optimal surgical procedure to decrease the size of the implanted vaginal grafts.

Methods: In a prospective preliminary study, 43 patients with lateral cystoceles were enrolled, and have been implanted a partially absorbable polypropylene/polyglycolic acid vaginal tape. The two endpoints of the tapes were administered above the ATFP, providing lateral support. In 53 % of the cases (23/43) the patients also received a TVT, due to co-existing SUI. Follow up examination were carried out six month after the operation.

Results: We observed significant shift in the Aa points ( $-0.86 \text{ cm} \pm 0.56 \text{ SD}$  to  $-2.95 \text{ cm} \pm 0.30 \text{ SD}$ ) and in the Ba points ( $-0.42 \text{ cm} \pm 0.59 \text{ SD}$  to  $-2.65 \text{ cm} \pm 1.04 \text{ SD}$ ) pre and postoperatively. Those patients who had dual tape implanted 95% (22/23) were found to continent. During the six month follow up period no mesh extrusion, no dyspareunia and no recurrence were noted.

Conclusions: the implantation of a vaginal tape is a relatively easily and quickly executed surgical technique, which is able to bypass laparoscopic approaches. The method can be combined with simultaneous TVT implantation in SUI patients. Although further studies with more participants, are required to assess the effectiveness of the approach.

## **Vaginal Sacropexy Achieved By Eight Tension-Free Fixing Arms Mesh-Preliminary Results**

*CHRISTIAN GOEPEL<sup>1</sup>, MIKLOS SZAKACS<sup>1</sup>, BALINT FARKAS<sup>1</sup>*

*<sup>1</sup> Vivantes Humboldt Clinic, Pelvic Floor and Incontinence Centre, Berlin, Germany  
dr.balint.farkas@gmail.com*

Objective: Surgical techniques utilizing six arm synthetic meshes for apical prolapse repair has been established, and debated in the last few years. Such vaginal hysteropexy (HPX) has several advantages over abdominal or laparoscopic HPX, although even through trans-sacrospinous fixation the apical reinforcement is not perfect. Our aim was to achieve optimal apical support by multivectoral apical suspension with the use of eight arm polypropylene vaginal mesh.

Methods: In a prospective preliminary study design, 29 patients with pelvic organ prolapse quantification (POP-Q) system stage II-IV anterior and central compartment prolapse were included. They underwent the implantation of an eight arm polypropylene mesh, through a single anterior vaginal incision. The fixation has been achieved through dual transobturator and dual apical (sacrospinous and sacrotuberal) sutureless anchoring.

Results: we experienced significant improvement in the prolapse after surgery in all patients. The mean Aa point was ascended from 1.1 cm to -2.9 cm, consequently the mean Ba point changed from 2.5 cm to -2.9 cm, and the mean C point climbed from 0.6 cm to -7.5 cm after the surgery. All patients were subjectively satisfied after the intervention. During the 12 week follow up period no mesh extrusion and no dyspareunia were noted.

Conclusions: the vaginal implantation of the eight arm mesh comes with high patient satisfaction rates, and achieves vertical vector stabilization of the vaginal apex through sacrotuberal fixation, although further studies with more participants are required to assess the effectiveness of the approach.

## **Experimental work on a new vaginal single port robot**

*PETER VON THEOBALD, D. COEN, M. NEUMAN*

*vontheobald@gmail.com*

Despite excessive costs, robotic surgery has proven some interest in augmenting human skill in surgical operations. Single port surgery raised a lot of interest in the last decade but was finally abandoned because of technical difficulties in obtaining an efficient triangulation of the instruments.

Access to the abdominal cavity through natural orifices has raised interest in many research team but didn't become reality to date.

The idea was to combine robotic surgery with single incision laparoscopy and natural orifices access. MEMIC is developing such a device and we present the experimental work, at a pre clinical stage to date, with the results of cadaver and animal surgery. Development is still ongoing.

## **Pelvic organ prolaps using a six tension free strap low weight transvaginal mesh: long term retrospective monocentric study of 311 patients**

*EMANUEL DELORME*

*delormee\_2000@yahoo.fr*

**Introduction:** Treatment of pelvic organ prolapse is an important public health issue due to the ageing population. The Food and Drug Administration recently issued a warning on complications after transvaginal insertion of high weight mesh. We evaluated a 6 tension-free straps, light prosthesis made from polypropylene monofilaments.

**Materials and methods:** This monocentric, retrospective study included patients undergoing anterior or apical prolapse repair surgery by placement of a six tension-free strap low weight vaginal mesh between 2008 and 2017. The following data were collected from patients' medical records: surgical history, concomitant surgery, clinical examination results, pre and postoperative results of the Urinary Symptom Profile questionnaire, and per and postoperative complications.

**Results:** A total of 311 patients were included (median follow-up: 33 months). The majority (93%) had stage  $\geq$ III cystocele and 26% had stage  $\geq$ III hysterocele. Postoperatively, there were nine cases (2.9%) of asymptomatic cystocele recurrence and 11 (3.5%) cases of hysterocele recurrence, among them six underwent reoperation. Vaginal comfort was significantly improved in 92% vs. 17% before surgery ( $p < 0,0001$ ); two (1,76%) patients had de novo dyspareunia. Preoperatively, 104 patients had stress urinary incontinence (SUI), 45,2% of them were cured postoperatively. There were 62 (30%) cases of de novo SUI. A significant improvement of dysuria ( $p < 0,0001$ ) and overactive bladder (OAB) was found for all severity stages ( $p < 0,0001$ ). Severe complications included haematoma (7,4%), mesh exposure (1.3%), retraction (0.6%), bladder injury (0.6%) and chronic pain (0.6%).

**Conclusion:** Treatment of anterior and/or mid-segment prolapse by transvaginal insertion of a six-strap low-weight mesh is long-term effective, with acceptable morbidity.

## **Bilateral plication of the puborectalis muscles: a novel surgical concept for treating vulvovaginal widening**

*EMANUEL DELORME*

*delormee\_2000@yahoo.fr*

**Objectives:** This study describe a new myorrhaphy technique by bilateral plication of the puborectalis bundles (PRP) of the levator ani muscle to treat vulvovaginal widening. The aim of this work was to report our preliminary experience in terms of morbidity and results (anatomical and functional) in the short and medium term. **Materials and Methods:** This single centre retrospective study concerned 69 women who underwent PRP between January 2011 and December 2014. The main criterion for judging success was the GH before and after surgery (Genital Hiatus in the POP-Q classification: Pelvic Organ Prolapse Quantification System). The secondary criteria were the quality of sexual intercourse and the morbidity. **Results:** The average GH post-surgery was 31, 35 and 35 mm at 6 weeks, 6 and 12 months respectively compared to  $65 \pm 5$  mm pre-operatively ( $p < 0.00001$ ). Among the 27 patients who were sexually active prior to surgery, 18.52% deemed the quality of sexual intercourse satisfactory. After surgery, more than 88% of the patients observed an improvement ( $p < 0.00001$ ). After the surgery the

reported rate of minor complications was under 3%. Conclusion: This preliminary study of PRP confirms the feasibility of the procedure, its low morbidity and the stability of the anatomical outcomes at 12 months.

## **Concepts to treat urethral stricture disease**

*HANSJÖRG KELLER, JÖRN BEIER*

*Clinic for Urology, Pediatric Urology, Urological Oncology and Palliative Medicine Hof, Hof, Germany, Academic Training Center, University of Erlangen  
hansjoerg.keller@sana.de*

**Introduction:** The Prevalence of urethral stricture in male is estimated for Germany on 0.9, that means probably there are more than 100.000 male who were treated with different techniques with variable treatment results. Even so the treatment modality should be influenced by the localization, the etiology and extension of the stricture as well by the patient's desire and estimated success rates, nearly all patients were treated by dilatation or direct vision urethrotomy in spite of a recurrence rate, that ranges between 65 und 100 %

**Objectives:** The following video shows concepts to treat urethral stricture disease oriented towards these parameters. We show how to treat short and extended bulbar, penile, panurethral and meatal strictures. We also present concepts in case of extended stricture with a lack of penile skin or in case of lichen sclerosus.

**Material and Methods:** The presented treatment modalities are performed since more than 20 years in more than 1300 patients and show in long time follow up of at least 5 years excellent results with free of recurrence in about 90 % of the patients.

**Conclusion:** we present concepts to treat urethral stricture disease orientated on etiology, localization, extension, and patient desires.

## **Long-term results of the urethroplasty using oral mucosa graft: a series of more than 1000 consecutive patients**

*ANNA-MARIA BARTA-KELEMEN MIKHAIL BORISENKOV, JÖRN BEIER, HANSJÖRG KELLER*

*Institution: Clinic for Urology, Pediatric Urology, Urological Oncology and Palliative Medicine Hof, Hof, Germany, Academic Training Center, University of Erlangen*

**Introduction and Objectives:** The reconstruction of the urethra with tissue-transfer (e.g. oral mucosa graft, OMG) is the gold standard to treat extended urethral strictures. We present the currently largest series of patients with long-term results.

**Material and Methods:** Since 04/1994 till 03/2016 we performed 968 urethral stricture reconstructions as one-stage procedure and 39 as multi-stage reconstructive procedure (n = 1007) in patients with extended urethral strictures by the use of OMG. The mean number of prior urethral surgery was 5.17x (1-34), the mean patient age was 50.4 years (2-89) and the mean stricture length was 9.4 cm (1-25, median 7 cm). The graft was always placed ventrally (onlay). The recommended follow-up contained uroflowmetry and residual urine ultrasound (prospectively and standardized every 3 months at the 1st year after surgery and then once a year) as well as a standardized "Patient self-reported"-questionnaire about quality of life and complication rate and if the surgery would be recommended to other patients or if in case of recurrence it would be chosen again.

In case of a Flow less than 20 ml/s, a residual urine > 50 ml or urinary tract infections we recommended to perform a urethroscopy or a urethrogramm.



Results: We received the data about recurrence rate from 885/1007 patients (88%, 850 one-stage procedures and 35 multi-stage procedures). 91% (805/885) of these patients were recurrence-free after a mean follow-up of 58.5 months (2-230).

From 78% (785/1007) of our patients the data about the quality of life and if the surgery would be recommended to other patients was available. 97% (n = 764) out of these were satisfied or highly satisfied and would recommend the operation to other patients with urethral stricture. In 7% (n = 52) out of these patients a recurrence of the stricture had occurred. Nevertheless 90% of these patients with relapse would choose the surgery again. 2% (16/785) were unsatisfied regardless of absence of the stricture recurrence.

Conclusions: This currently largest series confirms, that urethroplasty with OMG is the first-line therapy in case of recurrent urethral strictures and associated with an excellent quality of life for the patients.

## **Surgical repair of recurrent bladder neck obstruction after radical prostatectomy via a perineal approach**

*HANSJÖRG KELLER, JÖRN BEIER*

*Clinic for Urology, Pediatric Urology, Urological Oncology and Palliative Medicine, Sana Klinikum Hof, Academic training center University of Erlangen, Hof, Germany  
Hansjoerg.Keller@Sana.de*

Objectives: In case of recurrent bladder neck obstruction (BN) after radical prostatectomy and unsuccessful endourological treatment, open reconstruction is the only way to treat the patient successfully.

The following video shows our technique to reconstruct recurrent BN obstruction via a perineal approach. Cystoscopy is performed, the narrow bladder neck is opened so that a 22 French Cystoscope can pass and 2 single-j-catheters can be inserted in both ureters to prevent damage of the orifice.

Single-j-catheters are drained suprapubically and a suprapubic tube is inserted. Next step is the positioning of the patient in exaggerated lithotomy position like in perineal prostatectomy and to insert the lowsley protractor into the Bladder which is blocked inside to facilitate manipulations.

A semicircular incision is performed around the anus, subcutaneous tissue is transected and the bladder neck is developed by the help of palpating the lowsley protractor.

The access is performed according to Young and the external anal-sphincter is preserved.

The Bladder Neck is developed and the self-retaining-system is inserted.

Now the bladder neck is further developed by the use of bipolar scissors and blunt dissection.

The recto-urethralis muscle is transected and the bladder neck developed.

Levator muscles are pushed to the side bluntly and kept away by the self-retaining-system.

Then the Bladder neck is transected, the lowsley protector is removed and an 18 French catheter is inserted.

It is very important to mobilize the whole Bladder circumferentially to be able to remove all the scared tissue and to perform the anastomosis without tension.

After completely resecting the scared tissue, anastomosis is performed by the use of 3.0 PDS single stitches.

A silicon-tube 18 French is inserted and the wound is closed in layers by the use of 3.0 Monocryl.

Voiding cystography is performed after three weeks to assure a competent bladder neck. Most of the patients remain continent.

In conclusion recurrent bladder neck obstruction can be easily treated by perineal resection and anastomosis with a high success and low complication-rate.

We recommend not to perform more than two bladder neck incisions or dilatations but to go straight forward to do an open reconstruction.

## **Radical perineal prostatectomy and extended perineal pelvic lymph-node-dissection via the same incision.**

*HANSJÖRG KELLER, JÖRN BEIER*

*Clinic for Urology, Pediatric Urology, Urological Oncology and Palliative Medicine Hof, Hof, Germany, Academic Training Center, University of Erlangen*

*Hansjoerg.Keller@Sana.de*

Introduction: Radical perineal prostatectomy is a minimally invasive procedure to treat prostate cancer. However in the past lymph node dissection could not be performed via this approach. Thus a second laparoscopic approach had to be performed in case lymphnode dissection was necessary.

Objectives: In 2004 we developed a technique to perform an extended lymphnode dissection via the same perineal incision, to save operation time and to reduce morbidity.

Material and methods: The video shows how to perform an extended lymphnode dissection via the same perineal approach while performing radical perineal prostatectomy.

Results: Up to now we have performed more than 1000 procedures and removed a mean of 19 up to 37 nodes without increasing the morbidity of the procedure. By doing this, it is the most minimally invasive procedure to treat prostate cancer. All patients are on regular diet within 24 hours and on oral pain killers only.

The transfusions rate is less than 1 % and all the oncological and functional results are comparable even to the robot-assisted procedure.

Conclusion: Radical perineal Prostatectomy can be performed in all patients with prostate cancer not invading surrounding organs via a single incision of about 5 cm in a minimally invasive way.

## **Radiofrequency in gynaecology**

*OSCAR HORKY*

*horky609@live.com.au*

The 21st century is the time for women to achieve equality in all areas. This includes sexual freedom and freedom from incontinence, vaginal atrophy, vaginal laxity and vulval problems.

I initially trained in Laser therapy but after meeting with Dr Red Alinsod at the ISPP Conference in Istanbul he introduced me to Radiofrequency and demonstrated its superiority to Laser.

I introduced ThermiVa to Australia and subsequently into China. I shall detail my experience with this new treatment for Vulval/Vaginal problems and mild to moderate incontinence.

## **Long lasting symptom cure by pelvic floor surgery depends on successful longlasting prolapse repair**

*BERNHARD LIEDL, A. YASSOURIDIS, S. SUTHERLAND, J. LUKBAN, JP ROOVERS, E STANFORD*

*bernhard.liedl@t-online.de*

Many symptoms of bladder and anorectal dysfunctions as well as pain can be induced by pelvic organ prolapse. The Propel-Study (ClinicalTrials.gov Identifier:NCT00638235) was performed to prove the efficacy of Elevate anterior/apical and Elevate posterior/apical in pelvic organ prolapses stage 2.-4. The pelvic floor disorder Inventory (PFDI) contains 46 questions of all possible prolapse induced dysfunctions and was used for patient related outcome measures. The women were asked preoperatively, 6, 12 and 24 months after surgery. This analysis focuses on treatment effects and should answer the question how symptom cure depends on successful longlasting prolapse repair.

277 women could be analysed, 185 women could be followed up for 24 months postoperatively. The possible answers to the different questions concerning symptom bother were: no, yes-not at all, somewhat, moderate, quite a bit.

All symptoms of daytime urinary frequency, urgency, urgency incontinence, nocturia, abnormal emptying of the bladder, fecal incontinence, obstructed defecation, hemorrhoids, rectal prolapse, pain were cured in a high percentages. Analysing the effects of successful (definition in the study: prolapse stage 0 or 1 at follow-up, called responders) versus the others (at follow-up stage 2, 3 or 4, called non-responders), those women with successful prolapse repair had much better cure rates than the others. The table shows the results concerning the symptom nocturia.

In conclusion all symptoms of pelvic floor dysfunctions could be cured in a high percentage. The cure rates depend on the successful longlasting prolapse repair. It seems that use of alloplastic material is important for longlasting symptom cure by pelvic floor surgery.

Prevalences of the OAB symptom-outcomes before and after POP reconstruction  
in the subpopulation of the **Responders** (POPQ grade in all phases after OP= 0 or 1; n=141)

OAB symptoms and their possible outcomes (FFDI questionnaire)	BASELINE (phase: 0)		6 months after OP (phase: 1)		12 months after OP (phase: 2)		24 months after OP (phase: 3)		Cochran's Q-tests for the global time effects on #2 (p-values)	McNemar tests for the simple effects (phase pairs with stat. significance at $\alpha^1$ )
	abs. freq.	rel. freq.	abs. freq.	rel. freq.	abs. freq.	rel. freq.	abs. freq.	rel. freq.		
<i>FFDI 27 (nocturia)</i>										
no or not at all	48	34,8%	87	64,4%	83	64,3%	59	63,4%		
somewhat	29	20,6%	38	28,3%	28	21,7%	21	22,6%		
moderately	32	22,7%	8	5,9%	14	10,9%	12	12,9%		
quite a bit	32	22,7%	2	1,5%	4	3,1%	1	1,1%		
abs. cases	141	100,0%	135	100,0%	129	100,0%	83	100,0%		
#2: moderate or quite a bit	64	45,4%	10	7,4%	18	14,0%	13	14,0%	p < 0,00001	0/1, 0/2, 0/3

Prevalences of the OAB symptom-outcomes before and after POP reconstruction  
in the subpopulation of the **Non-Responders** (POPQ grade in either 6, 12 or 24 months after OP=2, 3 or 4; n=87)

OAB symptoms and their possible outcomes (FFDI questionnaire)	BASELINE (phase: 0)		6 months after OP (phase: 1)		12 months after OP (phase: 2)		24 months after OP (phase: 3)		Cochran's Q-tests for the global time effects on #2 (p-values)	McNemar tests for the simple effects (phase pairs with stat. significance at $\alpha^1$ )
	abs. freq.	rel. freq.	abs. freq.	rel. freq.	abs. freq.	rel. freq.	abs. freq.	rel. freq.		
<i>FFDI 27 (nocturia)</i>										
no or not at all	29	33,3%	48	55,8%	41	53,2%	29	47,5%		
somewhat	16	18,4%	20	23,3%	15	19,5%	14	23,0%		
moderately	14	16,1%	12	14,0%	11	14,3%	11	18,0%		
quite a bit	28	32,2%	6	7,0%	18	23,0%	7	11,5%		
abs. cases	87	100,0%	86	100,0%	77	100,0%	61	100,0%		
#2: moderate or quite a bit	42	48,3%	18	21,0%	21	27,3%	18	29,5%	p < 0,00001	0/1, 0/2, 0/3

Table: Effect of mesh-supported prolapse repair on bothering nocturia: responders versus non-responders to surgery.

## Closing the gap between the conservative and the surgical therapy of the genital laxity: the radiofrequency approach

ANDREI MÜLLER-FUNOGEA  
andrei.muellerfunogea@gmail.com

The anatomy and physiology of female genitalia can change due to various causes such as childbirth, aging and menopause, genetics or trauma. If the female genital region becomes loose and lax over time, this can cause not only aesthetic but also medical concerns that can adversely affect female sexual health and quality of life. Symptoms include atrophic vaginitis, decreased sexual sensation during coitus, loss of sexual gratification, stress urinary incontinence (SUI), pelvic organ prolapse and general dissatisfaction with the appearance of the area. Since vaginal laxity is common and may impact important sexual and medical functions, greater knowledge regarding pathophysiology and treatment is of benefit to women patients.

Vaginal remodeling and rejuvenation are general terms used to describe a range of procedures intended to restore the optimal structure of the vagina and surrounding tissues. These procedures include topical and systemic treatments, surgical procedures and, recently, energy-based technologies. Noninvasive energy-based procedures are often preferred by women who are reluctant to undergo surgery due to the risk, expense, and recovery period.

Recent technological developments include fractional laser and radiofrequency technologies for vaginal non-surgical thermal treatment in women with vaginal atrophy and laxity suffering from aesthetic and medical symptoms. Studies have shown that the controlled application of thermal energy to the vaginal wall and labia stimulates biological processes in the vaginal skin layers such as proliferation, neovascularization and new collagen formation, resulting in an improvement of symptoms.

Radiofrequency is one of the more innovative approaches to treating vulvo-vaginal laxity and SUI. It has gained significant popularity in recent years due to its non-invasiveness, absence of adverse events, and rapid results. The mechanism of action is based on elevating the temperature of the treated tissue to initiate biological changes. Radiofrequency energy heats the connective tissue of the vaginal wall up to 43°C, triggering micro-inflammatory stimulation of fibroblasts to stimulate collagen contraction, neocollagenesis and ne elastogenesis to revitalize and restore the strength, elasticity and finally also the moisture of the vaginal mucosa. It can be used postmenopausal, especially when topical estrogen doesn't work and even after hormone-sensitive breast cancer.

Numerous studies have demonstrated the therapeutic efficacy of RF-based devices in the rejuvenation of other body areas such as the face and neck and are at this time quite popular in the USA and already FDA approved. Their application in the vaginal canal is a relatively new concept that is currently being studied and also applied in some European countries.

The results indicated that RF-based therapy can be used safely and successfully for the treatment of various vaginal-related symptoms, including sexual matters and urine incontinence.

The treatment was uncomplicated and well-tolerated by the patients. Patients with either light or dark skin types can be treated. There were statistically significant improvements in all of the treatment outcomes tested. Especially the bipolar RF is a targeted, very safe technology. The therapy is ambulatory and takes 20 to 30 minutes, needs no local anaesthesia and shows short-term recovery. It may be repeated once again and after 6 months.

In one study, there were no differences between the groups and a short treatment duration was as effective as a longer treatment duration. However, an even longer treatment duration, more treatment sessions and an objective quantitative evaluation could result in significant differences. We need more data about that.

## **Sacrocolpopexy : Advantages and disadvantages - a systematic literature review**

*DUMITRAȘCU MIHAI CRISTIAN, ALBU RUXANDRA ANDREEA. FODOROIU RĂZVAN, NENCIU CĂTĂLIN GEORGE, NENCIU ADINA, GORGOI CORINA OANA, CÎRSTOIU MONICA MIHAELA  
drdumitrascu@yahoo.com*

Pelvic organ prolapse has become a common problem among women and because of the increasing incidence, several surgical techniques have been developed.

The current 'gold standard' surgical repair for pelvic organ prolapse is the abdominal mesh sacrocolpopexy because of its high success rate and excellent anatomic outcome.

Other methods have also been developed, such as transvaginal, laparoscopic and robotic assisted surgical procedures.

The goal of this presentation is to determine the major advantages and disadvantages of these methods based on a systematic literature review.

Keywords: Sacrocolpopexy; Pelvic organ prolapse; Laparoscopy; Surgical procedure.

## **Excess of vaginal tissue in POP: a bond between the use of mesh versus native tissue repair in POP reconstructive surgery**

*SERBAN NASTASIA, ROXANA BOHILTEA, ELVIRA BRATILA, MONICA CARSTOIU, MANUELA CRISTINA RUSSU*

*"Carol Davila" University Of Medicine And Pharmacy, Bucharest, Romania  
serban\_nastasia@yahoo.com*

This study presents the usage of excessive vaginal tissue in transvaginal POP surgery, using mesh anchored to sacrospinous ligaments. An elliptic incision in the midline of anterior and/or posterior vaginal walls created a flap from vaginal mucosa excess, left in situ and deepithelialized by electrofulguration. The mesh is placed superficial to the flap. The pathological examination of a small fragment of the vaginal flap showed no epithelium left after electrofulguration.

Excess of vaginal mucosa is a valuable source of autologous material for strengthening the subvesical and intervaginorectal fascia in patients with genital prolapse associated with voluminous cystocele and/or rectocele.

## **Sequential versus concomitant surgery in cystocele with stress urinary incontinence**

*DICULESCU DORU, FULGA FLORESCU, TODEA CEZARIN, CIORTEA RAZVAN, MALUTAN ANDREI, BUCURI CARMEN, POP DARIA, RADA MARIA, IUHAS CRISTIAN, MOCAN-HOGNOGI RADU*

*University of Medicine and Pharmacy "Iuliu Hatieganu", Department of Obstetrics and Gynecology, Cluj-Napoca, Romania  
ddiculescu@yahoo.com*

The coexistence of anterior vaginal prolapse (cystocele) with stress urinary incontinence (SUI) is a challenge for reconstructive surgery. Unfortunately, prolapse repair might not restore urinary continence, even if a dedicated sling procedure is performed.

Some patients with cystocele have occult SUI, discovered on the occasion of the prolapse reduction procedure, during preoperative urodynamic tests. Although they perceive themselves as continent, these patients also need an anti-incontinence procedure.

Patients with cystocele and SUI without urethral hypermobility do not benefit from sling procedures. Cystocele patients with concomitant intrinsic sphincter deficiency and urethral hypermobility would benefit from prolapse repair with the simultaneous placement of a suburethral sling. In the case of mixed urinary incontinence, medical therapy is the first choice, while sling surgery is only used subsequently.

The choice of sequential surgery versus concomitant combined surgery in patients with cystocele and SUI generates a dilemma. In the sequential approach, cystocele is first repaired, and the patient is monitored postoperatively for persistence or resolution of SUI. Subsequently, a sling procedure can be performed if indicated. In the concomitant surgical approach, which is sometimes intuitive, studies have identified the anti-incontinence procedure as a risk factor for cystocele recurrence. On the other hand, the concomitant approach may cause postoperative micturition dysfunction (hyperactive bladder, urinary obstruction or retention), with a devastating impact. From this point of view, a sequential approach may lead to a higher patient satisfaction in the long term. However, concomitant surgery has the advantage of one hospitalization, one surgery, one anesthesia procedure and one recovery period.

Each surgeon should establish their own clinical and ethical algorithm to resolve such situations.

## **Transperineal intrapartum ultrasound. What is the aim?**

*DOMINIC ILIESCU<sup>1,2</sup>, STEFANIA TUDORACHE<sup>1</sup>, ROXANA DRAGUSIN<sup>1,2</sup>, CIPRIAN PATRU<sup>1,2</sup>*  
*<sup>1</sup>Department of Obstetrics and Gynecology, University of Medicine and Pharmacy Craiova, Romania*  
*<sup>2</sup>Department of Obstetrics and Gynecology, SC Endogyn AM SRL Craiova, Romania*  
*dominic.iliescu@yahoo.com*

**Objective:** The benefits of the objective and accurate ultrasound (US) determinations of the fetal head situation in the birth canal are underlined by an impressive body of the literature. Our aim was to summarize the potential influence of US determinations in labor on fetal and maternal outcome.

**Methods:** We present our experience and a review of the literature, regarding the performance of US monitoring of labor.

**Results:** The evidences strongly suggest the need for objective US determinations regarding the fetal position and progression, especially in challenging clinical situations for the prediction of successful vaginal birth. The fetal head progression can be accurately estimated using the objective sonographic techniques. Still, regarding the potential benefits of routine US in labor, the literature offers discordant data on interventional and Caesarean delivery rates.

**Conclusion:** The advantages of US labor monitoring should be known by the professionals, at least for high-risk cases including the occiput position. The accuracy of US measurements regarding head position and progression is remarkable and superior to clinical exam.

## **Haemorrhoids in females – a consequence of impaired blood flow associated with pelvic organ prolapse?**

*TRAIAN ENACHE*  
*traian\_e2000@yahoo.com*

**Objective:** We are trying to find an explanation for the high incidence of haemorrhoids in female patients with pelvic organ prolapse (POP). Our hypothesis was that a cause-effect relationship between POP and haemorrhoids might be the key. The objective of this study was to find an element which connects the two instances.

**Materials and methods:** We examined a group of 13 patients with 3rd and 4th degree POP. The subjects were assessed clinically and using ultrasound, before and after the gentle reduction of the prolapse. Among the parameters measured by ultrasound were: resistivity index (RI) on uterine arteries measured transvaginally and inferior rectal arteries (IRA) assessed by transrectal approach.

**Results:** Both uterine arteries RIs were significantly lower after reducing the prolapse,  $p < 0.01$ . The mean RI of IRA was 0.77 and 0.91 after reducing the prolapse. This might be interpreted as a pelvic venous stasis associated with POP which is improved after the above mentioned manoeuvre. Obstructed veins due to POP might induce the dilation of the haemorrhoids. The direct measurement of IRA allows us to assess directly the increased resistance in the rectal vascular system.

**Conclusion:** Venous stasis and impaired vascular flow might be the physiopathological explanation of the association between POP and haemorrhoids. In these patients the pathogenic treatment should aim the restoration of a normal blood flow (POP surgical cure) instead of focusing on haemorrhoids only.

## **The place of hysterectomy in the management of uterine prolapse: Is it actually necessary? Pros and Cons**

*PIRTEA LAURENTIU, BALINT O., SECOSAN C., GRIGORAS D.*  
*laurentiupirtea@gmail.com*

The traditional approach for uterine prolapse was vaginal hysterectomy. Modern theories advocate in favour of uterine conservation considering that the uterus is a healthy organ and the prolapse is generated

by a connective tissue damage. Our presentation reviews the arguments in favour or against the preservation of uterus as well the possible vaginal or laparoscopic techniques for uterine prolapse treatment with uterus in place.

## **Laparoscopic promonto hysteropexy - the six points technique**

*PIRTEA LAURENTIU, BALINT O., SECOSAN C., GRIGORAS D.  
laurentiupirtea@gmail.com*

Laparoscopic promontopexy is the golden standard for surgical cure of apical vaginal fixation. The technique implies 2 meshes one on the anterior and one on the posterior compartment; and 6 different points for mesh fixation: 2 on the puborectalis muscles, 2 at the level of uterosacral ligaments, one the anterior vaginal wall and one at the promontorium. A video that demonstrates the technique step by step will be presented.

## **Laparoscopic lateral suspension using a mesh in the treatment for pelvic organ prolapse, an alternative method for vaginal hysterectomy**

*DUMITRAȘCU MIHAI CRISTIANI, FODOROIU RĂZVANI, NENCIU CĂTĂLIN GEORGEI, NENCIU ADINAI, ALBU RUXANDRA ANDREEAI, PARIZA GEORGEI, CÎRSTOIU MONICA MIHAELAI  
1 University Emergency Hospital, Bucharest, Romania  
drdumitrascu@yahoo.com*

Pelvic organ prolapse is a condition characterized by the descent of pelvic organs. Major risk factors for pelvic organ prolapse in women are pregnancy and childbirth, associated with surgical gynecological treatment and heavy lifting.

The traditional approach for uterine prolapse is the vaginal hysterectomy. However, hysterectomy is both the reason for and outcome of pelvic organ prolapse.

In this our article we want to present our experience with the technique of laparoscopic lateral suspension using a mesh to treat uterine prolapse as an alternative to the vaginal hysterectomy.

Keywords: Laparoscopic lateral suspension; Vaginal hysterectomy; Pelvic organ prolapse.

## **Chronic pelvic pain, incontinent pelvic vein relationship**

*LIANA PLES<sup>1,2</sup>, MIRCEA OCTAVIAN POENARU<sup>1,2</sup>, OCTAVIAN GABRIEL OLARU<sup>1,2</sup>, ANCA DANIELA STANESCU<sup>1,2</sup>  
1 Carol Davila University of Medicine and Pharmacy, Romania  
2 St John Hospital Bucharest, Romania  
plesliana@gmail.com*

Background. Chronic pelvic pain (CPP) is a spectrum of symptoms including pain, tension in the lower abdomen, dyspareunia, dyschezia, dysuria or dysmenorrhea. The condition responsible for CPP are various but in more than 60% cases the diagnosis cannot be established. Ultrasound is a useful tool in the evaluation of those patients.

Material and method. We evaluated retrospectively the ultrasound scans and physical examination of the patients who presented in our clinic for various gynecological complaints between jan 2016- jan 2018. We retrieved only the patients who reported at least one of the symptoms compatible with CPP and reviewed the files. A chart with relevant characteristics –age, parity, main complaints, transvaginal ultrasound was completed. We searched for abnormal pelvic vascular patterns suggestive for incontinent pelvic veins

Results. In a two years period 2437 women asked for genital examination in "Bucur" Obstetrics and Gynecology Clinic. For 326 women abdominal pain was the main complaint but only 128 met the criteria for CPP. In 31 of them ultrasound transvaginal scan revealed abnormal vascular patterns of the pelvic veins (enlarged, tortuous vessels) suggestive for congestion and incompetent veins.

Conclusions. Congestion of the pelvic veins can be responsible for about 30% of the CPP especially in multiparous women. Ultrasound using Doppler is useful in order to establish incompetence of the pelvic veins.

## **The genitourinary syndrome of menopause**

*CORINA GRIGORIU, CORINA NEAMTU, MADALINA MUSAT, RARES SIMU, STELUTA GEORGESCU-MARIUTAN, DIANA MUNTEANU, LUCIANA OPREA, MIRCEA ICHIM, ALICE LAVINIA BALACEANU*  
*corigri@gmail.com*

**Objective** The genitourinary syndrome of menopause (GSM) defines, according to the International Society for the Study of Women's Sexual Health and the North American Menopause Society, a collection of symptoms and signs associated with a decrease in estrogen and other sex steroids involving changes to the labia majora/minora, clitoris, vestibule/introitus, vagina, urethra and bladder. The syndrome may include, but is not limited to, genital symptoms of dryness, burning and irritation; sexual symptoms of lack of lubrication, discomfort or dyspareunia; urinary symptoms of urgency, dysuria and recurrent urinary tract infection. Some or all of these signs may be present.

**Method** As a consequence of declines in estrogen secretion, all the above mentioned structures may suffer from thinning of their epithelial lining, loss of elasticity, reduction of secretions with consecutive dryness and inflammation (vagina). Also, the bladder, urethra, pelvic floor musculature and endopelvic fascia become atrophic. Although disturbing, these symptoms are rarely discussed with the health care provider in our country (due to cultural or religious beliefs, considered being part of the normal aging). As such, no treatment is used and women make instead different life style changes (they stop their sex life because of dyspareunia, limit their liquid intake due to urinary symptoms etc). About 40% report this symptoms during perimenopause and over 55% three years postmenopause.

**Results** Beside clinical pelvic exam, several cheap paraclinical tests may be useful: vaginal pH measurements, the maturation index of the vaginal epithelium (the proportion of parabasal, intermediate and superficial cells from the upper one third of the vagina), the microscopic examination of vaginal smears and also cervical cytology, ultrasonography of the endometrium, urinalysis. Treatment options vary from vaginal moisturizers and lubricants to vaginal estrogens (tablets, creams, ring), vaginal testosterone, vaginal dehydroepiandrosterone, SERM's (Ospemifene) or complementary medicine treatments (phytotherapy, gemmotherapy, apytherapy, homeopathy).

**Conclusion** Genito-urinary syndrome of menopause has to be recognized and actively treated, due to important health benefits and improvement of quality of life in peri and postmenopausal women.

## **Single incision sling (mini-sling) for treatment of stress urinary incontinence: 2 years experience of Erciyes University**

*IPTISAM IPEK MUDERRIS*  
*Erciyes University Faculty of Medicine, Kayseri, Turkey*  
*yusufmadendag@mynet.com*

**Object:** Urinary incontinence has been shown to affect up to 50% of women. The purpose of this study is to evaluate the surgical treatment of stress urinary incontinence by the min-single.



Methods:Patients with only SUI were included in the study. All patients included in the study received single incision sling Ophira(Promedon).

Results:33 patients who meet the criteria were included. There was no hematoma and wound infection, bladder or vaginal perforation, urethral injury and infection. None of the patients described the incontinence and urinary retention after the operation.

Conclusions:It seems that the adjustable mini-sling is currently the best compromise in terms of effectiveness and complications.

## **A rare case report: Meckel–Gruber syndrome. Case report**

*IPTISAM IPEK MUDERRIS*

*Erciyes University Faculty of Medicine, Kayseri, Turkey  
yusufmadendag@mynet.com*

Introduction:Meckel–Gruber-syndrome (MGS) is a hereditary, autosomal recessive disorder, with 1/140000 incidence, not compatible with life. Different gene mutations may lead to MGS, it has overlapping clinic manifestations and heterogeneous clinical features. Hepatic, renal, skeletal involvements and pulmonary hypoplasia are major clinic features of MGS...

CASE:A-35-years-old patient at 16th gestational weeks, gravidity-6, parity- 4, was referred. Fetal biometric measurements were all compatible with gestational week except for abdominal circumference(19th weeks)...

Conclusion:Ultrasound technology may supply enough information for the diagnosis of MGS. It is possible to detect impaired antenatal tests in the second trimester. In some suspicious cases fetal MRI can help clinicians to diagnose MGS...

## **Management of proctologic complications in obstetrics.**

*TOMASZ KOSCINSKI*

*Poznan University Of Medical Sciences, Poznan, Poland  
tomaszkoscinski.proktolog@op.pl*

The most frequent risk factors of proctologic complications during childbirth are : prolonged delivery, too quickly conducted labor /oxytocine induced/, too big size of foetus, vacuum or forceps delivery, episiotomy avoidance, abnormal foetus position, uncontrolled perineal tear, incorrect episiotomy.

Evident anal sphincter tears have to be repaired immediately. Episiotomy suturing complications and late diagnosis of anal sphincter damage need delayed reconstruction. Treatment of recto-vaginal fistulas depends on the localization, size of the defect and integrity of anal sphincters. The surgery consists of rectal opening sliding flap repair, recto-vaginal fascia and vaginal wall defect layer repair. Acute onset of hemorrhoidal disease need pharmacotherapy. Large hemorrhoidal thrombosis or massive bleeding are indications for Milligan-Morgan or Ferguson surgery. Biofeedback is first choice treatment for weakened and descending pelvic floor. Large fascial defects are reconstructed using prosthetic material grafts. The rectocele treatment depends on localization and size of the recto-vaginal fascia defects. The transanal techniques may be used for reconstruction as well as transvaginal tension-free mesh implantations.

## **Iliococcygeal fixation as an alternative vaginal surgical technique for anterior compartment repair**

*DERYA KILIC<sup>1</sup>, TOLGA GULER<sup>1</sup>, AKIN SIVASLIOGLU<sup>2</sup>*

*1 Pamukkale University, Department of Obstetrics and Gynecology*  
*2 Mugla University, Department of Obstetrics and Gynecology*  
*deryakilicsakarya@gmail.com*

**Introduction:** Anterior vaginal wall repair is the most commonly performed procedure in POP surgery, either as an isolated procedure or in combination with other surgical interventions. Results of this procedure also have a high risk of surgical failure. Several surgical procedures for the repair of anterior vaginal wall have been described. However, the ideal technique for restoration of normal anterior vaginal anatomy and axis has yet to be defined. Among different clinical studies the success rates of native tissue repair range from %30 to %70 [1].

The bladder normally rests on the anterior endopelvic fascia supported by the vaginal attachments between the pubis, bilateral ATFPs and ischial spines. In most cases, anterior vaginal defects occur by tearing of the endopelvic fascia from the cervical ring. Therefore, it is plausible to suggest that the appropriate surgical technique should contain apical support of bladder by restoring the physiological trapezoid formation of the anterior endopelvic fascia. Using iliococcygeal muscle fascia as an fixation point for the vagina was first described by Inman in 1963 [2] and revised by Shull et al in 1993 [3]. The value of this technique for the restoration of anterior vaginal defects, however, needs to be further elucidated. The objective of the present study is to evaluate the surgical feasibility, efficacy and safety of the use of bilateral iliococcygeal (ICG) fixation as an alternative vaginal surgical technique for the correction of anterior compartment defects.

**Material-Methods:** This study was conducted in an University hospital. A total of 15 patients with anterior vaginal wall defects (isolated or combined with other compartment prolapses), who had been treated by ICG fixation, were retrospectively analyzed. Patient characteristics, intra and post-operative data have been documented and collected on a datasheet.

Standard evaluation in our urogynaecology department included a comprehensive evaluation according to the symptoms and findings. Additionally, all patients were evaluated with validated questionnaires for prolapse, incontinence and quality of life. Complete pelvic and site-specific vaginal examinations were performed. Each compartment (anterior, middle and posterior) were evaluated individually and findings were documented using the pelvic organ prolapse quantification (POP-Q) system.

**Surgical Technique:** The anterior vaginal wall was opened with midline longitudinal incision. The pubocervical fascia was dissected from the vagina with sharp dissection until the iliococcygeal muscle was reached laterally. Central defects on the pubocervical fascia and tears from the cervical ring were restored, if observed. Ischial spine is a landmark to find iliococcygeal muscle and can be found by palpation with the index finger. The non-absorbable suture was used and placed in order to anchor the pubocervical fascia to the fascia of the ICS muscle just through the lateral wall with a fixed 5 mm penetrating depth. Along with site-specific corrections, this fixation surgically restores the normal trapezoid shape and formation of the pubocervical fascia.

Post-operatively, the patients were re-evaluated with the same questionnaires and underwent a complete pelvic and site-specific examination. Preliminary results from the first and third month visit were extracted. Urinary, bowel, pelvic and sexual symptoms, POP-Q scores, ultra-sonographic findings, intra-operative and post-operative complications were evaluated as outcome measures.

**Results:** Preliminary results at the short-term (first and third month) follow-up showed a statistically significant reduction in the subjective prolapse-associated symptoms ( $p < 0.05$ ). There was also a significant difference in the prolapse considering each point of the POP-Q score (not limited only to the anterior compartment). There was a significant restoration for the mean C-point value ( $p < 0.001$ ), although the genital hiatus width and perineal body length were not significantly different between preoperative and postoperative measurements. No notable intraoperative or postoperative complications were observed. One patient was diagnosed with urinary tract infection at the first month visit.

**Discussion:** Our preliminary results confirmed that ICG fixation is a safe and effective procedure for anterior compartment repair, with a promising early postoperative results. One important advantage of using fascia of ICS muscle as a fixation point is the fact that, the ICS fascia does not contain critical structures such as nerves and vessels. Also, it seemed to provide a stable point, adequate for apical

support. Furthermore, because of its lateral and posterior position, the final surgical result would restore the normal trapezoid formation of pubocervical fascia to support the bladder base. One other advantage of ICS fixation is the fact that it has a relatively short learning curve.

Conclusion: ICG fixation for anterior repair seems to be a safe and effective alternative surgical method. Preliminary data with short-term outcome results are promising. Further prospective studies are needed for elucidating its long-term effectiveness.

References:

- 1)Lang P, Whiteside JL (2017) Anterior compartment prolapse: what's new? *Curr Opin Obstet Gynecol.* 29(5):337-342.
- 2) Inmon WB (1963) Pelvic relaxation and repair including prolapse of vagina following hysterectomy. *South Med J* 56:577-582.
- 3) Shull BL, Capen CV, Riggs MW, Kuehl TJ (1993) Bilateral attachment of the vaginal cuff to iliococcygeus fascia: an effective method of cuff suspension. *Am J Obstet Gynecol* 168(6 Pt 1):1669-1674.

## **The tissue fixation system for very elderly patients under local anesthesia on the outpatient basis**

*YUKI SEKIGUCHI*

*Yokohama Motomachi Women'S Clinic LUNA, Yokohama, Japan  
dumbo-ys@d9.dion.ne.jp*

Background: The world population is ageing, notably in Japan bringing with it problems of pelvic organ prolapse (POP). In 2006-7, we began using the TFS (Tissue Fixation System) because of its safety, minimal invasiveness and effectiveness. We have performed TFS-surgery under local anesthesia on the outpatient basis.

Aim: We examined the effectiveness and safety about TFS surgery under local anesthesia for the very elderly people.

Methods: We analysed the results of five TFS surgery under local anesthesia for the patients who were over 85 years old.

Results: The mean age was 86 (range: 85-96). The mean surgery time was 74minutes (range:40-90). The mean blood loss was 21ml (5-29). All operations were carried out on the outpatient basis with no intraoperative and postoperative complications. The cure rate was 100% (The mean observation period was three years.)

Conclusions: We could carry out TFS surgery to the very elderly patients safety and effectively.

## **What equipments will remain among energy exposure treatments for genital area**

*YUKI SEKIGUCHI, RYOKO NAKAMURA, NORIKO NINOMIYA AND YUKARI USUGISAWA*

*Luna Pelvic Floor Total Support Clinic, Yokohama, Japan*

*Yokohama Motomachi Women's Clinic LUNA, Japan*

*Women's Clinic LUNA Shinsabashi, Osaka, Japan*

*dumbo-ys@d9.dion.ne.jp*

(Hypothesis / aims of study)We started to treat genital area problems by energy exposure treatments in 2011. First we used the equipment of Radio-Frequency wave(RF). Next we used the equipment of Fractional CO2 Laser(FCO2L) Third we used the equipment of High Intensity Focused Ultrasound technology(HIFU). This time we are assessing the effectiveness and safety of those 3 technologies and talking expectation of energy exposure treatments for genital area in future.

(Object and Method) We treated 35 patients with RF therapy, 41 patients with FCO2L and 31 patients with HIFU between April 2011 and January 2017 at LUNA Pelvic Floor Total Support Clinic. We reviewed complications and outcome retrospectively. Follow up was performed at 3 months. We checked preoperative safety, vaginal health index, continence and sexual function using 5 grade VAS scale of vaginal tightness, International Consultation on Incontinence-Short Form (ICIQ-SF), Overactive Bladder Symptom Score (OABSS), Urogenital Distress Inventory (UDI-6) and Female Sexual Function Index (FSFI) before operation and after operation 3 months. This study was approved by the Ethics Committees of the Yokohama Motomachi Women's Clinic LUNA in 2011, 2013 and 2016. Written informed consent was obtained from all patients.

(Results) No adverse side effects requiring treatment for more than 3 days were observed in all treatments. Regarding ISIQ-SF, FSFI, vaginal loosening, statistically significant improvement was observed in all treatments, but FSFI did not improve within 3 months. FCO2L was found to be superior than FR and HIFU about vaginal health index.

(Discussion) The characteristic target zones of each treatment are FCO 2 L are mucosa and epidermis, those of RF are submucosal tissue and subcutaneous tissue, and those of HIFU is muscle layer. Urinary incontinence improved in all procedures, but the rates of improvement were inferior to any sling surgeries. On the other hand, the concept of disease called GSM (Genitourinary Syndrome of Menopause) of which characteristic symptoms are genital discomfort, lower urinary tract symptoms and sexual pain has spread. FCO 2 L is considered to be the most effective method relatively for GSM.

## **In-Vitro Anticandidiasis Effect of the Komboucha Extract on Candida Albicans Isolates From Vaginal Secretion**

*FASIE VALERIA<sup>1</sup>, ROBU SILVIA<sup>1</sup> MARDARE NELA<sup>1</sup> DIACONU CAMELIA<sup>1</sup>*

*1 "Dunărea de Jos" University of Galati, Faculty of Medicine and Pharmacy, Unit "Research Center in the field of medical and pharmaceutical sciences "Dunărea de Jos", Faculty of Medicine and Pharmacy / Pharmacology Sciences Department, "Dunărea de Jos" University of Galati, Galați, Romania*

*\*corresponding author: NelaMardare: hipocratgalati@yahoo.com*

*\*\*All authors have had equal contribution to designing and writing the presented paper.*

The present paper aims to highlight the antimicrobial potential of the compounds isolated from Komboucha extract on standard microorganisms strains, successfully used in vitro to treat diseases infected with or primary Candidosis. The results have indicated a variation of the anticandidotic action of the Komboucha extract.

**Introduction:** Komboucha extract has found an important role in therapy due to their antiseptic, antimicrobial and antimycotic properties, being potentially successfully used both in the pharmaceutical area and in other fields like food industry. The present paper lays emphasis on the antimycotic action on various infections associated with Candida Albicans.

**Materials and methods:** For each Candida strain isolated in pure culture, we performed 2-3 mL of a physiological saline tube with a sterile dipstick, an inoculum by suspending mycotic culture (Sabouraud medium for fungi) with 0.5 McFarland turbidity ( $1.5 \times 10^8$  CFU / mL), measured nephelometrically with Densimat equipment.

The analyzes complied with the NCCLS (National Committee for Clinical Laboratory Standards) 2009

**Results and discussions:** Positive results have been obtained on candida albicans. A special recommendation as an alternative in non-responsive cases or a supplement in the treatment of primary candidiasis of genital tract or of the diseases infected with various microbial agents, and also in the prophylaxis of secondary post-antibiotic candidiasis would be the use of extractive solutions based on Kombucha. The observations can be extended in the future to the approach of in vivo/ in vitro inhibition of dysbiosis, alterations of microbiome and endosymbionts possibly involved in genital tract pathology. Also the observations can be extended in the future to prepare lyophilized extract microcapsules as retarded pharmaceutical forms for the treatment of candidiasis.

Keywords: Komboucha extract, antimicrobial, candida albicans

## **Considerations on the in vitro inhibitor effect of komboucha on pseudomonas aeruginosa isolates from the urethral and periurethral area in women**

*FASIE VALERIA<sup>1</sup>, ROBU SILVIA<sup>1</sup> MARDARE NELA<sup>1</sup> DIACONU CAMELIA<sup>1</sup>*

*1 "Dunărea de Jos" University of Galati, Faculty of Medicine and Pharmacy, Unit " Research Center in the field of medical and pharmaceutical sciences "Dunărea de Jos", Faculty of Medicine and Pharmacy / Pharmacology Sciences Department „Dunărea de Jos” University of Galati , Romania, Al. I. Cuza Str. 35, Galați, Romania*

*\*corresponding author: NelaMardare:hipocratgalati@yahoo.com*

*\*\*All authors have had equal contribution to designing and writing the presented paper.*

Our paper highlights the positive antimicrobial potential of Komboucha extract on E.Coli microorganism strains isolated from urethral and periurethral area . The results have indicated a positive inhibitive action on several gram-negative bacteria like Pseudomonas aeruginosa

Introduction: The positive effects of Komboucha extract on gram-positive,gram negative microorganism strains , on fungi such as Candida albicans are recently find in the literature. Also known are the favourable effects of Komboucha extracts in other fields, such as food industry. Our paper aims to highlight the positive inhibitive action of the Komboucha extract on gram-negative microbial strains, i.e. Pseudomonas aeruginosa ones.

Materials and methods: Chemical and microbiological determinations have been made.

For each bacterial strain that was isolated in pure culture, we performed in a 2-3 mL physiological saline tube using a sterile loop, an inoculum, by suspending bacterial culture (Muller Hinton bullion for bacteria) with 0.5 Mc Farland turbidity ( $1.5 \times 10^8$  CFU / mL), measured nephelometrically with Densimat equipment

The antimicrobial activity has been pursued by diffusion in Mueller - Hinton agar on strains of Pseudomonas aeruginosa. The analyses have been carried out in compliance with the NCCLS(National Committee for Clinical Laboratory Standards) 2009.

Resultsand discussions:The results have highlighted a positive inhibitory action on the gram-negative bacteria, more precisely on Pseudomonas aeruginosa

A special recommendation as an alternative in non-responsive cases or a supplement in the treatment of primary bacterial generated by gram-negative bacteria in urethral or periurethral diseases or in gynecologic or urologic pathology with secondary infection with gram-negatives would be the use of extractive solutions based on Kombucha. The observations can be extended in the future to the approach of in vivo/ in vitro inhibition of disbacteriosis, alterations of microbiome and endosymbionts possibly involved in genital and perigenital pathology. Also the observations can be extended in the future to prepare lyophilized extract microcapsules as retarded pharmaceutical forms for the treatment of gram-negative bacterias

Keywords: Komboucha extract, antimicrobial, Pseudomonas aeruginosa.

## **Positive inhibitive action of komboucha extract on E.Coli isolated from perivaginal and vaginal tract**

*FASIE VALERIA<sup>1</sup>, ROBU SILVIA<sup>1</sup> MARDARE NELA<sup>1</sup> DIACONU CAMELIA<sup>1</sup>*

*1 "Dunărea de Jos" University of Galati, Faculty of Medicine and Pharmacy, Unit " Research Center in the field of medical and pharmaceutical sciences "Dunărea de Jos", Faculty of Medicine and Pharmacy / Pharmacology Sciences Department „Dunărea de Jos” University of Galati, Galați, Romania*

*\*corresponding author: NelaMardare:hipocratgalati@yahoo.com*

*\*\*All authors have had equal contribution to designing and writing the presented paper.*

Our paper highlights the positive antimicrobial potential of Komboucha extract on E.Coli microorganism strains isolated from perivaginal and vaginal tract . The results have indicated a positive inhibitive action on several gram-negative bacteria like E.Coli.

Introduction: The positive effects of Komboucha extract on gram-positive, gram negative microorganism strains , on fungi such as *Candida albicans* are recently find in the literature. Also known are the favourable effects of Komboucha extracts in other fields, such as food industry. Our paper aims to highlight the positive inhibitive action of the Komboucha extract on gram-negative microbial strains, i.e. E.Coli ones.

Materials and methods: Chemical and microbiological determinations have been made. For each bacterial strain that was isolated in pure culture, we performed a 2-3 mL physiological serum with a sterile loop, an inoculum, by suspending the bacterial culture (Muller Hinton bullion for bacteria) with a turbidity of 0.5 Mc Farland ( $1.5 \times 10^8$  CFU / mL), measured nephelometrically with Densimat equipment. The antimicrobial activity has been pursued by diffusion in Mueller - Hinton agar on strains of *Escherichia coli*. The analyses have been carried out in compliance with the NCCLS (National Committee for Clinical Laboratory Standards) 2009.

Results and discussions: The results have highlighted a positive inhibitory action on the gram-negative bacteria, more precisely on E.Coli .

A special recommendation as an alternative in non-responsive cases or a supplement in the treatment of primary bacterial generated by gram-negative bacteria in genital or perigenital diseases or in gynecologic pathology with secondary infection with gram-negatives would be the use of extractive solutions based on Kombucha. The observations can be extended in the future to the approach of in vivo/ in vitro inhibition of disbacteriosis, alterations of microbiome and endosymbionts possibly involved in genital and perigenital pathology. . Also the observations can be extended in the future to prepare lyophilized extract microcapsules as retarded pharmaceutical forms for the treatment of gram-negative bacteria, more precisely on E.Coli

Keywords: Komboucha extract, antimicrobial, *Escherichia Coli*

## **Development of POP-related Symptoms, Quality of Life, Anatomical Results and Side Effects after Cystocele Correction with an Improved Titanized Mesh**

*C. FÜNFELD<sup>1</sup>, T. CADENBACH-BLOME<sup>2</sup>, M. MENGEL<sup>3</sup>, M. GREBE<sup>4</sup> AND F. PAUL<sup>5</sup>*

<sup>1</sup> *Clinic Tett nang GmbH, Tett nang Germany*

<sup>2</sup> *Clinic Ev. Amalie-Sieveking, Hamburg, Germany*

<sup>3</sup> *Clinic Oberlausitzer Bergland g GmbH, Zittau, Germany*

<sup>4</sup> *Clinic Dresden-Friedrichstadt, Dresden, Germany*

<sup>5</sup> *Clinic Augsburg, Augsburg, Germany*

*chr.fuenfgeld@t-online.de*

Pelvic organ prolapse (POP) significantly impairs the function of bladder, bowel and sexuality and reduces quality of life (QoL). The aim of POP surgery is the reconstruction of the anatomical position and improvement of QoL. According to the Cochrane database a significantly lower rate of recurrent prolapse is reported for mesh-supported cystocele reconstruction. However, the potential for mesh-induced risks has led to a controversial discussion concerning the use of surgical meshes in urogynecology.

Objective: The purpose of this study was to investigate anatomical stability, complications, improvement of QoL, and the influence on POP-related symptoms after 12 months. The titanized mesh used was improved by changing the porosity (extension from 1 to 3 mm pore size) and weight reduction from 35 to 24 g/m<sup>2</sup>. The improvement of QoL, stability and reduction of adverse events, especially the erosion rate, should be investigated.

Methods: In a prospective multicenter study 52 patients with symptomatic cystocele  $\geq$  Stage II (ICS classification) were treated with implantation of a titanium coated polypropylene mesh (TiLOOP® PRO A, pfm medical ag) via the transvaginal route. A 6-armed mesh was placed using an improved tunneler

for a transobturator and ischioirectal approach and fixed distally, laterally and apically at the sacrospinal ligament. Anatomical outcomes were quantified using the POP-Q system. A recurrent prolapse was defined as  $> -1$  cm: Stage  $\geq$  II. POP-related QoL and symptoms were evaluated pre- and postoperatively. QoL was assessed using the German version of the validated P-QoL questionnaire. All adverse events were assessed by an independent clinical event committee. The study was followed by 100 % monitoring and supervised by an audit.

Results: Stage II prolapse was diagnosed preoperatively in 30.8 % (16/52) of patients; 65.4 % (34/52) had a Stage III prolapse, and 3.8 % (2/52) suffered from a Stage IV prolapse. 57.7 % (30/52) of patients underwent concomitantly posterior colporrhaphy; 17.3 % (9/52) an additional posterior mesh-supported repair and 13.5 % (7/52) were hysterectomized. Twelve months postoperatively data was recorded for 49 patients. In the anterior compartment 4.1 % (2/49) of patients had a recurrent cystocele stage II. After twelve months QoL improved significantly in all nine investigated areas ( $p < 0,001$ , Wilcoxon test). Sexual activity increased from 26.9 % (14/52) preoperatively to 44.9 % (22/49) after twelve months and dyspareunia decreased. 10.2 % (5/49) developed de novo stress urinary incontinence (SUI). 30.6 % (15/49) recovered from preexisting SUI after twelve months. 40.4 % (21/52) suffered from urge urinary incontinence (UUI) prior to implantation. The rate of patients with UUI decreased to 8.2 % (4/49). The impairment through foreign body and prolapse sensation reduced from 86.5 % (45/52) and 84.6 % (44/52) to 2.0 % (1/49) and 0.0 % (0/49) after twelve months. Defecation disorder was initially reported by 11.5 % (6/52) of patients and by 6.1 % (3/49) after twelve months, respectively. During the clinical stay three hematomas were observed out of which one needed a surgical revision. 1.9 % (1/49) suffered from urinary retention. None required explantation of the mesh. There was no erosion of mesh through the vaginal wall.

Conclusion: The correction of a symptomatic cystocele with improved titanium coated polypropylene mesh leads to a low recurrence rate, a highly significant improvement of QoL and reduced impairment through POP-related symptoms. The risks are acceptable with absence of any mesh erosion or infections. A recently published study with 289 patients treated with a titanized polypropylene mesh for cystocele correction in a 36 month-follow-up demonstrated a significant improvement of patients' QoL and a very low recurrence rate, too. The erosion rate was low, but not low enough. However, the risk of erosion was reduced by improving the mesh due to larger pores and lower weight.

Furthermore, a very low rate of intraoperative complications and a low rate of de novo SUI as well as improvement of UUI could be achieved. Considering earlier safety concerns of the FDA on utilization of surgical meshes for POP repair, i.e. increased risk of infections, erosions, recurrence of prolapse, incontinence, intraoperative complications and decrease in QoL, the data obtained within these studies shows superior outcome in almost all aspects.

Therefore, the implantation of a 2nd generation mesh can be offered to patients with a recurrent or a higher grade prolapse after extensive patient information on the risks and benefits of mesh-supported POP repair.

## **Sacrocolpopexy: Advantages and disadvantages - a systematic literature review**

*DUMITRAȘCU MIHAI CRISTIAN, ALBU RUXANDRA ANDREEA, FODOROIU RĂZVAN, NENCIU CĂTĂLIN GEORGE, NENCIU ADINA, GORGOI CORINA OANA, CÎRSTOIU MONICA MIHAELA*  
*University Emergency Hospital, Bucharest, Romania*  
*drdumitrascu@yahoo.com*

Pelvic organ prolapse has become a common problem among women and because of the increasing incidence, several surgical techniques have been developed.

The current 'gold standard' surgical repair for pelvic organ prolapse is the abdominal mesh sacrocolpopexy because of its high success rate and excellent anatomic outcome. Other methods have also been developed, such as transvaginal, laparoscopic and robotic assisted surgical procedures.

The goal of this presentation is to determine the major advantages and disadvantages of these methods based on a systematic literature review.

Keywords: Sacrocolpopexy; Pelvic organ prolapse; Laparoscopy; Surgical procedure.

## **Combination of slings and site-specific fascial POP repair. Multicenter study.**

*BORIS SLOBODYANYUK1, YULIA DOBROKHOTOVA1, SVETLANA KAMOEVA2, ALEXANDER SLOBODYANYUK3, VALENTINA DIMITROVA4, SERGEY APRESSYAN4.*

*1 Pirogov Russian National Research Medical University RNIMU, gynecology, Moscow, Russia*

*2 Central Clinical Hospital of the Russian Academy of Sciences, pelvic floor and aesthetic medicine, Moscow, Russia*

*3 Zhukowsky clinical hospital, gynecology, Zhukowsky, Russia*

*4 Inozemtsev municipal hospital, gynecology, Moscow, Russia  
borisslo@inbox.ru*

**Background.** Due to FDA warnings regarding using mesh in vaginal surgery and medicolegal issues worldwide there are big intention to diminish use of synthetic material with good outcome and improvement of QoL. With development of Integral Theory by P.Petros we understand importance of precise anatomical restoration and augmentation all pelvic “ligaments” using polypropylene tapes with preserving vaginal tissues and it’s elasticity. We developed “low cost” variant of trocar guided variation of POP restoration “Total paracervical reconstruction”.

**Methods.** Procedure begins with the incisions of anterior and posterior vaginal wall, mobilization of the rectovaginal and pubocervical fascia, identification SSL, CL and internal obturator muscle. We use two 7mm wide low elastic polypropylene tapes. Posterior sling pass through SSL “inside-out” manner and fixing middle part in front of cervix. Anterior sling is passing through obturator foramen near attachment of ATLA to pubis symphysis (anterior transobturator approach). Both slings are fixed to the cervix anteriorly. After that, we restore fasciae in site-specific manner and plicate both cardinals in front of the cervix with prolene of PDS sutures thus covering the tapes anteriorly. If indicated, lax perineal body, anal spinster repair or MUS also performed when indicated.

**Results.** Since 2016 we have done 34 procedures in 4 clinics in Moscow region performed by senior surgeons. Indication was: different types of symptomatic POP 2-4 stages (POPQ). Simultaneous operations were: trachelectomy in 8,8%, LS supracervical hysterectomy in 8,8%, TVT-O in 23% cases, PB repair (29%) include EAS repair (3%). To estimate outcome we used: QOL questionnaires (PFDI-20, PFIQ-7, FSFI) and factor analysis of the symptoms according diagnostic algorithm, ultrasound examination of pelvic floor, Rö defecography if indicated. Operation time was 90±25 min. Blood loss never exceed 150 ml. We have 1 complication during perineoplasty breakdown of the needle which required wide dissection of right ishiorectal space results in hematoma of subcutaneous fat – without consequences. In all cases pain was mild (1-4 VAS) localized in perineal body or buttocks treated with NSAID not more 2-4 days. Mean follow up were 15±3 mounts. Erosion rate was zero. There were statistical improvements of functional results of symptoms before and after the operation: PFDI-20 115,5/48,7 (p<0,01), PFIQ-7 68,7/14,4 (p<0,01). Sexually active patients (58%) report improvements according FSFI (p<0,01). There was significant improvement of symptoms: bulge 96 to 0%, pelvic pain - 14 to 3%, dyspareunia 29 to 3%, obstructive urination 29 to 0%, frequency 47 to 6%, urgency - 11,7 to 0%, stress incontinence - 23 to 7% (in 7% cases of de novo SUI midurethral sling was performed during first 12 month), obstructive and dyssynergic defecation 17 to 3%, AI 7 to 0%, nocturia 29% to 0%. We noted 2 (5,8%) asymptomatic cases of cystocele and apical prolapse 2-nd degree without reoperation.

**Conclusions.** Short-term results make possible to consider this approach as effective minimally-invasive method of “functional surgery”. However, long-term multicenter studies are needed.



## **Vaginal reconstruction and laparoscopic Kapanji suspension is a good option for advanced apical POP in young patients**

ALEXANDER SLOBODYANYUK 1, BORIS SLOBODYANYUK 2, YULIA DOBROKHOTOVA 2.

1. Zhukowsky clinical hospital, Gynecology, Zhukowsky, Russia.

2. Pirogov Russian National Research Medical University RNIMU, gynecology, Moscow, Russia  
borisslo@inbox.ru

Background. POP still remains unresolved problem. In spite of plenty of methods described rate of recurrences are still high. We know that many “classical” operations didn’t provide normal anatomic position of pelvic organs which can lead to failure. That’s why in complex cases it’s reasonable to use some sort of prosthesis. Frankly speaking all this procedures per se are not ideal. For SSF vaginal vector of proximal vagina goes backward facilitate cystocele formation and SCP particularly promontofixation suspend vagina very high and frontally.

Methods. From January 2015 for young and sexually active patients with advanced prolapse ( $C < +7$  cm) we use combination of site-specific pericervical fascial reconstruction of pubocervical and rectovaginal fascia with bilateral SSF of vagina or cervix either with prolene sutures or transsacrosplinal sling and our developed 25 year ago laparoscopic version of Kapanji operation with fixation of vault or cervix in front of rectus sheath with long polypropylene tape. The sling passing form lateral trocar ports retroperitoneally via parametria and fix it with nonabsorbable sutures to cardinal-uterosacral complex or vaginal vault. Lateral portions of the slings pass in subcutaneous fat and suturing together with mild tension in front of rectus sheath. In rehabilitation program we always include PFMT.

Results. Total 11 patients enrolled in the study. Three with vault prolapse, 2 with cervical stump prolapse and other – uterine prolapse. Mean preoperative "C point" was 12 cm. Age was  $41 \pm 6$  year. Total procedure time was  $109 \pm 20$  min. Blood loss was minimal. In all cases we’ve got excellent results. Pain was minimal. Mean follow up was 20 month. No mesh related complications. The position cervix or vaginal vault was very high as well as anterior or posterior compartments. All patients didn’t experience any sexual discomfort. Due to SUI in 2 cases transobturator urethropexy were performed. According PFDI-20 and PFIQ-7, function of bladder and rectum was satisfactory without worsening of symptoms in any cases.

Conclusions. This laparovaginal method is highly effective for the young sexually active patients with 4-th degree advanced apical POP. On the one hand it provides correction of all defects at perineal level and 2-nd level, on the other hand strong long-term fixation of apical compartment with minimal complications in experienced hands.

## **Initial experience of Restorelle® direct fix anterior mesh in treatment of pelvic organ prolapse**

JILL CHENG SIM LEE, SHU QI TAN, JOLENE SIN SE PEH, HOW CHUAN HAN

jill.lee@mohh.com.sg

Introduction. Women have up to 50% lifetime risk of pelvic organ prolapse (POP) with 11.8% requiring surgery. There has been a role for transvaginal mesh (TVM) for treatment of POP since the 1990s. However, concerns due to mesh-related complications have arisen recently highlighting the need for more research to better select patients for TVM. This also helps clinicians provide thorough pre-operative counselling for women to make informed decisions.

Restorelle® Direct Fix Anterior Mesh is a light-weight (19g/m<sup>2</sup>) synthetic polypropylene mesh shaped for transvaginal anterior compartment prolapse repairs. Restorelle® was introduced at our centre in March 2017. New products cannot be assumed to have equal or improved safety and efficacy unless long-term data are available.

**Objective.** This study aims to describe the initial experience of a single urogynaecological centre with Restorelle®, in particular analyzing the surgical, anatomical and symptom-related outcomes following POP repair with Restorelle®.

**Methods.** Patients with Grade 3 or 4 cystourethroceles treated with Restorelle® at our urogynaecological centre between July 2017 and December 2017 were identified from the departmental database. Clinical characteristics and outcomes were identified through review of case notes. Post-operative follow-up data were collected up to 1 month post-treatment.

**Results.** 26 patients were treated with Restorelle®. The mean age was 67.2±7.3 years. All presented with symptomatic lump at introitus. 17 (65.4%), 11 (42.3%) and 9 (34.6%) reported concomitant frequency or nocturia, stress incontinence and urge incontinence respectively. 12 (46.2%) reported pre-existing voiding difficulties. 8 (30.8%) had prior hysterectomies.

19 (73.1%) patients had Grade 3 cystourethroceles while 7 (26.9%) had Grade 4 cystourethroceles. 4 (57.1%) patients with grade 4 cystourethroceles had hydronephrosis on pre-operative ultrasound.

18 (69.2%) underwent concomitant vaginal hysterectomy with Restorelle®. All underwent concomitant posterior colporrhaphy. 11 (42.3%) underwent concomitant mid-urethral sling procedures. 17 (65.4%) underwent sacrospinous ligament fixation. Duration of surgery was 116.3±20.8 minutes. Average estimated blood loss was 217.3±122.4ml. 3 (11.5%) patients required post-operative blood transfusion. Mean length of stay was 4.5±2.1 days. Median duration of urinary catheterization was 2.5(2-34) days. 4 (15.4%) had urinary retention beyond 14 days. 12 (46.2%) had fever for 1-3 days.

There were 2 intra-operative complications; 1 bladder perforation and 1 case where the left ureteric orifice was obscured at end-of-surgery cystoscopy. The latter case subsequently developed renal impairment secondary to kinked ureter at the level of pelvic floor repair post-operatively requiring surgical removal of Restorelle® with concomitant anterior colporrhaphy.

2 other patients required re-operation for urinary retention. 1 (3.8%) required loosening of Restorelle® while another (9.1%) required loosening of concurrently inserted mid-urethral sling.

At 1 month follow-up, there were 2 (7.7%) cases of abnormal urinary flow, 1 (3.8%) de-novo stress incontinence and 1 (3.8%) mesh extrusion into vagina. There were no recurrent cystoceles detected. All patients were pain-free and satisfied with surgery.

**Conclusions.** Cystoscopy is useful to identify surgical complications with Restorelle® treatment. Half the patients with post-operative urinary retention required surgical management.

Restorelle® provides high anatomical and symptomatic cure rates for Grade 3 and 4 cystourethroceles with good patient satisfaction.

These findings will improve pre-operative counselling for our patients.

## **Transperineal ultrasound as a complementary tool in the assessment of urinary incontinence in women**

*RADA MARIA PATRICIA 1, CIORTEA RĂZVAN 1, MĂLUȚAN ANDREI MIHAI 1, OANCEA MIHAELA 1, MOCAN-HOGNOGI RADU 1, BUCURI CARMEN ELENA 1, MIHU DAN 1*

*1 Department of Obstetrics&Gynecology, UMPH "Iuliu Hațieganu", Cluj-Napoca, Romania; "Dominic Stanca" Clinic, Romania  
mpr1388@gmail.com*

Urinary incontinence (UI) represents a condition that, although not vital, has a significant impact that can interfere with the well-being of affected females, its overall prevalence being of approximately 40%.

No standard imaging modality is mandatory in initial evaluation of patients with UI. Since 1920, urogynecologists showed an increasing interest in imaging of the pelvic floor, ultrasound being a reliable method of examination, easy accessible and inexpensive. At the beginning, B-mode ultrasound via transvaginal or transperineal route, was used to describe the urinary bladder and the anterior pelvic compartment and only later, the other compartments.

Pelvic floor dysfunctions include several conditions among which UI. The main indications for transperineal ultrasound are: recurrent urinary tract infections, urgency-, frequency-, stress-UI, dysuria, prolapse of pelvic organs, dyspareunia, fecal incontinence, pelvic masses. This method proves its utility in assessing parameters like: residual urine, detrusor wall thickness, mobility of the bladder neck, anterior and posterior urethrovesical angle, urethral integrity. Stress UI may be highlighted by Color Doppler. Studying the pelvic floor during contractions or Valsalva manoeuvre allows the assessment of the functional anatomy, keypoint for understanding the UI pathophysiology.

The assessment of these specific objective and reproducible parameters is complementary to the diagnosis of UI and puts several therapeutic options in a different light. The progress in imaging permanently contributes to the improvement of therapeutic management either refining existing techniques or supporting the development of new procedures in urogynecology.

## **Predisposing factors for uterine fibroid**

*DUCA OANA MONICA, LUPU MARY-NICOLETA, MATEI MADALINA, AUREL NECHITA  
oanam.duca@yahoo.ro*

Uterine fibroid represents one of the most common benign gynecological pathologies, whose causes of development are still incompletely elucidated. One of the predisposing factors, quoted in the literature, is hormonal disturbances, namely the high level of estrogen and low progesterone. The level of these hormones is influenced by age, body mass index and urban and rural areas inhabitants.

In this paper we tried to see if the appearance of uterine fibroid is influenced by these parameters.

**Results.** We performed a retrospective study on a group of 453 patients diagnosed with uterine fibroids and having total hysterectomy with bilateral salpingo-oophorectomy .

Depending on the age, 44.60% of the patients were younger than 45 years and 55.40% aged 45 years or over. The patient from urban areas had a frequency of 65.60% and the rural patients 34.40%.

It was observed that overweight patients had a higher incidence of 40%, followed by those who have obese class I (21%).

Correlating the age with the body mass index and the environment of origin with the age the results obtained were not statistically significant ( $p = 0.364$  vs.  $p = 0.478$ ).

Regarding the environment of origin and the body mass index the results obtained have signaled a poorly statistically significant association ( $p < 0.001$ ).

**Conclusions.** On the basis of statistical analyzes it was found that the appearance of the environment of origin and body weight influences the occurrence of uterin fibroid.

The age of the patients in the study group and its association with the environment of origin or BMI was not a factor in the development of uterine fibroids.

## **Innovative vaginal cones with vibrating ball inside in pelvic floor dysfunction**

*FEDERICO VILLANI<sup>2</sup>, E. MORATTI<sup>2</sup>, B. MINOPOLI, A. GUGLIELMINO, L. ARDUINI, A. FATUZZO,  
A.L. TATARU, C FURAU.  
vllfr@gmail.com*

**Introductions:** Pelvic floor muscle training (PFMT) is considered the first-line treatment for stress urinary incontinence (SUI) and urge urinary incontinence(UUI). Studies demonstrate that pelvic floor exercises, electrical stimulation and vaginal cones (VC) are equally efficacious treatments for SUI and far more effective than no treatment at all.

VC are cheapest non-surgical treatments for women with stress urinary incontinence and are able to manage also some sexual dysfunctions caused by pelvic muscle relaxation in an autonomous way. Opportunities for self-management by the women should be encouraged, as women can purchase VCs themselves or they can undertake PFMT without formal supervision. Therapies are

most likely to be effective and cost-effective when women receive training in order to know how to perform the exercises correctly.

From the several different physical therapies, in this multicenter trial we decide to test a new type of vaginal cone (VC) that has a vibrating ball inside like the Ben Wa ball.

Material and methods: The device is composed of a set of 3 vaginal cones of different weights (30 g, 47 g 65 g).

The cones have a new anatomical and more physiological shape that respects the vaginal mucosa in order to avoid any scratching or bleeding. It is 29mm in diameter, around 25% larger than conventional VCs to help the woman during exercises.

The device has a single body made of medical silicone and has a cavity containing a steel sphere rolling freely that causes vibration during exercise. These mechanisms help proprioception of pelvic muscle by the woman during training. ( Fig 1).

36 women took part of the study (range 26–78). The average number of vaginal deliveries per patient was  $1.65 \pm 1.71$  SD. The subject, who signed a consent form, was instructed to use the device for 15-30 minutes a day. When the patient no longer felt the cone was falling from her vagina, the next heaviest cone was used. This procedure was continued for three months. The patients were evaluated after one (T1) and three (T2) months.

During the gynecological examination, the patients were classified according to PC test. The scores were used to report the results of this procedure: 0 to 9 (0-3 for strength, 0-3 for endurance , 0-3 for fatigability).

At the end of the first and the last evaluation the women filled a QoL questionnaire composed by 13 questions.

Results: Out of the 36 women involved, 18 were with urgency, 7 with effort, 5 with mixed problems and 3 with sexual dysfunction only (Fig. 2). 10 dropped out from the study for lack of commitment and perseverance.

Out of the 26 women left 24 reported a clear improvement of the pathologies.

All women with sexual dysfunctions reported a gain of sexual pleasure.

All the 26 women reported an improvement of PC score between the first and last evaluation in all evaluation parameters. More specifically parameters from T0 to T3 increase: strength 18% endurance 22,6% 17% (Fig. 3).

The QoL shows an improvement. The average T0 score are  $3,95 \pm 0,68$  SD and the average T2 score are  $4,29 \pm 0,59$  SD (Fig 4).

No side effects such as pelvic pain, vaginal infections or other complaints was reported by patients during the last meeting.

Conclusion: It can be noted that this new type of VC wants to confirm that vaginal cones may be an instrument that is still modern and usable especially in countries where pelvic floor rehabilitation is not yet full known and understood and we can have a useful tool to give to women when PFMT is needed. A complete training leads to an improvement of pathologies related to the weakness of the pelvic floor. It should be considered as first-line treatment for these pathologies,. The verifiable limit to the treatment is the arbitrary level of commitment..

It is our advice to propose the device to all the women that risk pelvic floor dysfunction for primary care, mainly in high risk periods like postpartum and premenopause.

This methodology allows freedom and empowerment to women, thanks to the autonomous use of the device without any additional costs for the National Health System.

*Figure 1: PelviK Vaginal Cones*

*Figure 2: Percentage of Pathologies*

Figure 3: PC Score at different times (number ± SD), classified for each category of evaluation

Figure 4: QoL Results for each answer ( number ± SD)

## Application of titanium mesh in reconstructive surgery of POP

SVETLANA KAMOEVA, ANTON KAZANTSEV<sup>1</sup>, ALEXANDER ALEKHIN<sup>1</sup>, BORIS SLOBODYANYK<sup>2</sup>, YULIA DOBROKHOTOVA<sup>2</sup>, TATIANA IVANOVA<sup>1</sup>, EKATERINA PANOVA<sup>1</sup>.

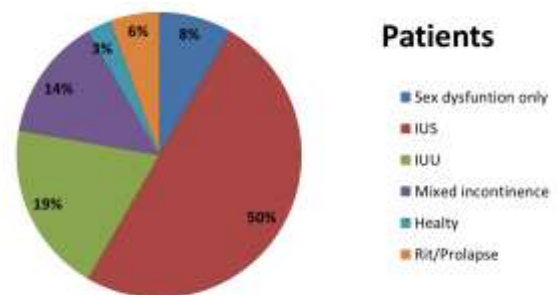

1 Central Clinical Hospital of the Russian Academy of Sciences, Moscow, Russia.

2 Pirogov Russian National Research Medical University RNIMU, Moscow, Russia.

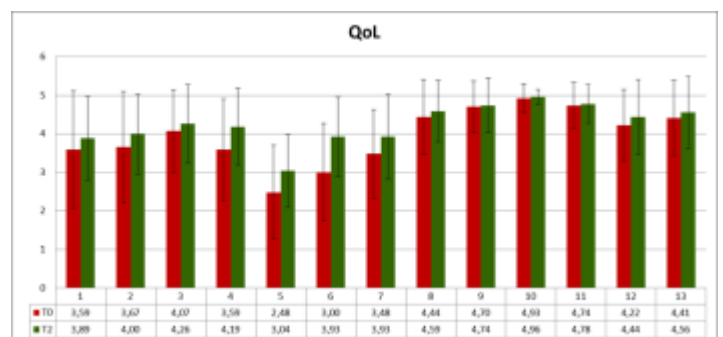
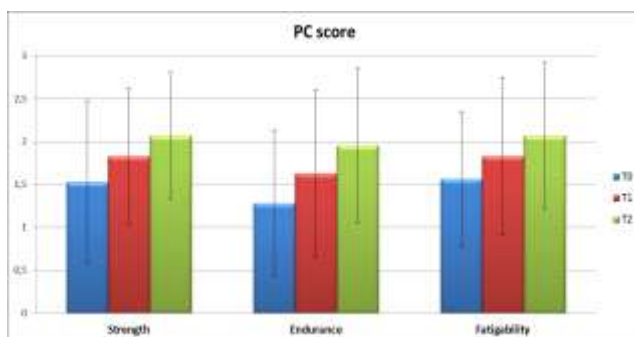
sv02016@yandex.ru

Background: An interest to transvaginal minimally-invasive approach to sacrospinous colpopexy is increasing among pelvic reconstructive surgeons. There is no ideal material for pelvic reconstructive surgery but in our opinion more close to it super-light scaffold «titanium silk» (density 25-55 g/m<sup>2</sup>), made of 0,06 mm thread with pore size 0,5-2 mm, elasticity 40-80% and porosity 96%. This material more bioinert and elastic compared to polypropylene and restore its original shape after tension and can be cut for making individual shape in each particular case. Moreover, in comparison to standard methods, using PP due to rather different properties (much more roughness, resistance in tissues and hyper-elasticity) we use in several times less foreign material. After implantation it provide good support and more adequate remodeling of ECM with prevalence of “mature” collagen 1 type in comparison to polypropylene. It’s been showed in vivo on rabbit model that titanium is resistant to oxidative damage and result less shrinkage in comparison with polypropylene thus provides more stability. The objective of this study was to assess effect of restoration of POP (apical and anterior prolapse) using titanium super-light mesh.

Material & Methods: We’ve analyzed 52 women with POP-Q stage 2 or greater apical and/or anterior prolapse in the Center of the pelvic surgery of Central Clinical Hospital of the Russian Academy of Sciences from April 2017 to May 2018. After hydrodissection full thickness transverse incision of



anterior vaginal wall was made. Blunt dissection is performed towards the ischial spine, identifying the sacrospinous ligaments. Then the reusable suturing device SeraPro® was used for place suture in sacrospinous ligament 2-3 cm medially of the ischial spine with prolene sutures. For the reconstruction of



fascial defects 11x6 cm titanium scaffold were implanted. By means of traction of edges we made 4 arms of this titanium mesh and fix them to sacrospinal ligaments and through internal obturator muscle, one centimeter behind anterior attachment of ATFP to pubis. Then we fix mesh to cervix if present and paravaginal tissues in order to stabilize medial part. In addition we perform site-specific rectocele repair and perineoplasty if indicated.

Results: Mean operative time were 34,4±5,3 min. No intraoperative complications were observed. Early post-operative complications were: febrile temperature during 24 hours 5 (8,9%), nonobstructive bladder atony after cystocele 4<sup>th</sup> degree repair in 2 cases (3,8%). Also we noted asymptomatic cystocele relapse 2<sup>nd</sup> degree POP (Aa-1) in 3 (5,8%) cases. Mean follow-up was 12 months. Forty eight (92%) of the patients were considered as optimal or satisfactory anatomical result according NIH criteria (POP-Q 0-1). The vaginal sonography shows correct position of mesh and elastic vagina without scarring and deformation of surrounding structures. It is impossible to palpate implant except obturator and SSL points of insertion. Vaginal wall was mobile and elastic in all cases.

Conclusion: Ultra lightweight titanium mesh augmented POP repair showed minimal complications rate comparable to conventional surgery. Our data suggest that titanium meshes is excellent for anterior and apical compartments, preserves vaginal elasticity and provide good remodeling of tissues, anatomic and functional outcome at short-term follow-up.

Keywords mesh, «titanium silk», POP

## **Perspectives of Pelvic Minority in Croatia - Croatian Pelvic Society**

*RAJKO FUREŠ<sup>1-4</sup>, DAMIR HODŽIĆ<sup>4,5</sup>, JADRANKA ŠANJUG<sup>1-4</sup>, IVICA BALAGOVIĆ<sup>1-4</sup>, TONČI VISKOVIĆ<sup>1-4</sup>, MARTIN GREDIČAK<sup>1-4</sup>*

*1 General Hospital Zabok and Croatian Veterans Hospital, Zabok, Croatia.*

*2 Faculty of Medicine Osijek. University of Josip Juraj Strossmayer – Osijek, Croatia.*

*3 Faculty of Dental Medicine and Health - Osijek.*

*4 Croatian Society for Pelviperineology.*

*5 Department of Gynecology and Obstetrics. University Hospital "Mercur", Zagreb, Croatia  
rajko.fures@kr.t-com.hr*

In its work, the Croatian Pelvic Society (CSP) has a group of clinicians and other health professionals who share a common professional interest in the pelvis and related organs, especially in the pelvis surgery, conservative therapy and prevention and rehabilitation, with the aim of improving pelvic health. It is certain that the pelvis area requires multidisciplinary and integrative approaches to various professional profiles that need to collaborate in team work with experts of various specialties. Likewise, because of the complexity of this unique anatomical region, it is important to include not only experts from different disciplines, especially gynecologists, urologists and colonists, but also a number of specialists of many specialties and profiles, such as oncologists, neurologists, radiologists, physiotherapists, general practitioners, midwives, nurses, etc. The Croatian Society for Palpiperineology (CSP) was established in 2017 in the Zabok General Hospital and Croatian Veterans Hospital [https://www.croatia.hr/nl-NL/experiences/health-and-wellness / General Hospital-Zabok-and-Hospital-Croatian-Veterans](https://www.croatia.hr/nl-NL/experiences/health-and-wellness/General-Hospital-Zabok-and-Hospital-Croatian-Veterans). The Society (CSP) is particularly active in the field of education, clinical and research activities and enlightenment activities among health and non-health workers and the entire community. With such multidisciplinary and integrative approach, new ideas and approaches have been developed for even more successful treatment of our patients. In this way, the Croatian Society for Hyper-Pelvic Sociology (CSP) becomes widespread and present in this part of the world, especially for its integrative and multidisciplinary approach to pelvic diseases, as it enables a multifaceted connection of opinions, ideas, practices and research of its members and other experts. Similarly, the website <https://hdp-csp.hr/> is designed and developed to facilitate the processing of this potentially respectable knowledge base. It should share and use the maximum advantage for the recognizable benefit of our patients as the ultimate recipient. The Society (CSP) has already organized the 1st Mediterranean Pediatric Surgery and

Pelvipiperinology Meeting, Zagreb, Croatia, from 1 to 4 December 2017. <http://www.otours.hr/en/clinical-nutrition-in-the-era-of-postmodernism-2-2/>. The Croatian Pelvic Society (CSP) continuously organizes monthly professional, educational lectures and gatherings all over Croatia, each time in another city, where local medical societies are hosted. The Society also organized a successful Multimedia Interactive Educational Conference on Pelvic Surgery and Pelvicology in Zabok (Castle of Gredice), Croatia, from 18 to 19 May 2018, <https://hr-hr.facebook.com/HotelDvoracGjalski/>. In the forthcoming short-term and long-term period, the Croatian Society for Pelvic and Pelvic Sociology plans a number of educational projects in the Republic of Croatia and beyond, in cooperation with related companies. Pelvipiperinology in Croatia - the Croatian Society for Pelvipiperinology  
Email: rajko.fures@kr.t-com.hr;

## **Midurethral sling TOT procedure for the treatment of stress urinary incontinence – our experience**

*MIRCEA OCTAVIAN POENARU<sup>1,2</sup>, BRAICU FLAVIA<sup>2</sup>, ANCA DANIELA STANESCU<sup>1,2</sup>, LIANA PLES<sup>1,2</sup>*

*1 Carol Davila University of Medicine and Pharmacy, Romania*

*2 St John Hospital Bucharest, Romania*

*plesliana@gmail.com*

**Background.** Stress urinary incontinence (SUI) affects 4 to 35 percent of women [1]. SUI occurs when an increase in intraabdominal pressure exceeds urethral closure pressure, resulting in the involuntary leakage of urine. The first midurethral sling, introduced in 1996, was placed by passing trocars with mesh through the retropubic space. Transobturator slings were introduced in 2001 with the goal of avoiding some of the complications of retropubic insertion (eg, bladder perforation, vascular injury, bowel injury).

**Material and method.** We have studied articles from the literature and the experience of the “ Bucur” Clinic of Obstetrics and Gynecology during January 2010 - December 2016 for the modern indications of synthetic meshes in the surgical treatment SUI.

**Results.** During January 2010 and December 2016 in the "Bucur" Obstetrics and Gynecology Clinic, 320 women with urogenital disorders were surgically treated. There were 118 cases of prolapse of the anterior vaginal wall, 82 of them associating urinary incontinence. Were performed 67 transvaginal synthetic meshes, transobturator procedure (TOT) and Kelly technique was systematically used for the surgical treatment of manifest or masked SUI. Cases of isolated SUI (61 patients) were resolved by midurethral sling TOT. We recorded 4 cases of erosion of the vaginal mucosa (2 after the midurethral sling), 1 pelvic-perineal hematoma, 2 recurrences of the previous prolapse and 3 recurrences of urinary stress incontinence (1 after midurethral sling). From a total of 131 interventions in which prosthetic material was used, only 5% were considered unsuccessful or had complications.

**Discussions.** The low rate of complications and relapses is much lower than reported meta-analyzes, up to 20%. The finding would recognize as the main explanation the lack of long-term follow-up. On the other hand, account should also be taken of the predominantly urban addressability of a feminine population with risks and factors of lesser recurrence (low degree of parity, increased incidence of cesarean surgery, less physically demanding profession, hygienic-sanitary conditions etc )

**Conclusions.** Midurethral transobturator sling used for the treatment of urinary stress incontinence is a safe surgical technique with high success rate. Despite the complication rate of up to 20%, the procedure become the first choice procedure for management of this pathology.

## **Transvaginal versus transperineal ultrasound in the evaluation of the cervix after cerclage**

*OLARU OCTAVIAN GABRIEL<sup>1,2</sup>, ROMINA MARINA SIMA<sup>1,2</sup>, LIANA PLES<sup>1,2</sup>*

*1 Carol Davila University of Medicine and Pharmacy  
2 St John Hospital Bucharest  
plesliana@gmail.com*

**Objectives:** to compare the acceptability and efficacy of transvaginal versus transperineal ultrasound for the assessment of cervical canal post-cerclage.

**Method:** On cohort of 67 pregnant women who underwent cervical cerclage for incontinent cervix in the midtrimester pregnancy, an ultrasound exam was performed 48 hours after the procedure, to evaluate the status. They had previously given their informed consent and completed a questionnaire specifying how ultrasound verification (transvaginal or transperineal) of cervix will be performed.

**Results:** 58 of patients opted for transperineal route. However, the cervix could not be satisfactorily examined in this way than in about 75% of patients. For those patients who could not be examined the transvaginal route was adopted and offered a proper assessment of the cervix. No adverse events were reported after the transvaginal examination. As a result we propose an examination algorithm in which the first option is the transperineal examination. If it is either not possible to realize (the exam of the cervix) or not possible to obtain acceptable data by this way, then we should use the transvaginal exam.

**Conclusions:** Transperineal examination of the cervix after the cerclage has a higher acceptability rate comparative with the transvaginal way but the reliability of the transvaginal evaluation, has greater accuracy than transperineal examination.

## **What else can be done in preventing stress urinary incontinence?**

*CORINA GRIGORIU, STELUTA MARIUTAN-GEORGESCU, MIRELA MIHAILA, LUCICA VISAN,  
DIANA MUNTEANU, R. M. GRIGORIU  
corigri@gmail.com*

**Objective** Stress urinary incontinence (SUI) recognizes as major risk factor obstetrical trauma, lower quality of supporting tissue, constant overload of the pelvic floor through obesity, chronic constipation, chronic cough or physical strain.

**Method** One of the main methods of prevention of SUI is the preparation of the antepartum perineum (Kegel exercises, etc.), supervised labor, as far as possible without augmentation of uterine contractions and non-physiological shortening of the periods of birth, judiciously executed episiotomy, re-education of the perineum after birth and – as possible- avoiding all the other above mentioned risk factors. Complementary medicine can be of real help in this regard.

**Results** 1. Phytotherapy: Raspberry leaf tea (*Rubus idaeus foliae*) administered from the second trimester of pregnancy; gemmotherapy with raspberry extracts from the very beginning of pregnancy; perineal massage with sweet almond oil or olive oil (after 34 pregnancy weeks). 2. Apitherapy: supplementing the diet with pollen and royal jelly provides a improved trophicity of maternal tissues. 3. Homeopathy. A homeopathic consultation at the beginning of pregnancy can recognize the sensitive type and the chronic reactionary mode of the future mother. The specific homeopathic remedies favor good tissue reactivity in pregnancy, during birth and postpartum. Thus, complications and sequelae of birth can be prevented (examples of remedies: *Actaea racemosa*, *Sepia*, *Silicea*, *Equisetum*, *Pulsatilla*, *Ferrum metallicum*, *Arnica* etc), prescribed as a personalised treatment.

**Conclusion** Muscular microtraumatism, lacerations of fascia and ligaments, involvement of microvascularization and pelvic floor innervation are inevitable throughout birth. Having some simple and cheap prevention methods available, we think it is appropriate for them to be known by obstetricians. Collaboration with specialists in complementary medicine can bring real benefits to patients.

## **Recurrent stress urinary incontinence after primary surgical treatment**



*CORINA GRIGORIU, CORINA PARAU, LUCICA VISAN, DIANA MUNTEANU, MIHAI GRIGORIU  
corigri@gmail.com*

**Objective** Recurrent stress urinary incontinence (SUI) refers to recurrence of SUI symptoms after a period without symptoms following surgery. The incidence of recurrent SUI ranks between 6-14%, being less frequent after sling procedures.

**Method** We analysed the risk factors associated with recurrent SUI: the mixed incontinence (the association of urgency urinary incontinence), urethral incompetence, obstructive voiding symptoms, advancing age, obesity and diabetes. There is also a constant debate about particularities of neuromuscular function in women with recurrent or persistent SUI after a first surgery.

**Results** The clinical exam has to exclude non-stress causes of incontinence, to assess the severity of symptoms (and, hence, the disturbance of quality of life QoL) and to evaluate other surgical or medical factors and their implication in choosing a treatment. The paraclinical approach consists of: urinalysis, cystoscopy, postvoidal residual urine, the cough stress test, the assessment of urethral mobility, a dye test (if the women underwent a hysterectomy), urodynamic studies, ultrasonographic evaluation (sling position). Patients without significant influence on QoL may be managed expectantly. If the patients needs treatment, several steps may be taken: pelvic floor muscle exercises, vaginal pessary, periurethral injection therapy or surgical treatment (with averance of risk of failure or surgical morbidity).

**Conclusion** Patients with recurrent SUI should be addressed to a experienced urogynecologist. The recommended surgical procedure in patients with recurrent SUI is a midurethral or bladder neck sling rather than retropubic urethropexy (Burch colposuspension).

## **Bladder Pain Syndrome / Interstitial Cystitis (BPS/IC), a multidisciplinary approach**

*ANDREI MANU-MARIN*

*Evomed Pelvic Care Center*

*andrei.manumarin@yahoo.com*

**Introduction.** BPS/IC is defined as pain or discomfort related to bladder filling associated, mainly, with urinary frequency. The discomfort can be described as persistent or recurrent symptoms of pelvic pain associated with symptoms suggestive of lower urinary tract and, also, sexual, bowel or perineum dysfunctions. The treatment of these pathologies must address all aspects of bladder pain, central pain, depression, anxiety and also, when present, the retraining for dysfunctional voiding and difficult bladder emptying.

**Method.** It is reviewed the diagnostic approach and the treatment guidelines of BPS/IC and the algorithm used at our clinic. The interdisciplinary approach is presented.

**Conclusion.** Neuropathic pain modulation, peripheral electrical stimulation, instillation therapies, pelvic floor biofeedback are all used in combination with psychotherapy to obtain symptom improvement.

## **QoL after Cystocelerepair**

*C. FUENFGELD<sup>1</sup>, M. GREBE<sup>2</sup>, B. HENNE<sup>3</sup>, J. KAUFHOLD<sup>4</sup>, M. MENGEL<sup>5</sup>, M. STEHLE<sup>1</sup>,  
D. WATERMANN<sup>6</sup>*

*1 Klinik Tett nang, Tett nang, Germany*

*2 Krankenhaus Dresden Friedrichstadt, Dresden, Germany*

*3 St. Elisabeth Krankenhaus Leipzig, Leipzig, Germany*

*4 Klinikum Ludwigsburg, Ludwigsburg, Germany*

*5 Frauenklinik Zittau, Zittau, Germany*

6 Diakoniekrankenhaus Freiburg, Freiburg, Germany  
chr.fuenfgeld@t-online.de

Pelvic organ prolapse (POP) significantly impairs the function of bladder, bowel and sexuality and reduces quality of life (QoL). The aim of POP surgery is the recontraction of the the anatomical position and improvement of QoL. According to the Cochrane database a significantly lower rate of recurrent prolapse is reported for mesh-supported cystocele reconstruction. However, the potential for mesh-induced risks has led to a controversial discussion concerning the use of surgical meshes in urogynecology.

**Objective:** The purpose of this study was to investigate anatomical stability, complications, improvement of QoL, and the influence on POP-related symptoms after 36 months in a high number of patients.

**Material and Method:** In a large prospective multicenter study 289 patients with symptomatic cystocele > Stage I (ICS classification) were treated with implantation of a titanium coated polypropylene mesh (TiLOOP® Total 6, pfm medical ag) via transvaginal route. A 6-armed mesh was placed using a tunneler for a transobturator and ischioirectal approach and fixed distally, laterally and apically at the sacrospinal ligament. Anatomical outcomes were quantified using the POP-Q system. A recurrent prolapse was defined as > -1 cm: Stage  $\geq$  II. POP-related QoL and symptoms were evaluated pre- and postoperatively. QoL was assessed using the German version of the validated P-QoL questionnaire. All adverse events were assessed by an independent clinical event committee. After 36 months data was recorded for 269 patients. The study was followed by 100% monitoring and supervision through external auditing.

**Results:** Stage II prolapse was diagnosed preoperatively in 47.1% (136/289) of patients; 49.8% (144/289) had a Stage III prolapse, and 3.1% (9/289) suffered from a Stage IV prolapse. The recurrence rate in the treated anterior compartment was very low (4.5%). QoL improved significantly in all nine investigated domains, including sexuality and personal relationships ( $p < 0.001$ , Wilcoxon test). The impairment through prolapse sensation and foreign-body-sensation reduced from 77.9% to 3.7%. Urgeincontinence from 36.0% to 8.9%. Fecal incontinence from 4.8% to 1.9%. The rate of denovo stressincontinence was 20.3%. 18.5% of patient were healed from a preexistent stressincontinence. Intraoperative and perioperative complications were rare: bladder lesions in 1.7% (5/289) of cases, and ureteral injury or bleeding requiring transfusion were reported in 0.3% (1/289) each. Urinary tract infection or infected hematomas were diagnosed in 1.0% (3/289) of cases. 0.3% (1/289) of patients experienced positional pain. In 56.7% (17/30) of these erosions, medication or an outpatient procedure performed under local anesthesia were sufficient. 43.3% (13/30) of cases required surgical intervention under general anesthesia; none required explantation of the mesh. 46.7% (14/30) of all erosions were described as asymptomatic.

**Conclusion:** The correction of a symptomatic cystocele with a titanium coated polypropylene-mesh has a low recurrence rate, a high significant improvement of quality of life and a reduction of impairment through POP-related symptoms. The risks are acceptable. Therefore the implantation of a 2<sup>nd</sup> generation-mesh can be offered to patients with a recurrent or a high-grade prolapse after extensive patient information on the risks and benefits of mesh-supported POP repair.

## **Tissue fixation system (TFS) Sling Operation To Repair Pelvic Organ Prolapse In Women Of 80 Years And Older**

*HIROMI INOUE*

*OB& GYN Department and Urogynaecology Center, Shonan Kamakura General Hospital,  
inoue@shonankamakura.or.jp*

**Objective:** The objective of this study was to evaluate the feasibility, intraoperative complication, and follow-up results of the Tissue Fixation System (TFS) procedures in women of 80 years and older with pelvic organ prolapse (POP).

**Method:** Sixty-two patients over the age of 80 years with POP between January 2007 and May 2018 were eligible for this retrospective case series.

The indication for surgery was a complaint of severe POP with no desire for a pessary or a history of problems with pessaries. All patients strongly desired for prolapse surgery. The TFS sling (U sling, Cervical sling, USL-sling and Peritoneal body sling) operations were originally performed as reported by Petros & Richardson. Operations using the TFS anchor system were performed on 62 patients for grade 3 or 4 pelvic organ prolapses ( uterine prolapses and vault prolapses) . The mean follow-up time was 28.4(range, 3-108) months.

Result: The TFS sling operation was well tolerated by patients with regard to surgery and anesthesia. The mean operative time was 88.8(range, 50-180)min. There was no intraoperative and postoperative complication. The mean hospital stay was 0.7(range, 0-4)days. Five patients(9.0%) developed prolapse recurrence, and mesh erosions were observed in 4.8% (10slings )of 207slings. At the mean follow-up, cure rates of symptoms due to pelvic laxity were: SUI 81.2%, nocturia 67.7%, urinary urgency 71.4%, dragging pain 71.4% and fecal incontinence 66%.

Conclusion: Treatment of advanced prolapse using the TFS sling operation in very elderly women is a feasible, safe, and effective surgical option. There is a significant improvement in the quality of life for these women.

## **The role of episiotomy in the occurrence of pelvic floor disorders**

*DIANA BADIU<sup>1</sup>, DAN NAVOLAN<sup>2\*</sup>, ROXANA BOHILTEA<sup>3,4</sup>, RADU VLADAREANU<sup>5</sup>*

*1 Faculty of Medicine, Ovidius University of Constanta (Romania)*

*2 Department of Obstetrics-Gynecology and Neonatology, "Victor Babeş" University of Medicine and Pharmacy, Timișoara (Romania)*

*3 University of Medicine and Pharmacy "Carol Davila" Bucharest (Romania)*

*4 Department of Obstetrics and Gynecology, University Emergency Hospital Bucharest (Romania)*

*5 Department of Obstetrics and Gynecology, Elias University Hospital, "Carol Davila" University of Medicine and Pharmacy, Bucharest (Romania)*

*\* Correspondence: navolan@yahoo.com*

Pelvic floor disorders are late complications of vaginal birth and multiparity. The majority of pelvic changes after birth are remitted, but the symptoms persist in a number of cases. The healing of perineal trauma during delivery depends not only on the presence of tears but also on the method used to repair them. Although the routinely performed episiotomy was considered to be a protective factor for pelvic floor disorders, its protective role is debatable nowadays. It has been believed that episiotomy could result in better wound healing than suture of tears in the absence of this technique. However, episiotomy could be associated with complications like lacerations, urinary incontinence, dyspareunia, etc. Therefore, data showed that restrictive episiotomy could have more advantages than routine episiotomy and could lead to less perineal trauma. In our review, we present evidence that led to changing practices and the debate that has surrounded the episiotomy technique.

Keywords: episiotomy, delivery, urinary incontinence, pelvic floor disorders.

## **Episiotomy rate in developing countries**

*DIANA BADIU<sup>1</sup>, DAN NAVOLAN<sup>2\*</sup>, ROXANA BOHILTEA<sup>3,4</sup>, RADU VLADAREANU<sup>5</sup>*

*1 Faculty of Medicine, Ovidius University of Constanta (Romania)*

*2 Department of Obstetrics-Gynecology and Neonatology, "Victor Babeş" University of Medicine and Pharmacy, Timișoara (Romania)*

*3 University of Medicine and Pharmacy "Carol Davila" Bucharest (Romania)*

*4 Department of Obstetrics and Gynecology, University Emergency Hospital Bucharest (Romania)*

*5 Department of Obstetrics and Gynecology, Elias University Hospital, "Carol Davila" University of Medicine and Pharmacy, Bucharest (Romania)*

*\* Correspondence: navolan@yahoo.com*

Despite new recommendations advocating for restrictive use of episiotomy, the use of this technique is common. Studies from different centers and countries provide data regarding the usefulness and indication of episiotomy. From a statistical point of view, the rates of episiotomy showed to be high in the majority of countries. Episiotomy is used to protect perineum from laceration. At the same time episiotomy is mentioned to be associated with some complications (i.e. dyspareunia, pelvic pain, sexual dysfunction, and urinary and fecal incontinence). Therefore, the advantages and disadvantages of this procedure should be evaluated for each case. In this context, effective strategies are needed in order to develop new evidence-based protocols. The aim of our presentation is to reveal data about the indication of restrictive episiotomy in the recent literature.

Keywords: episiotomy, procedure, public health, developing countries.