

Surgical cure of chronic pelvic pain, associated bladder & bowel symptoms by posterior sling in 198 patients validates the Pescatori Iceberg principle of pelvic symptom co-occurrence

KLAUS GOESCHEN¹, DARREN M. GOLD²

¹ University of Hanover, Germany, Dept. of Surgery Henriettenstiftung, Hannover

² University of NSW, Professorial Dept of Surgery, St Vincent's Hospital, Sydney

Abstract: Purpose: The treatment of pelvic organ prolapse, chronic pelvic pain, bladder and bowel dysfunction is largely single-symptom specific and frequently treated by a singular discipline; urology, gynaecology or coloproctology. The presence of occult symptoms in colorectal pelvic floor patients has previously been demonstrated by the Pescatori 'iceberg' concept: other symptoms are latent and often ignored. **Methods:** One hundred and ninety-eight patients, mean age 69 years (48-72), presenting with chronic pelvic pain (CPP) were evaluated using the validated Integral Theory System Questionnaire (ITSQ), which diagnosed pubourethral, uterosacral and cardinal ligament laxity as the principal causes of the apical prolapse, CPP, bladder and bowel symptoms. These were reinforced with transobturator and infracoccygeal sacropepy tapes. **Results:** CPP and apical prolapse were present in 198 patients; apical prolapse Grade 1 (n=15), Grade 2 (n=39), Grade 3 (n=107) and Grade 4 (n=37). Anatomic cure rate for apical prolapse was 99% (p<0.001). Symptom prevalence (% cure at 12 months in brackets): pelvic pain 198 (74%, p<0.001); urinary frequency: 127 (80%, p<0.001); bladder emptying difficulties: 68 (54%, p<0.001); urinary stress incontinence: 66 (95%, p<0.001); nocturia: 63 (79%, p<0.001); obstructive defecation: 59 (80%, p<0.001); urge incontinence: 55 (80%, p<0.001); residual urine >50ml: 44 (55%, p<0.001). Two (1%) of 198 patients with grade 3 prolapse developed a high grade 2 cystocele, which was subsequently repaired. No tape erosions were observed at 12 months. **Conclusions:** Identification and cure of 'latent' symptoms affirmed the validity of Pescatori's 'Iceberg' concept and the theory, on which the surgery is based.

Key words: Chronic pelvic pain; PIVS; Infracoccygeal sacropepy; Pescatori iceberg.

INTRODUCTION

The association of chronic pelvic pain (CPP) with other urogenital disorders is well known and has been especially noted by Expert committees from the International Continence Society (ICS)¹ and the European Urology Association². However, no specific relationship between specific symptoms was described by these committees in their deliberations. Recommendations for treatment of organ prolapse, chronic pelvic pain, bladder and bowel dysfunction is largely single-symptom specific. The result is that treatment is carried out by three different disciplines; urology, gynecology or coloproctology. Other conditions frequently remain latent or ignored.

The problem of the fractured uni-disciplinary approach to this problem was addressed by Pescatori et al.³. One hundred consecutive patients, who presented with Obstructive Defecation Syndrome (ODS), were investigated thoroughly for other conditions, and these were noted in a novel "iceberg" diagram (Figure 1).

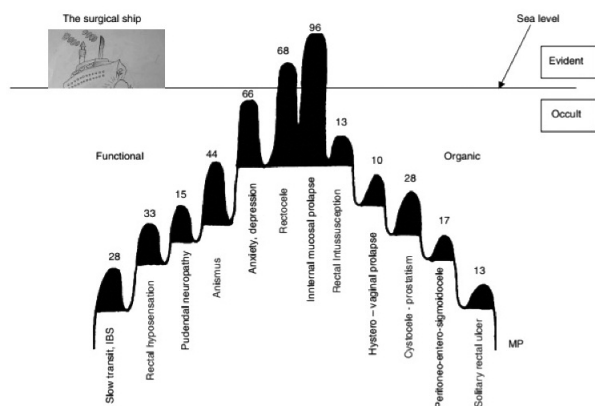


Figure 1. – *Original Pescatori Iceberg*. The presenting symptoms ODS is above the waterline. This was the patient's presenting symptom and focus. After and with Permission from M. Pescatori³.

These symptoms, though present, were not uppermost in patients' consciousness and had to be searched for.

A specific association between apical prolapse and CPP, bladder symptoms of urgency, nocturia and abnormal emptying was described in 1993 as "Posterior Fornix Syndrome", as part of the Integral Theory⁴. The Posterior Fornix Syndrome was expanded by Abendstein et al. in 2008 to include anorectal disorders⁵. The authors reported a significant cure rate of obstructive defecation (ODS), faecal incontinence, CPP and other posterior fornix symptoms following repair of the uterosacral ligaments⁵.

We report a prospective study of 198 patients from the European Centre of Excellence For Reconstructive Pelvic Surgery, a tertiary referral clinic from Hannover, Germany. In all 198 patients, the presenting symptom was chronic pelvic pain, 'CPP' as described in 1996⁶.

The aim of the study was

1. To investigate the incidence of other pelvic floor symptoms and derive an odds ratio for each symptom relevant to CPP, and
2. To assess the improvement of CPP and the other symptoms following a posterior sling to correct the apical prolapse.

This study was approved by the Ethics Committees of the Kvinno Center Hannover. Written informed consent was obtained from all patients. The principles of the Helsinki Declaration (2008) were followed.

MATERIALS AND METHODS

One hundred and ninety-eight patients, mean age 69 years (48-72), presenting with chronic pelvic pain (CPP) were prospectively assessed for 'latent' symptoms using the Integral Theory System Questionnaire (ITSQ). At the first consultation, all patients completed a self-administered validated ITSQ⁷, whose answers were transferred to a Pictorial Diagnostic Algorithm, which served as a guide to surgery.

TABLE 1. Association of pelvic symptoms with Chronic Pelvic Pain (n=198).

	No Hysterectomy n=132 (100%)	Hysterectomy n=66 (100%)	Total n=198
Frequency/ Urge	81 (61%)	46 (70%)	127 (64%)
Nocturia	42 (32%)	21 (32%)	63 (32%)
Bladder Emptying	40 (30%)	28 (42%)	68 (34%)
Urge incontinence	25 (19%)	30 (45%)	55 (28%)
Stress incontinence	40 (30%)	26 (39%)	66 (33%)
Obstructed defaecation	35 (27%)	26 (39%)	61 (31%)
Faecal incontinence	31 (23%)	25 (38%)	56 (28%)

All patients were examined (pre- and postoperatively) and operated upon by the senior author (KG). Pre-operative cystometry was performed in all patients. Additionally the amount of residual urine was calculated by ultrasound⁸. All patients underwent a vaginal examination to assess the degree of prolapse and to detect specific anatomical defects according to the ITS.

Inclusion criteria (Table1.) CPP as previously described [4] and some degree of uterine/apical prolapse where no other cause was evident.

Exclusion criteria. Younger patients with other known causes of CPP such as chronic pelvic inflammatory disease, endometriosis etc.

The pain was invariably severe, frequently one-sided, but often bilateral, situated low in the right or left iliac fossa, usually relieved on lying down. Frequently it could be relieved by insertion of a ring pessary and/or reproduced on palpating the cervix and displacing it posteriorly with the patient in the supine position. Although the pain was chronic in nature, it varied considerably over time with regard to intensity. There was often a history of deep dyspareunia, which only occurred on deep penetration, or in specific positions. Frequently the patient complained of a constant lower abdominal pain the day after intercourse. Patients often complained of low sacral backache⁴.

Included in this study were only patients presenting with CPP and at least two Posterior Fornix Syndrome symptoms as detailed in Table1; the percentage ratio of a symptom to CPP is indicated in brackets separately for patients with and without prior hysterectomy (HX); the combined numbers and percentage frequencies are recorded in Figure 2.

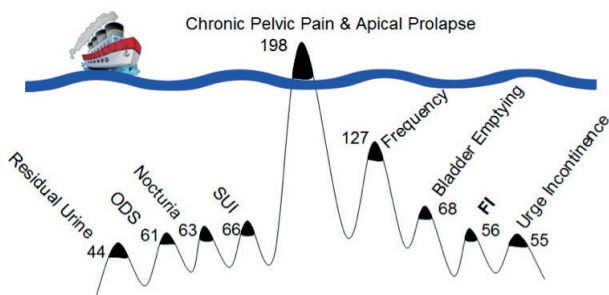


Figure 2. – Pescatori Iceberg applied to Chronic Pelvic Pain (CPP).

The symptom prevalence is graphically indicated in the iceberg diagram, latent symptoms below the waterline. All symptoms derived from the Integral Theory Symptom Questionnaire (ITSQ). Numbers indicate combined total of the hysterectomy and non-hysterectomy cohorts.

The percentage ratio of a symptom to CPP is indicated in brackets. The combined numbers are recorded in Figure 2 and the odds ratio per symptom for the whole cohort (198) is indicated in next to the symptom.

Surgery

Patients with stress incontinence were treated with a sub-urethral sling inserted by the transobturator technique.

Level 1 Vaginal Repair - Restoration of the uterosacral ligaments with a polypropylene tape

The aim of level 1 repair is to insert a polypropylene tape in the exact position of the uterosacral ligaments. To get access to the uterosacral ligaments a transverse 4-5 cm long incision was made in the posterior vaginal wall 1,5 cm below cervix or the hysterectomy scar. A Sims speculum opened out the incision. If necessary, the enterocele was opened and ligated with a high purse-string suture. Blunt dissection was performed to the sacrospinous ligaments and insertion of a 2-0 prolene suture through the ligament was achieved using a special purpose designed instrument on both sides.

Bilateral 8 mm perineal skin incisions were made 2 cm lateral and below the external anal sphincter at 4 and 8 o'clock. The IVS-Tunneler was placed into the ischioanal fossa for a distance of 4-5 cm. Under rectal examination control, the instrument was gently turned inwards. The blunt tip was brought through the levator plate, until it reached the transverse incision. A 8 mm Polypropylene tape was threaded into the eye of the stylus and brought into the transverse incision. The procedure was repeated on the other side. Both sacrospinous prolene sutures were brought through the tape to a distance of 4cm. The tape was sutured with no 1 Vicryl to the cervical ring or vaginal vault and also to the remnants of the uterosacral ligaments.

Level 2 Vaginal Bridge Repair

The aim of this procedure was to approximate the laterally displaced rectovaginal fascia towards the midline and to stretch the posterior vaginal wall including rectum. Two parallel full-thickness incisions were made in the posterior vaginal wall, extending from the transverse incision to 1 cm proximal to the introitus. On both sides adherent skin was freed from the rectum laterally to get access to the rectovaginal fascia.

The superficial epithelium was thoroughly destroyed by diathermy and the top of the bridge anchored onto the tape. Two transverse vaginal holding sutures (no 1 PDS) were placed as laterally as possible, one at the level of the uterosacral ligaments and the other at the level of the rectovaginal fascia and left untied. These sutures run subepithelially as a horizontal mattress suture through the rectovaginal fascia, back to the bridge and contralaterally. The purpose of this suture is to approximate the laterally displaced

TABLE 2.

	Incidence before Surgery % in brackets	Incidence after Surgery	Chi ² test p-value
Pelvic Pain	198 (100)	52 (26)	P < 0.001
Urinary Frequency	127 (64)	26 (13)	P < 0.001
Bladder emptying difficulties	68 (34)	32 (16)	P < 0.01
SUI	66 (33)	4 (2)	P < 0.001
ODS	59 (30)	12 (6)	P < 0.001
Urge incontinence	55 (28)	11 (6)	P < 0.001
Residual urine >50ml	44 (22)	20 (10)	P < 0.001

retovaginal fascia towards the midline, and to hold the tissues in place during healing.

Level 3 Vaginal Repair

The aim of this procedure was to restore the integrity of the perineal body as an anchoring point for the backwards and downwards forces. The perineal body was restored with two horizontal mattress sutures inserted subepithelially into both rectovaginal fascias. The distal part of the bridge was included.

The transverse incision was sutured with mattress suture, followed by a continuous layer (no 1 Vicryl). The bridge was buried below the lateral flaps with mattress and continuous sutures in the same way. The coccygeal ends of the tape were cut. Only the skin incision was sutured.

Data acquisition

A prospective audit based on 198 patients with posterior fornix syndrome between January 2009 and December 2012.

Statistics. A 2-tailed Student's t-test was applied (<http://www.socscistatistics.com/tests/studentttest>)

Follow-up and end point measurements

At 12 months follow up a full assessment was made using the self-administered ITS questionnaire⁷, as well as vaginal examination.

Criteria for a positive response

- Pain: A global self-assessed 80% improvement over the baseline symptom at the 12 month visit.
- Nocturia: Reduction from 2 or more episodes per night to one or none.
- Urge incontinence: Zero episodes of wetting prior to arrival at the toilet.
- Fecal incontinence: Zero episodes of soiling prior to arrival at the toilet.
- Obstructed defecation syndrome 'ODS': difficulty in bowel evacuation.

RESULTS

Pelvic pain and apical prolapse were present in 198 patients. The Baden- Walker classification for prolapse was used pre and post-operatively; apical Grade 1: n=15 (7.5%); Grade 2: n=39 (19.5%); Grade 3: n=107 (54%); Grade 4: n=37(19%).

The symptom prevalence is graphically indicated in an iceberg diagram, Figure 2, latent symptoms below the waterline.

Surgery

The mean operating time was 65 minutes (range 41-85 min). There was no serious bleeding. No patient required blood transfusion. Mean hospital stay was 5 days (range 2 – 9 days).

All patients were treated with 600mg Ibuprofen postoperatively every 6 hours, and the following days on demand. Serious complications such as rectal perforation, embolic problems, pyrexia did not occur. One urinary tract infections was observed, within the first week after surgery. This patient was successfully treated with broad-spectrum antibiotics. There were no hematomas, only minor bruising was noted in 5 patients around the incision. In 6 patients a permanent catheter was necessary for 2-5 days, because they were not able to empty their bladder properly. After at least 5 days the micturition was normal in all cases.

A post op follow up including vaginal examination and ultrasound was performed 7 days, 3 month and 12 months after the operation by the senior author (KG).

Of the 198 patients, 196 (99%) patients had normal vaginal anatomy 3 month after the operation and at 12 month review. Two (1%) patients with grade 3 prolapse developed a high grade 2 cystocele. Repair of the cystocele was successful at the 6 month review. No tape erosion was observed.

Symptoms

Symptom prevalence and % cure in brackets for both cohorts combined was: pelvic pain 198 (74%, p<0.001); urinary frequency: 127 (80%, p<0.001); bladder emptying difficulties: 68 (54%, p<0.001); urinary stress incontinence: 66 (95%, p<0.001); nocturia: 63 (79%, p<0.001); obstructive defecation: 59 (80%, p<0.001); urge incontinence: 55 (80%, p<0.001); residual urine >50ml: 44 (55%, p<0.001).

DISCUSSION

Though it is universally acknowledged, that CPP occurs in association with bladder and bowel symptoms^{1,2}, individual dysfunction continues to be treated individually: CPP by referral to a pain specialist; bladder conditions by a urologist; vaginal prolapse by a gynecologist; anorectal problems by a coloproctologist. A recent technique for repair of rectal prolapse⁹ makes no reference to alternative minimally invasive vaginal methods or other associated symptoms, nor does a comprehensive meta-analysis¹⁰.

A review on descending perineal syndrome¹¹ does not address co-existing pain and bladder symptoms nor successful simple recent vaginal methods for repair. A laparoscopic ventral rectopexy makes no mention of the far easier and safer vaginal route, which can reinforce the uterosacral ligaments directly¹².

The Pescatori Iceberg is an important concept, as it visually summarizes the problems with the fragmented assessment by 3 different disciplines and individual symptom by symptom management recommended by Expert Groups. Though we have applied the iceberg concept from the perspective of CPP, figure 2, the conclusion is the same as that of Pescatori et al.: bladder, bowel, pain and other symptoms co-exist with prolapse, albeit as 'latent' submerged symptoms. With the exception of the sensation of urgency/frequency, we found the frequency of an association of bladder and bowel incontinence or evacuation difficulty varying between 30% and 40%, Table1. Yet another characteristic of the iceberg concept is fluidity. For example, we have seen many patients with stress urinary incontinence successfully treated elsewhere with a midurethral sling, only to attend our clinic months or years later complaining of other conditions such as prolapse, urgency, nocturia, chronic pelvic pain, ODS, fecal incontinence. Some symptoms were present previously, some not. The former had emerged from below the iceberg surface to become presenting symptoms.

The inevitable conclusion from figure 1, previous data (9-12) and our data, figure 2, is, that assessment needs to be multicompartamental, as does the treatment. We use the IT-SQ⁷ as it not only addresses all the main symptoms from the three pelviperineal surgical disciplines, it accurately guides the diagnosis and therefore surgery of specific ligament damage.

Our results demonstrating improvement/cure of CPP, bladder and bowel symptoms by re-inforcing just two suspensory ligaments support the application of a different paradigm, namely, the Integral Theory System. The Theory essentially states, that pelvic organ prolapse, CPP, bladder and bowel dysfunction are mainly caused by laxity in 5 suspensory ligaments as a result of altered collagen/elastin¹⁴. It

follows from this, tightening and reinforcing the damaged ligament(s) will restore structure (prolapse) and reverse the cascade of events leading to CPP, bladder and bowel dysfunction.

The data from this paper is but another addition to similar data from many surgeons, who have tested the Integral Theory System paradigm by shortening and reinforcing the cardinal/uterosacral ligament complex (15-25). This method, with a less invasive approach and overnight stay outlines the apparent differences between the holistic Integral System approach to management compared to the often fragmented approach of the individual disciplines towards diagnosis and treatment.

CONCLUSIONS

Our pre-operative data supports the Iceberg concept of Pescatori, that patients usually present with one main symptom, while other symptoms, though present may be latent. We found a 30-40% co-existence of bladder and bowel dysfunctions in patients presenting with chronic pelvic pain. All symptoms improved significantly following repair of two main suspensory ligaments, namely pubourethral and uterosacral. This can be explained by application of the Integral Theory System, which relates ligamentous weakness to pelvic organ prolapse and symptoms.

It can therefore be argued, that the majority of patients presenting to either a urologist, uro/gynaecologist or coloproctologist will have occult symptoms normally associated with a different specialty and these should be accurately determined. Perhaps the time has come to accept the contribution made by the Integral Theory to our understanding of pelvic dysfunction and pain and approach these patients from a global perspective. Where surgery is indicated, it should be the primary objective to perform procedures aimed at addressing all the symptoms and perhaps unify the three specialties into a new discipline of "pelvipiperineology."

Conflicts. None by any authors.

Preparation of paper

Patient assessment, surgery, data collection: Goeschen
Conceptualization, writing, statistics: all authors

REFERENCES

1. Abrams P, Cardozo L, Fall M, Griffiths D, Rosier P, Ulmsten U, van Kerrebroeck P, Victor A, Wein A. The standardisation of terminology of lower urinary tract function: Report from the standardisation sub-committee of the International Continence Society Neurourology and Urodynamics 2002, 21; 2 167-178.
2. Fall M, Baranowski AP, Elneil S, Engeler D, Hughes J, Messelink J, Oberpenning F, de Williams AC. EAU Guidelines on Chronic Pelvic Pain, European Urology 2010, 57; 35-48.
3. Pescatori M, Spyrou M, Pulvirenti d'Urso A. A prospective evaluation of occult disorders in obstructed defecation using the 'iceberg diagram'. *Colorectal Dis.* 2007 Jun; 9 (5): 452-456.
4. Petros PE, Ulmsten U. The posterior fornix syndrome: a multiple symptom complex of pelvic pain and abnormal urinary symptoms deriving from laxity in the posterior fornix. *Scandinavian Journal of Urology and Nephrology* 1993. Vol 27; Supplement No 153; PART IV: 89-93.
5. Abendstein B, Brugger BA, Furtschegger A, Rieger M, Petros PE. Role of the uterosacral ligaments in the causation of rectal intussusception, abnormal bowel emptying, and fecal incontinence - a prospective study. *J. Pelvipiperineology* 2008, 27; 118-121.
6. Petros PE. Severe chronic pelvic pain in women may be caused by ligamentous laxity in the posterior fornix of the vagina. *Aust NZ J Obstet Gynaecol.* 1996, 36: 3: 351-354.
7. Wagenlehner FM, Frohlich O, Bschleipfer T, Weidner W, Perletti G. The Integral Theory System Questionnaire: An anatomically directed questionnaire to determine pelvic floor dysfunctions in women. *World J Urol* 2014; 32 (3): 769-81.
8. Schaer G, Koelbl H, Voigt R, Merz E, Anthuber C, Niemeyer R, Ralph G, Bader W, Fink D, Grischke E. Recommendations of the German Association of Urogynecology on functional sonography of the lower female urinary tract.
9. Gravié JF. Wrap technique for rectal prolapse: video step by step Techniques. *Coloproctology*, August 2015; 19 (8): 475-476.
10. Ramage L, Georgiou P, Tekkis P, Tan E. Is robotic ventral mesh rectopexy better than laparoscopy in the treatment of rectal prolapse and obstructed defecation? A meta-analysis Techniques. *Coloproctology* July 2015; 19 (7): 381-389.
11. Pucciani F. Descending perineum syndrome: new perspectives Techniques. *Coloproctology* August 2015; 19 (8): 443-448.
12. Francheschelli L, Varvaras D, Capuano I, Ciangola CI. Laparoscopic ventral rectopexy using biologic mesh for the treatment of obstructed defaecation syndrome and/or faecal incontinence in patients with internal rectal prolapse: a critical appraisal of the first 100 cases Techniques. *Coloproctology* April 2015; 19 (4): 209-219.
14. Petros PE, Ulmsten U. An Integral Theory of female urinary incontinence. *Acta Obstetrica et Gynecologica Scandinavica*, 1990; 153 (69): 7-31.
15. Neuman M, Lavy Y. Posterior intra-vaginal slingplasty for the treatment of vaginal apex prolapse: Medium-term results of 140 operations with a novel procedure. *Eur J Obstet Gynecol Reprod Biol.* 2008; 140: 230-233.
16. Petros PE. New ambulatory surgical methods using an anatomical classification of urinary dysfunction improve stress, urge, and abnormal emptying. *Int J Urogynecology* 1997; 8 (5): 270-278.
17. Farnsworth BN. Posterior intravaginal slingplasty (infracoccygeal sacropexy) for severe post-hysterectomy vaginal vault prolapse, a preliminary report on efficacy and safety *Int. Urogynecol J.* 2002; 13: 4-8.
18. Sivaslioglu AA, Gelisen O, Dolen I et al. Posterior sling (infracoccygeal sacropexy): an alternative procedure for vaginal vault prolapse. *Aust N Z J Obstet Gynaecol* 2005; 45: 159-160.
19. Abendstein B. Posterior IVS. *Amer J Obstet Gynecol* 2007; 196 (3): 18-19.
20. Sivaslioglu AA, İlhan TT, Aydogmus S, Uzun M, Dolen I. The comparison of the anatomical and symptomatic outcomes of sacrocolpopexy and posterior intravaginal slingoplasty. *Int Urogynecol J* 2011; 22: 1363-1368.
21. Petros P, Richardson P. TFS posterior sling improves overactive bladder, pelvic pain and abnormal emptying, even with minor prolapse. A prospective urodynamic study. *Pelvipiperineology* 2010; 29: 52-55.
22. Petros P, Inoue H. Letter - Pelvic pain may be caused by laxity in the uterosacral ligaments as part of the "Posterior Fornix Syndrome". *ANZJOG* 2013; 53 (3): 325-326.
23. Sekiguchi Y1, Kinjo M, Maeda Y, Kubota Y. Reinforcement of suspensory ligaments under local anesthesia cures pelvic organ prolapse: 12-month results. *Int Urogynecol J* 2013; Dec 7. DOI 10.1007/s00192-013-2281-x [Epub ahead of print].
24. Petros P, Richardson P. Fecal incontinence cure by surgical reinforcement of the pelvic ligaments suggests a connective tissue aetiology. *Pelvipiperineology* 2008; 27: 111-113.
25. Abendstein B, Petros PE, Richardson PA. Ligamentous repair using the Tissue Fixation System confirms a causal link between damaged suspensory ligaments and urinary and fecal incontinence. *Pelvipiperineology* 2008; 27: 114-117.

Correspondence to:

Dr D.M. GOLD MSc., FRACS, FRCS(Gen), FRCS(Eng), MBBS
193 Macquarie St Sydney 2000
Email d.gold@unsw.edu.au Tel +61292372500

Comment

Thank you for asking me to comment on how the iceberg concept evolved. I am very pleased to see that this concept is being successfully applied in a different but related field. The origins of the Iceberg Concept are as follows. We revised all our rectal mucosal prolapse patients with obstructed defecation, those who had undergone an operation. This was published by our group in 2006.

On further analysis, we found that those with anismus had a good outcome in about 30% of cases, whereas those without anismus had good outcomes in about 80% of cases. Those with psychological problems and those without had the same figures.

We hypothesized that the so-called hidden functional or organic lesions might have a pivotal role in determining the outcome of surgery for obstructed defecation.

We made a prospective study, 100 patients, where we searched out a large array of symptoms which we then analysed. We found that all of the 100 patients had at least two occult disorders. We assessed the percentages of those occult disorders, psychological disorders, anismus, rectal hyposensation, enterocele etc. and published the results in the Journal of Colorectal Diseases 2007¹ which has been referenced by the authors Goeschen and Gold.

I agree with the authors that patients tend to present with a singular symptom but many other symptoms are almost invariably present, hidden, like an iceberg, below the surface of the water. These other symptoms must be elicited by specific questioning, as we did in our 2007 work.

REFERENCE

1. Pescatori M, Spyrou M, Pulvirenti d'Urso A. A prospective evaluation of occult disorders in obstructed defecation using the 'iceberg diagram'. *Colorectal Dis.* 2007 Jun; 9 (5): 452-456.

MARIO PESCATORI

Founding Editor Techniques in Coloproctology
ucpclub@virgilio.it