

# The role of the external anal sphincter in the physiology of the pelvic floor

MICHAEL D. LEVIN

*Pediatric Surgical Center, 1st Clinical Hospital, Minsk, Belarus  
State Geriatric Center, Netanya, Israel*

**Abstract. Objective:** To clarify the physiology of the fecal retention and defecation. **Material & Method:** The comparison of the results of my own X-ray studies with published data on the anal manometry, anatomical dissection and 3D topography was produced. **Results:** Long-term retention of feces was due to tonic contraction of the internal anal sphincter (IAS) and the striated muscles of the pelvic floor including levator ani muscle (LAM), puborectalis muscle (PRM) and the external anal sphincter (EAS). The entrance into the rectum of the next fecal portion increases the rectal pressure, which leads to relaxation of the IAS and to mechanical contraction of the PRM and EAS. At this time, liquid feces and gas penetrate into the upper part of the anal canal, where they are identified. Following this, the rectum relaxes, adapting to this volume. The rectal pressure decreases, which causes contraction of the IAS and relaxation of the PRM and EAS. This anorectal inhibitory reflex can be repeated up to several times per hour. During defecation relaxation of the IAS, PRM occur, as well as deep and subcutaneous portions of the EAS. At the same time, a strong rectal peristalsis pushes the stool through the wide open anal canal. The upper part of the anal canal is opened as a result of the contraction of the LAM. The contraction of the superficial portion of the EAS leads to the opening of the distal part of the anal canal. The wide opening of the anal canal greatly reduces resistance to the stool promotion.

**Conclusion:** All portions of the EAS have different points of attachment and, therefore, have different functions. In fact, each of them is the separate sphincter.

**Abbreviations:** IAS – internal anal sphincter; EAS – external anal sphincter; PRM – puborectalis muscle; IAP– intra-abdominal pressure; LAM – levator ani muscle; TP-1 – threshold pressure of the first order, provoking of the anorectal inhibitory reflex; TP-2 - the threshold pressure of the second order, provoking the need of defecation; TP-3 - the threshold pressure of the third order, causing of the defecation reflex.

**Keywords:** Anorectal physiology; Defecation; Fecal retention; Hypothesis; Rectum; Anal canal

## INTRODUCTION

An adequate understanding of anorectal physiology is necessary for the correct diagnosis of pathological processes and the respective correction of them<sup>1</sup>. To date, a large quantity of researches have accumulated in this field, but due to the fact that the authors of different techniques (anatomical, manometer, X-ray, CT, MRI and 3D-topography) do not account for the results obtained using of other techniques, there are significant discrepancies in the description of the physiology of the fecal retention and defecation.

The purpose of this research is to compare different methods to create the acceptable representation of the anatomy and physiology of the anorectal region, which does not contradict reliable scientific evidences. In order not to stray from the path of truth, it is very important to keep in mind the following axioms. 1) Every muscle has a very simple function: when it contracts, its length is shortened. Therefore, it is important to know the two places of the muscle attachment to determine of its function. This implies that the muscle fibers with various attachment places have different functions and therefore they are the different sphincters. 2) Muscle fibers during contraction use ATP, and it should relax to restore capacity to contraction. 3) There are no voids in the tissues of the pelvic floor. If the anal canal during defecation always equally and widely opened, creating a channel in the form cylinder for passage of feces irrespective of their consistency (liquid, solid or soft), it means that tissues have changed configuration<sup>2</sup>. Only muscles can some effect this. If this was only due to changes in the relationship between the peristaltic pressure of the rectum and the tone of the anal canal, the liquid feces (contrast material) would pass through the narrow anal canal. 4) To avoid confusion, it is necessary to adhere to the recognized anatomical designations. Thus, for example, it occurs when Wu called the anal canal of the rectum, and do

not divide in the description of the deep and superficial portions of the external anal sphincter (EAS)<sup>3, 5</sup>. At each stage of scientific knowledge there is the gold standard, to which compare the results obtained by other methods. Wu and co-workers in the 3D-topography found no septum between the puborectalis and pubococcygeus, which separate these muscles from each other. However, this septum, is described in almost all textbooks<sup>3</sup>. Hence the anatomical dissection, rather than 3D-topography is taken as the gold standard. Applying the most modern equipment, the authors exaggerate its capabilities, leading to inappropriate conclusions.

## ANALYSIS OF THE LITERATURE

### *Fecal retention*

In healthy adults the length of the anal canal is approximately 4 cm<sup>4</sup>. This is the high pressure area compared with the pressure in the rectum. It is in constant contraction, with the exception of short-term opening during a bowel movement. At rest the tonic state of the internal anal sphincter (EAS) provides 45% of the total pressure in the anal canal<sup>4</sup>. The IAS is composed of smooth muscle fibers and is the thickened continuation of circular layer of the rectum. The caudal end of the IAS is located at a distance of 8-10 mm from the anal dimple<sup>5</sup>. It is absent in the contraction zone of the subcutaneous portion of the EAS. Thus, the length of the BAC in adults is about 3 cm. Outside the IAS is located a longitudinal smooth muscle layer. The puborectalis muscle (PRM), the deep and superficial portions of the EAS are located outside of longitudinal smooth muscle layer. Based on anatomical studies it was found that the striated muscle of the EAS consists of 3 parts: a subcutaneous, superficial and deep (Figure 1, B)<sup>6,7</sup>. Subcutaneous part is a true circular sphincter. It is separated from the superficial portion of

the fibrous tissue<sup>3</sup>. The superficial portion of the EAS has a U-shape. Posteriorly it is attached to the coccyx through the rising up anococcygeal ligament<sup>8</sup>, and then it covers the back and sides of the anal canal and attached (ends) to the perineal body at a considerable distance from the pubis (Fig. 1A).

The deep part of the EAS has a small volume and is located caudal to the PRM. It is located so close to the PRM that some authors consider it to be part of the PRM<sup>3,5</sup>.

Here is how is described a 3-D ultrasound picture of the anal canal - "The IAS is seen as a hypoechoic (dark) circular ring in these images...Surrounded by the IAS is a relatively hyperechoic ring-shaped structure of the EAS<sup>5</sup>. Is it that this study cannot be considered a gold standard, if anatomically (histologically) is well established that between the IAS and EAS is a longitudinal layer of smooth muscle? This example shows that modern methods of research that fascinated researchers to dissect the body without damaging it, are inferior in accuracy to anatomical dissection.

All baseline anal pressure profiles showed a peak pressure in the range of 70-80 mmHg at a level of 1.6 cm from the anal verge, which corresponds to the level of the IAS. In addition, there was a hump in the posterior pressure from 2.4 cm to 4 cm corresponding to the PRM<sup>9</sup>.

In order to evaluate these muscles in action, the researchers provoked the rectoanal inhibitory reflex, which is caused by stretching of the rectal walls. This reflex is described manometrically by the relaxation pressure or loss of anal canal pressure during rectal balloon distention. During high definition manometry the peak of the residual pressure is at 0.9 cm in the anterior and posterior vectors and an additional hump in the posterior only vector ranging from 2.4 to 4.4 cm, corresponding to the EAS and PRM respectively<sup>9</sup>. The peak pressure of the IAS is seen at a level of 1.6 cm from the anal verge, which corresponds to the peak relaxation pressure. The EAS is the only muscular structure located from 0.5 cm to 1 cm from anal verge<sup>9</sup>.

As shown earlier, the penetration of barium into the upper part of the anal canal in front of the tip of enema during barium enema is accompanied by a decrease in anal pressure and when the barium disappears from the anal canal, the pressure recovers to basal level<sup>2</sup>.

Combining of the anatomical studies with radiographic and manometric data allows mapping the sphincters apparatus during provocation of the rectoanal inhibitory reflex (Fig. 1). Stretching of the rectal wall causes reflex relaxation of the IAS, whereby the pressure at the top of the anal canal is reduced and the liquid (barium) penetrates into the upper part of the anal canal. Simultaneously, the PRM contraction presses the posterior anal wall to the tip enema<sup>2</sup>. The upper part of the anal canal is shifted forward, causing a decrease of the anorectal angle. The manometric and radiographic indicators of the impact of the PRM coincide with the place and width of coverage of the anal canal (about 1.6 cm). The PRM function corresponds to the anatomical location of the loop and its attachment to the pubic bone on either side of the symphysis pubis. It follows that during the anorectal reflex the PRM not completely covers the lumen of the anal canal. A gas or liquid feces pass into the upper part of the anal canal but a formed feces remains in the rectum (Fig. 1, A).

Despite the fact that the relaxation pressure is determined significantly caudal to the PRM, i.e. virtually at the level of the subcutaneous part of the EAS (1.2 cm from the anal pit), the contrast agent does not penetrate below the PRM border (2.4 cm from the anal verge). This can be explained by the contraction of the circular muscles located caudal to

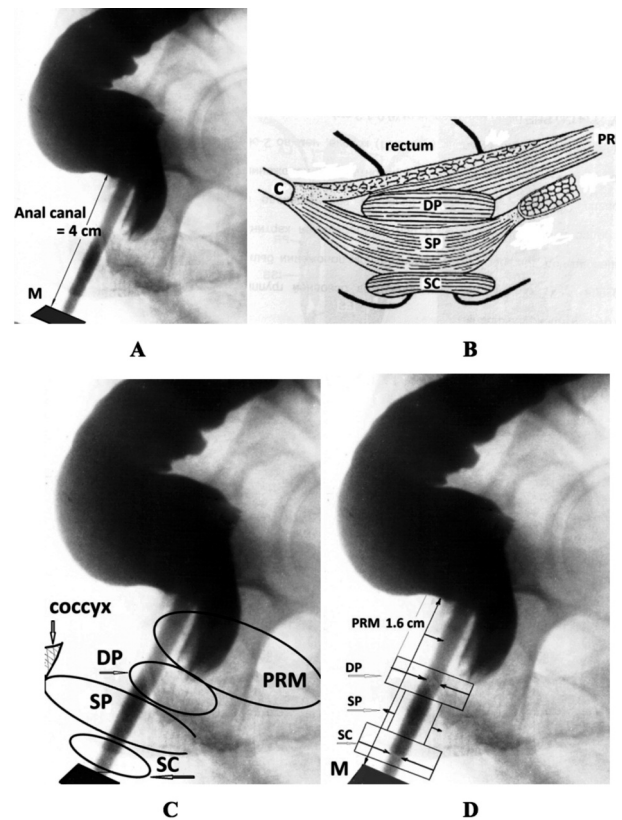


Figure 1. – The combining of the manometric study, anatomical data and X-ray imaging of the anorectal area (lateral view).

**A.** The contrast marker (M) is located near the anus. The barium was introduced into the rectum, and it is also defined in the tip of the enema. The distance from the rectum to the marker behind the tip is equal to the length of the anal canal (4 cm). The reflex relaxation of the IAS occurred in response to the rectal wall stretching. The barium has penetrated into the upper part of the anal canal in front of the tip only, because the posterior wall at this level is pressed against the tip by the contracted PRM.

**B.** Scheme of the muscle anatomy around the anal canal: PRM – puborectalis muscle; DP - deep portion of EAS; SP- superficial portion of the EAS; SC - subcutaneous portion of the EAS. From article Raizada V., Mittal R.K.<sup>7</sup>.

**C.** As result of the IAS relaxation and the decreasing pressure at this level, the liquid contrast agent penetrates into the upper part of the anal canal in front of the enema tip. The barium does not penetrate caudal level of the PRM, as a result of the circular muscle contraction. The converging folds are seen over the contraction of the deep portion of the EAS.

**D.** At the level of the superficial portion of the EAS the peak of relaxation pressure (1.7 cm from the anal dimple) is defined. This U-shaped muscle is attached to the coccyx. During contraction it pulls back and to sides the wall of the posterior semicircular of the IAS , creating a negative pressure inside of anal canal at this level.

the PRM. The location and course of its muscle fibers correspond to the deep portion of the EAS. Although it contracts simultaneously with the PRM, the circular course of the muscle fibers and function are different from the PRM. Consequently, the deep portion of the EAS is a self-sphincter.

The area of the anal canal relaxation with a peak relaxation pressure between the deep and subcutaneous portions of the EAS is defined. Its location corresponds to the superficial portion of the EAS. It has a U-shaped open anteriorly. Its rear part is attached to the coccyx through the anococcygeal ligament. It adjoins the rear semicircle of the anal canal. All sources only pay attention to the fact that its two branches join the perineal body. Meanwhile, it is obvious

that superficial portion of the EAS surrounds the anal canal back and sides and adjoin to the longitudinal layer. During contraction it pulls the lower part of the anal canal back and to sides, and stretches fan-like to the anal canal wall, which may explain the increase in peak relaxation pressure. Subcutaneous portion of the EAS is separated from the superficial portion by the fibrous layer<sup>3</sup>. It is a typical circular sphincter. All part of EAS, together with PRM contract during the anorectal inhibitory reflex, but as a result of various shapes and places of attachment they perform different functions.

**Defecation**

Paired levator ani muscles (LAM) is the name of a group of muscles that form the pelvic floor. The PRM is one of them. It is hardly separated from other muscles during anatomical study. On this basis, some authors still believe that all these muscles function the same way. Since it is known that the PRM relaxes during defecation, it is assumed that the rest of the pelvic floor muscles also relax during defecation<sup>10,11,12</sup>. According to them, the tension causes the reflex relaxation of the PRM, IAS and EAS, which leads to the “pelvic floor descending” and to disappearance of the anorectal angle<sup>12</sup>. The term “descending perineum” was first proposed by Parks et al. in describing of the wide opening of the anal canal during defecography<sup>13</sup>. Figure 2 shows two lateral radiographs of the anorectal area in the state of barium retention (A) and during defecation (B), which clearly show the broad opening of the anal canal up to the width of the rectum due to the displacement of the posterior anal canal wall to the spine (Fig. 2).

Skeletal muscles are capable of two types contraction: tonic and mechanical. Tonic prolonged contraction of the LAM, PRM and EAS explained by the postural reflex<sup>13,14</sup>. Each nervous axon has a connection to the muscle fibers scattered throughout the muscle. Therefore, even a small amount of the contracted muscle fibers results in a contraction of the whole muscle. The muscle tone is dependent on the number of fibers participating in the contraction, i.e.

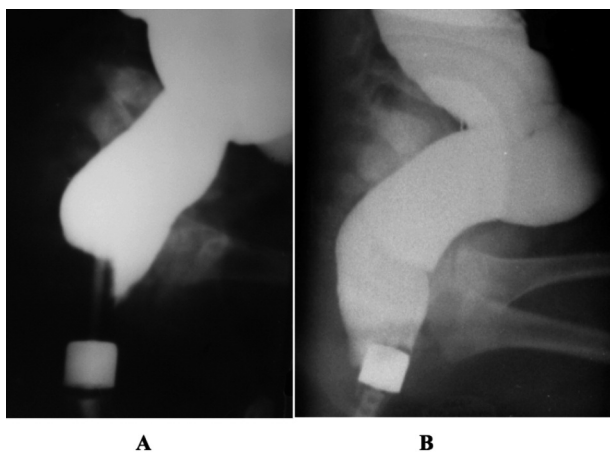


Figure 2. – The lateral radiographs of children first year of life during barium enema were made. Metal marker 1.6 cm diameter is located near the anus.  
**A.** Barium penetrated into the upper part of the anal canal in front of the enema tip as a result of the IAS relaxation. The posterior wall at this level is pressed to the enema tip by the contracted PRM. The distal part of the anal canal is blocked by the contracted PRM (anorectal inhibitory reflex).  
**B.** During defecation the posterior wall of the anal canal sharply moved backwards. Diameter of the anal canal corresponds to the diameter of the rectum. The disappearance of the anorectal angle is the result of the opening of the anal canal.

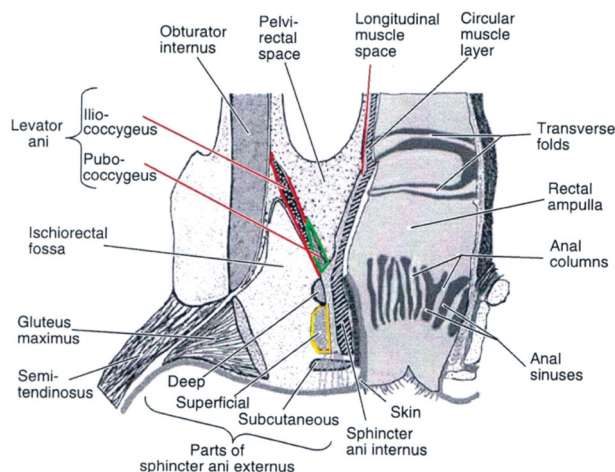


Figure 3. – The scheme of coronary section one of the pelvic sides at the level anal canal. From the article A.E.Bharucha<sup>17</sup>.

from the percentage of axons activating muscle contraction. The prolonged, tonic contraction is due to the continuous replacement of the axons activating the different groups of muscle fibers. At different time the different groups of the muscles fibers are contracted. During the contraction of one group, other groups of fibers restore ability to contract<sup>2, 15</sup>.

In mechanical contraction all fibers are involved, resulting in a significant shortening of the muscle. However the duration of the muscle contraction is severely limited, typically less than one minute. LAM function (pubococcygeus, iliococcygeus) during their contraction can be judged by their attachment points. It is known that these muscles on the periphery are attached to the pubic and ischial bones, and arcus tendinosus, which is a thickened part of the obturator fascia. They surround the anal canal and are closely connected to the deep portion of the EAS side and the rear wall of the anal canal<sup>16,17</sup>. Some authors consider that these muscles are attached to the longitudinal layer of the anal canal. The longitudinal layer of the rectum, crossing anorectal compound is mixed with the fibers of the LAM<sup>18</sup>. In recent years the prevailing opinion is that defecation is accompanied by the LAM contraction, which leads to the disappearance of the anorectal angle and to the descending perineum<sup>2,4,5,9,11</sup>. These two characteristics are not related to description of physiological processes. The disappearance of the anorectal angle is a X-ray symptom. That in the lateral projection is defined as the straightening of the anorectal angle, in three-dimensional image is a wide opening of the anal canal as a result of the movement of its posterior and lateral walls to the place attachment of the peripheral ends of the LAM. The definition “descending perineum” is misleading, since it is known that during defecation pelvic floor muscles do not descend, but are raised<sup>7</sup>. The LAM’s have a funnel shape. In the upper part, they are oriented horizontally. Dropping down they are connected to the anal canal in front at an angle of 30 ° to the horizontal line, and on the sides - 45 ° (Figure 3)<sup>3</sup>. Since the upper end of the LAM is fixed to the pelvis, during its contraction the muscles pull the lower end and posterolateral wall of the anal canal - up and back to the pelvis. The impression about the descending perineum is the result of the opening of the anal canal (Fig. 4).

The LAM (iliococcygeus and pubococcygeus) descend to the anal canal at an angle of 45° and to the top of the longitudinal layer of the anal canal are attached.

In recent years, most studies indicate that the main function of the LAM is the opening of the anal canal during



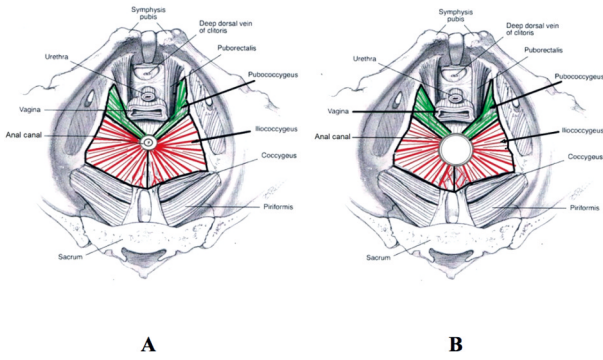


Figure 4. – Scheme cross-section at the level of the deep portion of the EAS. A scheme from the article of A.E.Bharucha was used<sup>17</sup>.

defecation<sup>9,17,19-21</sup>. Scheme cross-section at the level of the deep portion of the EAS at the time of the fecal retention and bowel movements is shown in Figure 4.

Li and Guo, using CT defecography showed that “...the levator ani muscle does not lift the anus; its main function is to open the genital hiatus and the anus during defecation”<sup>19</sup>. Palit and co-authors came to the conclusion that plateau levators (which are connected to the posterior surface of the rectum) and longitudinal layer of the anal canal are contracted at the same time during defecation<sup>8,11</sup>. Petros et al. suggest that three striated muscle vectors open the anorectal angle prior to defecation, causing the anorectal luminal diameter to increase to approximately twice its resting size. If the effective diameter of the anus is doubled during defecation, the frictional resistance is reduced by a factor of 8<sup>20,21</sup>.

The combination of X-ray pictures with the anatomical location of the muscles shows that the LAM may stretch the back and side walls only at the upper part of the anal canal with an additional force vector upward. In order to stretch the lower part of the anal canal additional force must be applied, which would have balanced the force vector directed upwards. We believe this role can perform only superficial portion of the EAS, given its location and points attachment. It has the shape of «U» and located below the LAM. Its posterior end is attached to the coccyx, and the sleeves tightly cover the lower part of the anal canal behind and on the sides, and their ends are attached to the center of the perineal body. During contraction of the superficial portion of the EAS the posterior and side walls of the anal canal are moving fan-like back and sides, counterbalancing the vector force of the LAM directed upwards. Function diagrams of the anorectal zone during the fecal retention and defecation are shown in Figure 5.

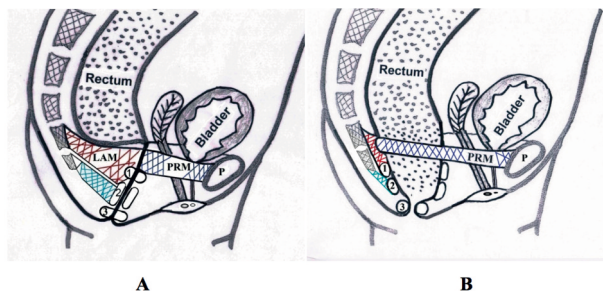


Figure 5. – Function diagrams anorectal area while fecal retention (A) and defecation (B).

LAM - red; PRM - blue; Superficial portion of the EAS - green; P - pubic bone; 1 - deep portion of EAS; 2 – superficial portion; 3 – subcutaneous portion of EAS.

## CONCLUSION

At rest, the IAS and all striated muscles of the pelvic floor are in a state of tonic contraction. They help to support the pelvic organs and participate in the continuous retention of feces. The pressure in an empty rectum is equal to the intra-abdominal pressure (IAP). During long-term fecal retention, while entering into the rectum of a certain volume of feces, there is a periodic increase in rectal pressure above the IAP. This pressure we called the threshold pressure of the first order (PD-1)<sup>2</sup>. It causes a reflex relaxation of the IAS and contraction of the EAS and PRM (anorectal inhibitory reflex). The PRM pulls forward the upper part of the anal canal. This reduces the anorectal angle. In front, inside the PRM loop the anal pressure decreases as a result of the IAS relaxation.

Between the rectum and anal canal there is a narrow opening through which the gas and liquid feces can penetrate into the upper part of the anal canal. In the mucosa at this level there are sensors that allow to distinguish the liquid from gas. In the presence of gas is enough to strain the abdominal wall to increase rectal pressure and expel gas through the lower part of the closed anal canal. Passing under pressure through a narrow channel gas causes a characteristic sound. When the liquid feces penetrate into the upper part of the anal canal the tone of the EAS increases, which leads to a contraction of the IAS and crowding out of the fluid from the anal canal into the rectum. During anorectal inhibitory reflex the formed stool remain in the rectum due to acute anorectal angle and the narrow holes between the rectum and anal canal. After a few seconds<sup>5-12</sup> the rectum adapts to the new volume of stool and relaxes. The rectal pressure drops up to IAP, resulting in the contraction of the IAS and relaxation of the PRM and EAS. After entering into the rectum of another portion of feces this picture (anorectal inhibitory reflex) is repeated. According to Wu this picture can be observed up to 7 times per hour<sup>3</sup>.

During the anorectal inhibitory reflex a gas and liquid does not penetrate into the lower part of the anal canal as result of circular contraction of the deep portion of the EAS. At the same time the contraction of the superficial portion of the EAS pulls the lower part of the anal canal backward, helping to reduce anorectal angle and increases relaxation pressure in the anal canal at this level, which also contribute to the retention of feces. The contraction of the circular fibers of the subcutaneous portions of the EAS increases the fecal retention.

When the volume of stool in the rectum reaches a certain value the rectal pressure rises from the TP-1 to the threshold pressure of the second order (PD-2), in which a need for a bowel movement appears.

If this need does not coincide with the possibility of its implementation, the rectum continues to relax, to adapt to the increasing volume of feces, but the TP-2 periodically reminds of necessity of bowel evacuation. When the need for a bowel movement coincides with the possibility of its implementation, a straining of the abdominal wall allows to increase the rectal pressure from TP-2 to TP-3. At the rectal pressure PD-3 the reflex defecation takes place: a strong peristaltic wave of the rectum expels stool through the open anal canal. It is accompanied by relaxation of the IAS, PRM, as well as the deep and subcutaneous portions of the EAS. The LAM (pubococcygeus and iliococcygeus), as well as the superficial portion of the EAS are contracted, creating a channel for facilitating the passage of stool. Circular fiber of the subcutaneous portion of the EAS located outside the IAS relax during defecation (but do not stretched), skipping the formed stool. Gas and liquid feces leave outside by a narrow stream, and soft stool passes in form a ribbon, the width of which is proportional to the density of feces.

Any of the pressure levels depend not only on the volume of feces, but also from the tone of the rectum. For example, with diarrhea, the rectal tone is higher than usual, and even small amount of feces causes a pressure rise from TP-2 up to TP-3.

Based on the combination of the results of anatomical studies, manometric data, and X-ray picture in the different phases of stool retention and during defecation, we came to the conclusion that the PRM and each of the three portions of the EAS have different functions and are actually different sphincters.

## REFERENCES

1. Van Koughnett JA, da Silva G. Anorectal physiology and testing. *Gastroenterol Clin North Am.* 2013; 42 (4): 713-28. doi: 10.1016/j.gtc.2013.08.001. Epub 2013 Oct 10.
2. Levin MD, Troyan VV. Anatomy and physiology of anorectal zone. Hypothesis of continence and defecation. *Novosti Chirurgii (Vitebsk)* 2009; 2: 105-18.
3. Wu Y, Dabhoiwala NF, Hagoort J et al. Correction: 3D Topography of the Young Adult Anal Sphincter Complex Reconstructed from Undeformed Serial Anatomical Sections. *PLoS One.* 2015 Oct 9; 10 (10): e0140736. doi: 10.1371/journal.pone.0140736. eCollection 2015.
4. Bharucha AE, Rao SS. An update on anorectal disorders for gastroenterologists. *Gastroenterology.* 2014; 146 (1): 37-45.e2. doi: 10.1053/j.gastro.2013.10.062. Epub 2013 Nov 6.
5. Mittal RK, Bhargava V, Sheean G et al. Purse-string morphology of external anal sphincter revealed by novel imaging techniques. *Am J Physiol Gastrointest Liver Physiol.* 2014; 306 (6): G505-14. doi: 10.1152/ajpgi.00338.2013.
6. Shafik A. A new concept of the anatomy of the anal sphincter mechanism and the physiology of defecation. The external anal sphincter: a triple-loop system. *Invest Urol* 1975; 12: 412-419. [PubMed: 1112669].
7. Raizada V, Mittal RK. Pelvic floor anatomy and applied physiology. *Gastroenterol Clin North Am.* 2008 Sep; 37 (3): 493-509, vii. doi: 10.1016/j.gtc.2008.06.003.
8. Jin ZW, Hata E, Jin Y et al. The anococcygeal ligaments: Cadaveric study with application to our understanding of incontinence in the elderly. *Clin Anat.* 2015; 28 (8): 1039-47. doi: 10.1002/ca.22629. Epub 2015 Oct 13.
9. Cheeney G, Nguyen M, Valestin J, Rao SS. Topographic and manometric characterization of the recto-anal inhibitory reflex. *Neurogastroenterol Motil.* 2012; 24 (3): e147-54. doi: 10.1111/j.1365-2982.2011.01857.x. Epub 2012 Jan 11.
10. MacCrea GL, Miaskowski C, Stotts N et al. Pathophysiology of constipation in older adult. *World J Gastroenterol* 2008; 14 (17): 2631-8.
11. Palit S, Lunniss PJ, Scott SM. The physiology of human defecation. *Dig Dis Sci.* 2012; 57 (6): 1445-64. doi: 10.1007/s10620-012-2071-1. Epub 2012 Feb 26
12. Shelton AA<sup>1</sup>, Welton nML. The pelvic floor health and disease. *West J Med.* 1997; 167 (2): 90-8.
13. Parks AG, Porter NH, Hardcastle J. The syndrome of the descending perineum. *Proc R Soc Med.* 1966; 59 (6): 477-82.
14. Porter NH. A physiological study of the pelvic floor in rectal prolapse. *Ann R Coll Surg Engl.* 1962; 31: 379-404.
15. Histology. By edition A.W. Ham and D.H. Cormack Eighth Edition. 1979. JB. Lippincott Company.
16. Coloproctology and pelvic floor. Pathophysiology and management. MM. Henry, M. Swash. Butterworths. 1985.-Moscow, Medicina 1988. p. 155-156.
17. Bharucha AE. Pelvic floor: anatomy and function. *Neurogastroenterol Motil.* 2006; 18, 507-519.
18. Courtney H. Anatomy of the pelvic diaphragm and anorectal musculature as related to sphincter preservation in anorectal surgery. *Am J Surg.* 1950; 79 (1): 155-73, illust.
19. Li D, Guo M. Morphology of the levator ani muscle. *Dis Colon Rectum.* 2007; 50 (11): 1831-9.
20. Petros P, Swash M, Bush M, Fernandez M et al. Defecation 1: Testing a hypothesis for pelvic striated muscle contraction to open the anorectum. *Tech Coloproctol.* 2012; 16 (6): 437-43.
21. Bush M, Petros P, Swash M, Fernandez M, Gunnemann A. Defecation 2: Internal anorectal resistance is a critical factor in defecatory disorders. *Tech Coloproctol.* 2012; 16 (6): 445-50. doi: 10.1007/s10151-012-0860-3. Epub 2012 Jul 24.

### Correspondence to:

Levin M, MD, PhD, DSc, radiologist.  
Amnonve-Tamar, 1/2, Netanya, 42202, Israel.  
Tel: 972-53-8281393 Fax: 972-9-8630151.  
[nivel70@hotmail.com](mailto:nivel70@hotmail.com)  
<http://orcid.org/0000-0001-7830-1944>  
<http://www.anorectalmalformations.com>

## Editorial commentary

The great Spanish anatomist /urologist Salvador Gil-Vernet (1892-1987), stated that it was not sufficient to describe an anatomical structure. He said that an answer was required to the question of “*what is it for*”<sup>1</sup>.

Even in the highest rating journals, the focus today seems concentrated on RCTs and Metanalyses. These are worthy but unoriginal endeavours. Innovative science asks the question “What is it for?”, an important question, for without original thought, there are no RCTs and no Metanalyses. Throughout its 10 year history, Pelviperrineology Journal has gone to great lengths to promote original thought. This paper by Michael Levin is one such example.

Michael Levin is a radiologist who goes beyond reading of images to ask, “what is it for”. A feature of Michael’s research method is the use of classic deductive logic to test his hypotheses for truth or falsity.

His reasoning on the role of the 3 external anal sphincters is a fine example of deductive logic. His emphasis on the role of internal anal sphincter (IAS) in continence control does not fit with my experience as a surgeon which considers the role of IAS is to seal not close the anus. I refer interested readers to the 2008 Musculoelastic Theory 2. Study No1 found that directional muscle forces activate anorectal continence and defecation in the female. Study No5 found only 39% of 80 fecally incontinent patients had even partial IAS damage. Four separate surgical studies (Studies 9-12), demonstrated fecal incontinence and obstructive defecation were (variously) cured by repair of incompetent pubourethral and uterosacral ligaments<sup>2</sup>.

## REFERENCES

1. Gil-Vernet JM, Salvador Gil-Vernet, a pioneer in Urological Anatomy, Chapter in De Historia Urologiae Europaeae Vol 24 2017, Eds. Van Kerrebroeck P, Schultheiss D, EAU History Office European Association of Urology, 13-43.
2. Petros PE & Swash M A Musculoelastic Theory of Anorectal Function and Dysfunction in the Female. *J Pelviperrineology*, 2008, 89-121.

PETER PETROS  
Editor Pelviperrineology  
[pp@kvinno.com](mailto:pp@kvinno.com)