

A review of the Integral Theory of Pelvic Organ Prolapse and proposed concept of repair:

Part 1 - Structural components and damage

DARREN M. GOLD¹, DAVID ENDE²

¹ Colorectal Surgeon, Senior Lecturer in Surgery, St Vincent's Clinical School, UNSW, Sydney, Australia

² Urologist, St Vincents Clinic, Senior Lecturer, Notre Dame Medical School, Sydney, Australia

Abstract: Aim: To explain the structural basis of the Integral Theory, how pelvic organ support requires 5 competent ligaments, uterosacral (USL), cardinal (CL) arcus tendineus fascia pelvis (ATFP), pubourethral (PUL) and perineal body (PB) and how damage to these ligaments may cause pelvic organ prolapse 'POP' (cystocele, uterine prolapse, rectocele), bowel, bladder and pain symptoms. **Biomechanics:** The ligaments attach the organs to the skeleton from above. Pelvic muscles stretch them from below. Ligaments are strong and relatively inelastic, breaking strain 300 mg/mm²; vagina is weak and elastic 60 mg/mm². **Pathogenesis:** Dislocation/stretching of vagina and CL from the cervix are principal causes of cystocele; stretching of USL & CL cause uterine prolapse. Dislocation/stretching of vagina from USL and PB may cause rectocele as may separation of the PB bodies. **Conclusions:** The pelvis functions like a suspension bridge. Organ support is derived by adequately tensioned ligaments from above and muscle contraction from below. If the ligaments are damaged they need to be reinforced in the position and along the axis of the natural ligament. Shortening and strengthening the ligaments also restores the directional muscle forces which contract against these ligaments to restore organ support from below.

Keywords: POP; Ligaments; Pelvic muscles; ATFP; Cardinal ligament; Uterosacral; Perineal body.

INTRODUCTION

This is the first of four related papers seeking to review and precis a proposed concept of repair of pelvic organ prolapse and the Integral Theory System on which it is based.

The Integral Theory¹, states pelvic organ prolapse and bladder and bowel dysfunction and some types of pelvic pain, mainly derive, for different reasons, from laxity in the vagina or its supporting ligaments, a result of altered collagen/elastin.

The aim of Part 1 is to explain the anatomical basis of the Integral Theory, how 5 competent ligaments, uterosacral (USL) cardinal (CL) arcus tendineus fascia pelvis (ATFP) pubourethral (PUL) and perineal body (PB) are key to organ support and how laxity in these structures may cause pelvic organ prolapse 'POP' and symptoms.

THE BIOMECHANICS OF PELVIC ORGAN PROLAPSE (POP) SURGERY

The following are important aspects of the Integral Theory^{1,2}. The ligaments attach the organs, vagina, bladder, rectum to the skeleton from above (Figures 1, 2). The pelvic muscles stretch them from below (Figure 3). The ligaments are strong and inelastic. They provide the principal strength for organ suspension. Because the organs and the vagina need to expand and contract, they contain significant quantities of elastin, but have far less structural strength. Estimated breaking strain of ligaments is approximately 300 mg/mm² and vagina approximately 60 mg/mm², Yamada 1973³. Collagen I provides structural strength and elastin stretchability. Both weaken with age, especially after the menopause. Elasticity of the vagina is fundamental to its function during organ closure, evacuation, intercourse and it is a low energy mechanism for closure of the urethra.

From these simple biomechanics, two surgical principles follow which need to be observed during pelvic reconstruction.

1. It is the ligaments which provide suspensory strength, so they must be reinforced in any surgical reconstruction, along the length of the ligament and in its anatomical axis.

2. The vagina has little structural strength. It functions as an elastic organ. Its elasticity must be preserved. Vaginal

excision will only add less elastic scar tissue and reduce the quantity of collagen and elastin available for normal vaginal function.

SURGICAL ANATOMY OF PELVIC ORGAN PROLAPSE

The ligaments. The organs are suspended to the pelvic side wall skeleton by 5 main ligaments, uterosacral (USL) cardinal (CL) arcus tendineus fascia pelvis (ATFP) pubourethral (PUL) from above, Fig1 and perineal body (PB) from below (Figure 2)⁴. The ligaments and the structural layer of vagina known as pubocervical (PCF) and rectovaginal (RVF) fascia are composed of collagen, elastin, smooth muscle, blood vessels and nerves, so they are contractile (1).

Ligaments attach the organs to the skeleton. ATFP ligaments attach to the pubic symphysis just above PUL, to

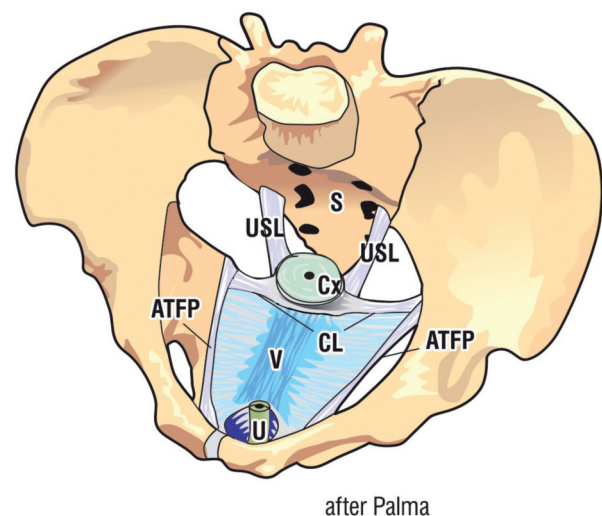


Figure 1. – Anterior vaginal attachments to skeleton. The vagina is suspended like a trampoline membrane between the Arcus Tendineus Fascia Pelvis (ATFP) ligaments laterally, proximally to the anterior part of the cervical ring (CX) and cardinal ligament (CL) and distally to the lower half of urethra (U) via the pubourethral ligament which inserts into the middle part of the urethra. S=sacrum.

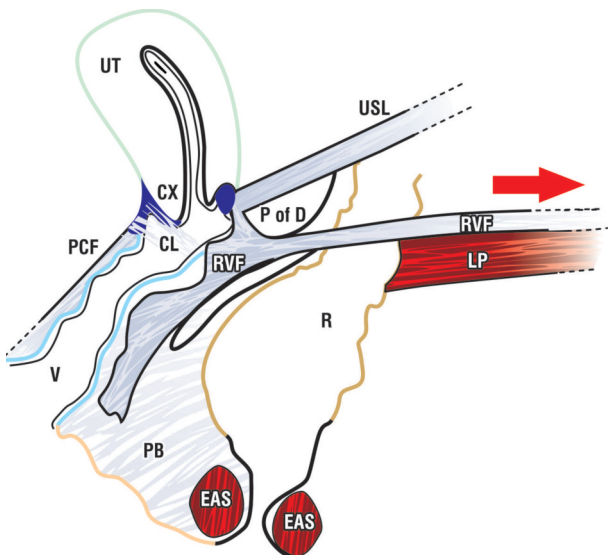


Figure 2. – The uterosacral ligaments (USL) attach uterus to sacrum, to the lateral rectal walls, cervical ring (CX), cardinal ligament (CL), fascial layer of posterior vaginal wall (rectovaginal fascia ‘RVF’) and perineal body (PB) in its distal 50%. Note the organ space between posterior vaginal wall and rectum. It needs to be preserved to allow independent movement of vagina over rectum especially during intercourse and defaecation.

the paracolpium of the lateral vaginal walls and to the ischial spines (Figure 1).

Cardinal ligaments attach to lateral side wall of the skeleton, anterior cervical ring, the pubocervical fascial layer of anterior vaginal as it attaches to the cervical ring, lateral border of cervix and USL (Figure 1).

Uterosacral ligaments attach to sacrum, rectal walls laterally and cervix anteriorly (Figure 1).

Perineal body (PB) attaches to distal rectum, distal vagina and to the descending ramus via the deep transversus perineus ligament (Figure 3).

Pubourethral ligaments attach to the mid urethra, anterior portion of pubococcygeus muscle (pubovaginalis muscle) and to the lower border of the pubic symphysis; Figure 4.

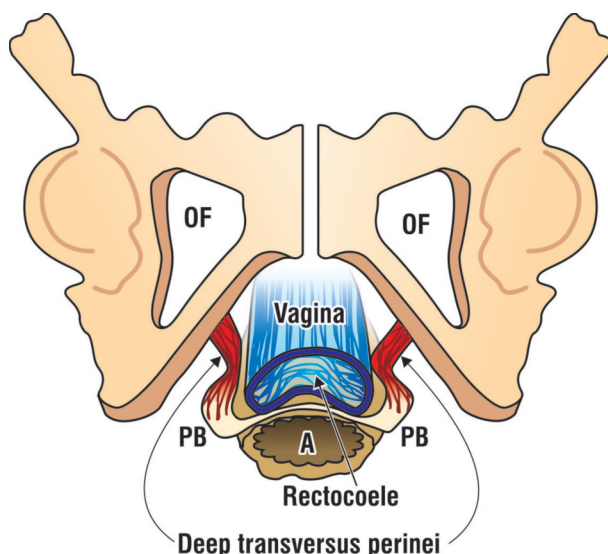


Figure 3. – Ligament attachment of perineal bodies (PB) behind descending ramus. The PBs have been separated during childbirth, causing stretching of the central tendon (not shown) allowing the rectum to protrude into the vagina as a rectocele. Note attachment of PBs to the descending ramus by the deep transverse perinei ligaments.

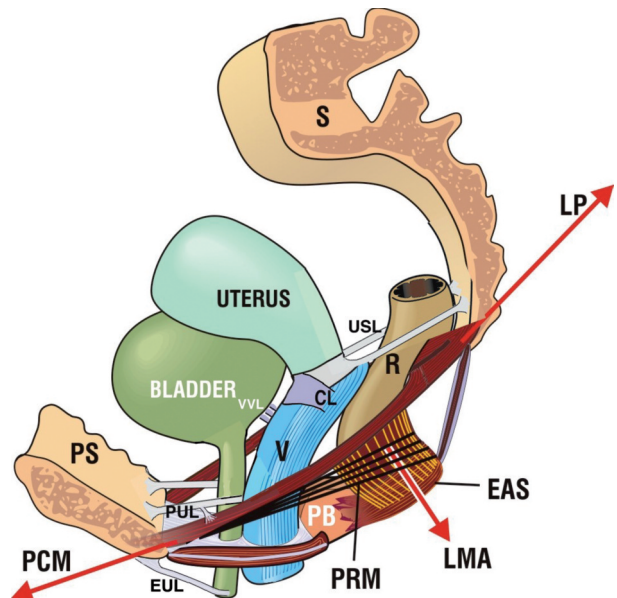


Figure 4. – The principal muscles and ligaments of the pelvic floor.

The 3 directional muscle forces (arrows) contract against PUL anteriorly and (CL/USL) posteriorly.

Forward contracting m. pubococcygeus (PCM); m. puborectalis (PRM).

Backward contracting m. levator plate (LP); conjoint longitudinal muscle (LMA). Ligament labelling as in fig1. LP inserts into the posterior wall of rectum; LMA connects LP to the external anal sphincter and contracts downwards.

External urethral ligament (EUL) attaches the external meatus to the anterior surface of the pubic bones. It is a 6th ligament, not directly relevant to POP causation, but important for urethral sealing (Figure 4).

Vagina. The vagina is a weak elastic membrane with little structural strength. It is attached to the cervix and side wall skeleton via its ligamentous and muscular attachments. The vagina has a squamous epithelial layer and attached below, a ‘fascial’ layer. This layer is known as the ‘PCF’ (pubocervical fascia) for the anterior vaginal wall and ‘RVF’ (rectovaginal fascia) for the posterior vaginal wall. Both structures contain smooth muscle, collagen, elastin, nerves and blood vessels¹.

Anterior vaginal wall. The fascial layer (pubocervical fascia ‘PCF’) attaches proximally to the anterior cervical ring and cardinal ligaments, laterally to ATFP and distally to the pubococcygeus muscle (‘pubovaginalis’) distal urethra and external urethral ligament (Figure 1).

Posterior vaginal wall. The fascial layer (rectovaginal fascia ‘RVF’) attaches to uterosacral ligaments, posterior cervical ring, ATFP laterally via the paracolpium, and distally, to perineal body and rectum (Figure 2).

Consequential anatomical relationship of the rectum (Figures 2-4). The USL attaches to the lateral walls of rectum and suspends it to the skeleton (sacrum); levator plate (LP) inserts into the posterior rectal wall. Rectovaginal fascia ‘RVF’ attaches to levator plate ‘LP’, perineal body ‘PB’ and cervix. LP contracts backwards to tension the uterus, the USLs, perineal body and posterior wall of the rectum. Anything which loosens USL will create a cascade of symptoms from the functions dependent on the USL muscle/ligament relationships. These are summarized in the pictorial algorithm (see Parts 3 & 4).

Organ spaces. Organ spaces (Figure 2) are essential to allow free movement of bladder over vagina and vagina over rectum. Especially vulnerable is the rectovaginal

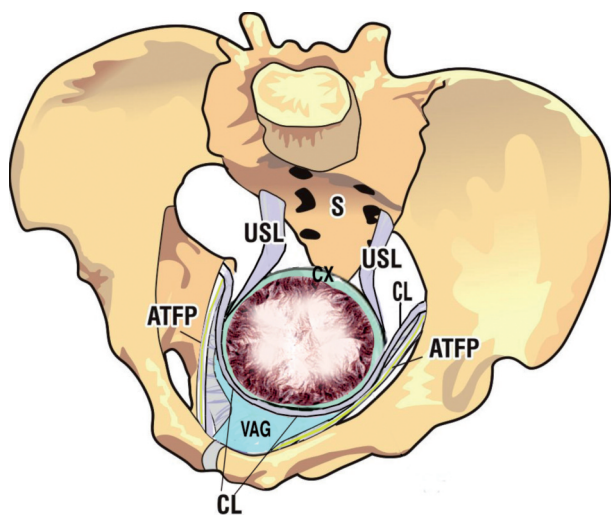


Figure 5. – Ligament damage at childbirth. View from above at 10cm dilatation of the cervix. The maximal strain of the 10cm dilatation is on the cervical ring attachments of vaginal ‘fascia’, uterosacral ligaments (USL) and cardinal (CL) ligaments and attachment of paracolpium of vagina laterally to ATFP. Extension or tearing of these attachments may cause apical prolapse, cystocele anteriorly, rectocele and enterocele posteriorly. The perineal body may be damaged and separated to cause low rectocele (perineocele) as the head exits the birth canal.

space. If the rectum and vagina are glued together via interposition of a mesh or surgical scarring, this may prevent natural stretching during intercourse in some individuals and dyspareunia and/or evacuatory dysfunction/incontinence may result. The basic cause of the pain is the stretching of the viscerally innervated vagina; pain in a visceral organ is caused by distension.

Muscles. There are 4 directional pelvic muscles, two forward acting, pubococcygeus muscle (PCM), puborectalis

muscle (PRM) and two backward, levator plate (LP) and conjoint longitudinal muscle of the anus (LMA) (Figure 4). They also support the organs from below. They contract or relax selectively to close the urethral or anal tubes (continence), open them (evacuation) or support the bladder and rectal stretch receptors to control the micturition and defecation reflexes.

Muscles contract against suspensory ligaments. With reference to Figure 4, only the PRM does not contract against any ligaments. It contracts against the pubic symphysis; the pubovaginalis portion of PCM contracts forwards against the pubourethral ligament (PUL); LP contracts backwards against PUL; LP and LMA contract backwards and downwards against the cardinal/uterosacral ligament complex (CL/USL).

If a ligament is loose, the muscle lengthens and loses contractile force, Gordon’s Law⁵. All functions of that muscle, including organ support, will be compromised, as a striated muscle must have a firm insertion point to function optimally.

PATHOGENESIS OF POP

Causation of pelvic organ prolapse is by stretching of the suspensory ligaments, and/or distension or tearing of vaginal fascia (Fig. 5 and 6). The resulting affect is lack of support leading to prolapse, and lack of tension in the organs leading to failure of muscular control and dysfunction.

CONCLUSIONS

The pelvis functions like a suspension bridge. Strength is derived by tensioning the cables (ligaments). If these are damaged they need to be reinforced and strengthened along their natural anatomical axis. Shortening and strengthening the ligaments also restores the directional muscle forces which contract against these ligaments to restore organ support from below and restore function.

CONFLICTS

There are no financial conflicts.

REFERENCES

1. The Integral Theory System, “The Female Pelvic Floor. Function, Dysfunction and Management according to the Integral Theory”, 3rd Edition, 2010, Petros PEP, Springer, Heidelberg.
2. Petros PE, Ulmsten U. An Integral Theory of female urinary incontinence. Acta Obstetrica et Gynecologica Scandinavica, Supplement 1990; 69: 1-79.
3. Yamada H. Aging rate for the strength of human organs and tissues. Strength of Biological Materials, Robert E Krieger New York, (Ed) Evans FG. 1973.
4. Wagenlehner F. M. E., Del Amo E, G. A. Santoro GA and P. Petros, Live anatomy of the perineal body in patients with third-degree rectocele Colorectal Disease 2013; 15: 1416-1422.
5. Gordon AM, Huxley AF, Julian FJ. The variation in isometric tension with sarcomere length in vertebrate muscle fibres. J Physiol. 1966;184:170-92.

Correspondence to:

Darren M Gold, Colorectal Surgeon,
Senior Lecturer in Surgery, St Vincent’s Clinical School,
UNSW, Sydney, Australia
e-mail: dandjgold@gmail.com

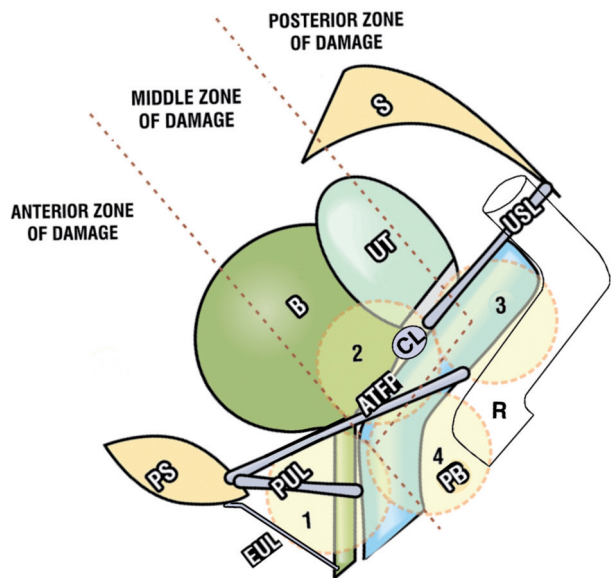


Figure 6. – Ligament damage at childbirth, schematic sagittal view As the head descends down the birth canal, circles 1-4, it may stretch or tear the ligaments or fascial attachments of the vagina. Circle 2. Cystocele. Defects: ATFP, CL, pubocervical fascia (PCF). Circle 3. Uterine prolapse, high rectocele, enterocele, anterior rectal wall intussusception Defects: USL, rectovaginal fascia (RVF). Circle 4 Middle and low rectocele Defects: PB, rectovaginal fascia (RVF). Circle 1 Stress urinary incontinence Defects: PUL, EUL, distal vagina.