

Pain reduction after anti-incontinence operation with a shortened sub-mid urethral sling implant and medial needle trajectory

REUT GILAD, MENAHEM NEUMAN, JACOB BORNSTEIN

Urogynecology, dep. of Ob-Gyn, Galilee M.C., Nahariya, and the Faculty of Medicine, Safed, Bar-Ilan University, Israel

Abstract: *Aim of the study:* We wanted to evaluate the 3 year-efficacy and the reduction in incidence, durability and severity of post-operative pain after trans-obturator sub mid urethral sling implantation with sling shortening and needle trajectory by medial route vs. results in previous studies reported in the medical literature of similar surgery using the Tension-free vaginal tape trans-obturator method. *Methods:* In this retrospective study, 82 patients' pre and post-operative data was collected from the medical records and by a telephone interview questionnaire regarding relief of symptoms and post-operative complications, focusing on post-operative pain. *Results:* Of the eighty two participants, most reported very low incidence and severity of post-operative pain. Two patients (2%) had post-operative moderate dyspareunia, while four patients (3.6%) suffered significant post-operative overactive bladder symptoms. Previously reported data regarding the trans-obturator sub mid urethral sling procedure showed that 11.5% and up to 30% of operated patients suffered post-operative pain, mainly at the thigh, pelvis and vagina, lasting for an average of two weeks. Some had chronic intractable thigh pain related to obturator neuralgia. Surgical attempts to remove the implant failed to improve the outcome. The operative cure rates shown here, evaluated by SUI symptoms persistence, were similar to those previously reported with the trans-obturator sub mid urethral sling procedure. *Conclusion:* The short sub mid urethral sling, positioned according to the FF method, is shown to lower the post-operative pain, while maintaining similar efficiency with SUI cure.

Keywords: Urinary stress incontinence; Trans-obturator sub mid urethral sling; Over-active bladder.

INTRODUCTION

Female urinary stress incontinence (USI) is defined as involuntary leakage of urine during physical activity, sneezing, or coughing.^{1,2}

Stress leakage occurs when an increase in intra-abdominal pressure overcomes sphincter closure mechanisms in the absence of bladder contraction.

DeLancey (1993), concluded that the underlying pathophysiology is associated with a defect in bladder neck and urethra due to the laxity of surrounding tissues and insufficiency of the internal sphincter of the urethra.³

Stress urinary incontinence is the most common cause of urinary incontinence in younger women, and the second most common cause in older women.^{4,5}

This is a significant public health problem, as shown by the 10% lifetime risk a woman has to undergo a surgical intervention to treat this bothersome condition.

The first choice of treatment for SUI is a conservative approach including lifestyle modifications (physical activity, dietary habits, and weight loss), bladder control exercises, and pelvic floor muscle training (PFMT). In the failure of conservative treatment, surgical treatment is necessary.⁶

The retro-pubic open colpo-suspension was widely used until Ulmsten (1996) described a new minimally invasive technique, a tension-free vaginal tape (TVT) for urinary incontinence treatment.⁷

This operation, based on a sub mid-urethral Prolene tape support, has been accepted worldwide as an easy-to-learn, effective and safe surgical technique. Recent prospective randomized studies have reported that the TVT success rate ranges from 80% to 95% with a longer-than-5-year follow-up.⁷⁻¹²

However, there have been several rather rare complications during and after the TVT procedure such as: bladder penetration, postoperative urinary outlet obstruction, bowel penetration and intra-operative and post-operative bleeding. These adverse events were attributed to the retro-pubic needle passage, proximal to the bladder, bowel and blood vessels.¹³⁻¹⁶

Modifying the retro-pubic TVT needle pass to the trans-obturator route allows avoidance of the para-vesical space,

and reduces the risk of the TVT-related bladder, bowel, and vascular injuries.¹⁴

Emmanuel Delorme²⁷ and Jean de Leval¹¹ were encouraged to design a sub mid-urethral trans-obturator sling (TOT) wherein the TVT needle bypasses the retro-pubic area. Instead, the TOT needle route passes through the relatively safe medial compartment of the obturator fossa area, 2.5-3 cm medially to the obturator vessels and nerve, remote from the pelvic viscera and vessels.¹⁷

Studies suggest that this new minimally invasive, anti-incontinence operative procedure is associated with high cure rates and lower morbidity rates than TVT over the short term.¹⁷

As clinical evidence supporting its efficacy and safety at medium/long term has continued to grow, the TOT procedure has become widely adopted by urogynecologists and urologists worldwide.¹⁸

Nevertheless, pain can occur after retro pubic and trans obturator tape procedures, especially with de-Leval's method¹⁹⁻²¹, at a rate of 11.5% up to 30% among operated patients, according to previous studies.

Following trans obturator procedures, pain symptoms are typically experienced by women at the groin/thigh region and are transient in the vast majority of subjects.²¹⁻²²

The source of groin pain after trans-obturator procedures may originate from trauma secondary to the penetration of the dissecting scissors, needles, and/or tape into muscular (i.e. obturator and adductor muscles) and/or aponeurotic (i.e., obturator membrane) structures. It could also be related, however, to a foreign-body reaction to the tape, possibly in proximity to peripheral obturator nerve branches.

Theories of the origin of groin pain after TVT-Obturator sling include direct obturator nerve damage or indirect nerve compression and a myofascial syndrome arising from muscle hypertonia secondary to excessive tension or incorrect placement of the tape.²⁹

To address these issues of postoperative groin pain as well as the – rather theoretical – risk of obturator nerve injury and to further improve the original surgery, the original TOT procedure was modified²⁸ to further reduce TOT-related post-operative thigh pain, by shortening the tape implant (TVT-

Abbrevio®, Ethicon, USA),²⁴ theorizing that a reduced amount of mesh would decrease post-operative groin pain.²⁹

At 1 year follow-up, the modified inside-out trans-obturator sub mid urethral tape procedure was deemed as safe and efficacious as the original TVT-O, and also associated with less immediate postoperative groin pain.²⁵

Although short term follow-up has been documented, longer-term evaluation has not appeared in the medical literature. Therefore, we wanted to evaluate the 3 year-efficacy and the reduction in incidence, durability and severity of post-operative pain, comparing patients operated according to a modified trans-obturator sub mid urethral sling procedure (TVT-Abbrevio), using a 12 cm-long polypropylene tape, in comparison with previously-published studies evaluated the same in TVT-O patients.

We expected to find that post-operative pain, severity and durability following the TVT-Abbrevio will be reduced, while other peri-operative complications and the therapeutic efficiency will be unchanged.

PATIENTS AND METHODS

This retrospective study examined the medical records of patients operated at a single center.

Inclusion criterion was the modified TVT-Abbrevio operation for USI, previously diagnosed by the history taking and cough test.

Exclusion criteria included absence of complete medical records and patient's refusal to participate in an interview. All operations were carried out by an experienced surgeon at a private hospital. The study was approved by the hospital's Institutional Review Board.

The operations were performed according to previously reported surgical steps.²⁸ In short, a 1 cm. longitudinal vaginal cut was made at the sub mid urethral area, sub mucosal lateral tunnels were created up to the inferior pubic ramous, the TVT-Abbrevio needles were passed close to the bone through the medio-anterior compartment of the obturator fossa and out at the covering skin, through the major labia.

Study participants' data regarding relief of symptoms and peri and post-operative complications, focusing on post-operative pain location, severity, duration and frequency, were carefully collected from the medical records. The data had been collected at three years' post-op telephone interview questionnaire regarding relief of symptoms and post-operative complications including post-operative thigh pain. Patients were routinely asked at follow-up visits whether they experience groin pain or inner thigh pain. Charts were reviewed for complaints of post-operative groin pain at any stage of follow up.

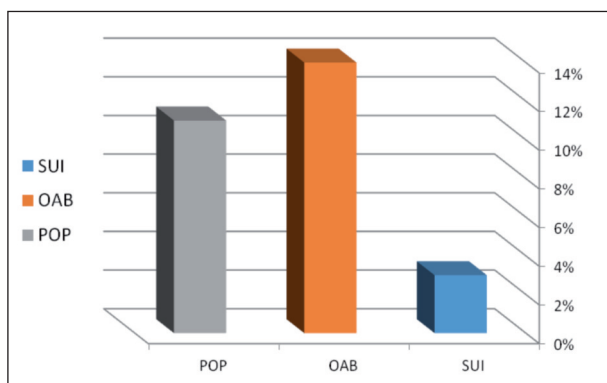


Figure 1. – Post Op clinical data.

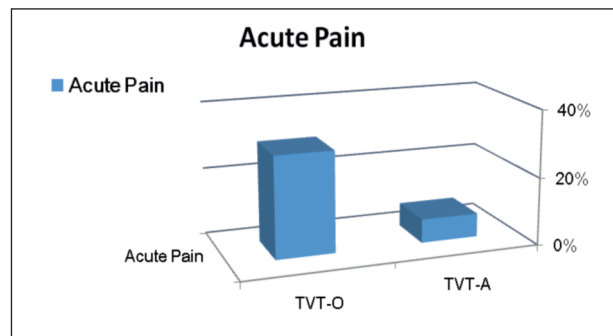


Figure 2. – Early post Op pain.

The percentage of patients with significant pain after surgery was expected to decrease significantly by using a medially placed short sling.

A 95% confidence interval for proportion was calculated for comparison of the expected differences in outcomes (this research vs. the literature): significant pain in no more than 10% of patients who underwent TVT-Abbrevio with modified needle surgery, compared to above 20% for the TVT-O procedure as quoted in the literature.

These results are based on one sample test for Proportions, alpha 5%, 1-sided hypothesis, examination of at least 80 patients is needed to achieve power of 81%.

Data was collected from 102 patients' charts by researchers not involved with the patients' care. Postoperative pain was assessed with a 0-10 Visual Analog Scale (VAS). Normally distributed continuous data were described using means and standard deviations, resorting to the median and inter quartile range for those not matching a normal distribution. Categorical data were described using numbers and percentages.

RESULTS

Between May 2011 and January 2012, a total of 102 patients suffering from SUI underwent TVT-Abbrevio implantation. Of these, 20 patients (20.4%) were lost to follow up after their first postoperative visit. Of the remaining 82 patients, 6 patients (7%) suffered early post-operative thigh pain described as mild, for up to one month after the procedure. Two patients (2%) reported early post-operative mild pelvic pain lasting for 2 weeks, and 3 patients (4%) reported mild dyspareunia which disappeared after two months in 2 patients and 4 months in the third.

Eleven patients (13%) complained of significant sustained post-operative Over Active Bladder (OAB) symptoms. Nine patients (11%) reported bulging symptoms during the third year following the procedure. Of these 9 patients, seven suffered only mild POP symptoms not necessitating any intervention, while 2 suffered moderate symptoms and required therapy. Finally, 2 patients (2.5%) reported mild SUI symptoms at the 3 year-post-operative interview.

The data retrieved from previous studies regarding the TVT-O procedure, showed that 11.5% up to 30% of operated patients suffered post-operative pain, mainly at the thigh, pelvis and vagina. Some had intractable chronic thigh pain related to obturator neuralgia. Surgical attempts to remove the implant failed to improve the pain. The operative cure rates, evaluated by SUI symptoms persistence, were similar to those previously reported for the TVT-O procedure.

DISCUSSION

The main finding of the present study was that while the operative urinary incontinence cure rates reported here are similar to the ones previously reported in the literature for

the TVT-O technique, the primary outcome measure of our study, the incidence and duration of postoperative thigh pain, differed significantly.

Postoperative pain may appear as a result of tissue damage at the central obturator region radiating to the thigh, with subsequent spontaneous healing and recovery.

Persistent groin pain after an uncomplicated TVT-O procedure may be explained by damage of a peripheral branch of the obturator nerve. Though such damage is rare, it can occur. According to the FF method, instead of passing the needle tangentially through the central part of the obturator membrane and muscles, it is inserted perpendicularly, through the medial section of these structures, with the purpose of causing less tissue damage by virtue of its remoteness from the obturator nerve, thereby reducing postoperative thigh pain.

The shortened TVT-Abbrevio tape placed at a medial modified position appears to permit fixation in those tissues critical for support, while avoiding the muscles likely related to groin pain.

Our hypothesis regarding the lower rate of postoperative pain with the short sub mid urethral sling positioned according with FF method was confirmed, as well as our assumption regarding the similar cure rates between the two procedures

This trans-obturator sub mid urethral short sling implant method reduced the early post-operative pain to 6% compared to approximately 11.5-30% according to the previous TVT-O method reported in the medical literature.

In conclusion, the short sub mid urethral sling positioned according with the FF method is shown to have both lower post-operative pain and maintain similar efficiency with SUI cure rates.

DISCLOSURE STATEMENTS

There was no conflict of interest and informed patient consent was obtained.

REFERENCES

1. Nitti VW, Blaivas JG. Urinary incontinence: epidemiology, pathophysiology, evaluation, and management overview. In: Wein AJ, Kavoussi LR, Novick AC, editors. Campbell-Walsh urology. 9th ed. Philadelphia: Saunders Elsevier; 2007. pp. 2046-78.
2. Abrams P, Cardozo L, Fall M, et al. The standardization of terminology of lower urinary tract function: report from the Standardization Sub-committee of the International Continence Society. *Am J Obstet Gynecol.* 2002; 187: 116-26.
3. DeLancey JOL. Anatomy and biomechanics of genital prolapse. *Clinical Obstetrics and Gynecology.* 1993; 36 (4): 897-909.
4. Shao Y, He HC, Shen ZJ, et al. Tension-free vaginal tape retro-pubic sling for recurrent stress urinary incontinence after Burch colpo-suspension failure. *Int J Urol.* 2011; 18: 452-7.
5. Minassian VA, Drutz HP, Al-Badr A. Urinary incontinence as a worldwide problem. *Int J Gynaecol Obstet.* 2003; 82: 327-38.
6. Zyczkowski M, Nowakowski K, Kuczmik W, Urbanek T, Kaletka Z, Bryniarski P, Muskala B, Paradyś A. Analysis. *Biomed Res Int.* 2014; 2014: 347856.
7. Ulmsten U, Henriksson L, Johnson P, Varhos G. An ambulatory surgical procedure under local anesthesia for treatment of female urinary incontinence. *Int Urogynecol J.* 1996; 7: 81-6.
8. Ausra Cerniauskiene, Marija Barisiene, Feliksas Jankevicius, Gediminas Januska. Treatment of recurrent stress urinary incontinence in women: comparison of treatment results for different surgical techniques. *Video surgery Mini Inv* 2014; 9 (2): 239-245.
9. Olsson I, Kroon U. A three-year postoperative evaluation of tension-free vaginal tape. *Gynecol Obstet Invest* 1999; 48: 267-9.

10. Kuuva N, Nilsson CG. A nationwide analysis of complications associated with the tension-free vaginal tape (TVT) procedure. *Acta Obstet Gynecol Scand* 2002; 81: 72-7.
11. Paraiso MFR, Muir TW, Sokol AI. Are mid-urethral slings the gold standard surgical treatment for primary genuine stress incontinence? *J Am Assoc Gynecol Laparosc* 2002; 9: 405-7.
12. Waetjen LE, Subak LL, Shen H, et al. Stress urinary incontinence surgery in the United States. *Obstet Gynecol* 2003; 101: 671-6.
13. Neuman M: Tension-free vaginal tape bladder penetration and long-lasting trans-vesical prolene material. *J Pelvic Med Surg* 2004; 10 (6): 307-309.
14. Grise P, Lobel B, Grall J. Les complications du TVT. *Prog Urol* 2003; 13 (1): 144-6.
15. Cody J, Wyness L, Wallace S, et al. Systemic review of the clinical effectiveness and cost-effectiveness of TVT for the treatment of urinary stress incontinence. *Health Technol Assess* 2003; 7 (21): 1-189.
16. Palva K, Rinne K, Kivela A et al. A randomized trial comparing tension free vaginal tape with tension free vaginal tape obturator: 36 months results. *Int Urogynecol Pelvic Floor Dysfunct.* 2010; 21 (9): 1049-55.
17. Menahem Neuman. TVT-Obturator: Short-term data on an operative procedure for the cure of female stress urinary incontinence performed on 300 patients. *Eur Urol.* 2007; 51 (4): 1083-7; discussion 1088.
18. Jean de Leval, Alexandre Thomas, David Waltregny. The original versus a modified inside-out trans-obturator procedure: 1-year results of a prospective randomized trial. *Int Urogynecol J* (2011), 22: 145-156.
19. Bourrat M, Armand C, Seffert P, et al. Complications and medium-term functional results of TVT in stress urinary incontinence. *Prog Urol.* 2003; 13 (6): 1358-64.
20. Duckett JR, Jain S. Groin pain after a tension-free vaginal tape or similar suburethral sling: management strategies. *BJU Int.* 2005; 95 (1): 95-7.
21. Duckett J, Baranowski A. Pain after suburethral sling insertion for urinary stress incontinence. *Int Urogynecol J.* 2012; DOI: 10.1007/s00192-012-1863-3.
22. Waltregny D, de Leval J. The TVT-obturator surgical procedure for the treatment of female stress urinary incontinence: a clinical update. *Int Urogynecol J Pelvic Floor Dysfunct.* 2009; 20 (3): 337-48.
23. de Leval J, Thomas A, Waltregny D. The original versus a modified inside-out transobturator procedure: 1-year results of a prospective randomized trial. *Int Urogynecol J.* 2011; 22 (2): 145-56.
24. Waltregny D, de Leval J. New surgical technique for treatment of stress urinary incontinence TVT-ABBREVO from development to clinical experience. *Surg Technol Int.* 2012 Dec; 22: 149-57.
25. Waltregny D, Reul O, Mathantu B, et al. Inside out transobturator vaginal tape for the treatment of female stress urinary incontinence: interim results of a prospective study after a 1-year minimum followup. *J Urol.* 2006; 175 (6): 2191-5.
26. Neuman M, Sosnovski V, Goralnik S, et al. Comparison of two inside-out transobturator suburethral sling techniques for stress incontinence: Early postoperative thigh pain and 3-year outcomes. *Int J Urol.* 2012; DOI: 10.1111/j.1442-2042.2012.03117.x
27. Delorme E, Droupy S, de Tayrac R, Delmas V. Transobturator tape (Uratape). A new minimally invasive method in the treatment of urinary incontinence in women. *Journal de L'Association Francaise D'urologie et de la Societe Francaise D'urologie* [2003, 13 (4): 656-659].
28. Neuman M, Hubka P, Martan A et al. Modified needle route for potential reduction of the trans-Obturator inside-out related thigh pain: a cadaveric study. *Gynecol Surg.* 2011; 8: 171-3.
29. Jonathan S. Shaw, Peter C. Jeppson, Charles R. Rardin. Decreasing trans-obturator sling groin pain without decreasing efficacy using TVT-Abbrevio. *Int Urogynecol J* (2015) 26: 1369-1372.

Correspondence to:

Prof M. Neuman, mneuman@netvision.net.il