

Post vesico-vaginal fistula repair incontinence - A new hypothesis and classification potentially guide prevention and cure

PETER PETROS³, GORDON WILLIAMS², ANDREW BROWNING¹

¹ Arusha Tanzania, Fistula Dept

² Bethel Teaching and General Hospitals Addis Ababa Ethiopia, Urology

³ St Vincent's Hospital Clinical School, University of NSW, Sydney, Professorial Unit, Department of Surgery

Background: Post-repair urinary incontinence is a major problem in women who have had successful repair of their vesico-vaginal fistula. Rates of incontinence of 16% to 55% after successful repair of the fistula have been reported. The basis of our hypothesis is the demonstration in the normal patient that 3 oppositely acting directional vectors close the distal and proximal parts of urethra. Adequate elasticity is required in the bladder neck area of the vagina for these two mechanisms to operate independently. *The hypothesis* Tissue necrosis and consequent scarring in the bladder neck area of the vagina “tether” the stronger posterior vectors to the weaker forward vectors, overcoming them, so that the urethra is opened out instead of being closed. *Testing the hypothesis* The treatment proposed during the primary fistula repair is to release the vaginal tissue from its scarred attachments to the urethra and pubic bones. After repair of the bladder defect, if there is a gap between the dissected walls of vagina (i.e., a tissue deficit), a skin graft is inserted to restore the elasticity required in the bladder neck area of the vagina for the two separate closure mechanisms to operate independently of each other. Similar principles apply to patients with ongoing incontinence some time after fistula closure. *A new classification* We believe that there is only one issue as regards fistula classification. If, after full dissection of the vagina off the pubic bones and urethra the two sides of vagina remain separated, then a skin-on flap is required. Any forcible approximation of tissue will lead to problems.

Keywords: Post fistula repair incontinence; Fistula; Tethered vagina; Skin-on Martius graft; Singapore graft.

INTRODUCTION

It is estimated that at least 3 million women in poor countries have unrepaired vesicovaginal fistulas, and that 30 000–130 000 new cases develop each year in Africa alone.¹ The psychosocial damage is devastating, with many of these women divorced, alienated and exiled from their families.¹

Success rates of closure for primary procedures between 73% and 90% have been reported by throughout Africa.² The FIGO training manual aims to have at least 85-90% closure rate. These impressive results have unmasked another major problem: persistent urinary incontinence even after successful closure of the fistula. Rates of incontinence of 16% to 55% after successful repair of the fistula have been reported.² For many women, after a repair of the vesicovaginal fistula, urethral incontinence is so severe that their incontinent symptoms remain unchanged. These women subsequently believe their successful repair was a failure. Urodynamics (UDS) based therapy does not appear to be successful. On UDS testing at the Addis Ababa Fistula Hospital (AAFH), 121 women had a mixture of stress and detrusor instability (DI), 18 pure stress and 2 DI only. 29 had overflow and 6 were normal. Treatment with 2 months Oxybutynin in 155 women with DI cured only 9 and improved 65 (GW, AAFH unpublished data). Nor have attempts at surgical cure been overly successful. A “patient dry” rate of 24% was recently reported in 96 patients undergoing a fascia lata sling.²

THE HYPOTHESIS

The hypothesis had its origins in a visit to AAFH by one of the authors (PP) in 2012 where many patients were found to have some, but not all characteristics of the Tethered Vagina Syndrome.³ One major point of difference was that urine leakage at night is extremely rare in women who have the Tethered Vagina Syndrome, but not uncommon in the post-repair fistula patient. The hypothesis and suggested treatment follows many discussions between the authors since that date.

In previous studies, it was assumed that the cause of post-fistula incontinence was either urinary stress incontinence (USI) or an unstable bladder.^{2,4} Though urine loss may be lost with effort with both USI and Tethered Vagina, the pathogenesis of Tethered Vagina Syndrome is quite different from that of urinary stress incontinence (USI). Whereas USI is usually caused by urethral hypermobility, a result of a loose pubourethral ligament, Tethered Vagina Syndrome is caused by loss of elasticity in the bladder neck area of vagina, figs 1A,1B and 2. In the Western woman, this is a result of excess bladder neck elevation after a Burch Colposuspension or scarring after vaginal repair.³ Treatment is by a plastic operation to augment vaginal tissue in the bladder neck area of vagina, or if there is significant tissue deficit, a skin graft is applied, preferably a skin-on Martius graft,⁵ figure 3, Singapore graft or a split labium minus graft.⁶

It is our hypothesis that a major cause of post fistula repair incontinence is neither a loose pubourethral ligament nor an overactive bladder. Rather, it is tissue necrosis consequent upon obstructed labour which leads to scarring in the bladder neck area of the vagina. This “tethers” the stronger posterior vectors to the weaker forward vectors, figure 2, overcoming them, so that the urethra is opened out instead of being closed on effort and in severe cases, at rest.

In the normal continent patient, figures 1A, 1B, PCM vector (m.pubococcygeus) stretches the distal vagina forwards against the pubourethral ligament (PUL) to close the distal urethra.⁷ The backward/downward vectors, levator plate (LP) and conjoint longitudinal muscle of the anus (LMA) stretch and rotate the proximal urethra backwards and downwards around PUL to close the bladder neck.⁷ Adequate elasticity in the bladder neck area of vagina (“zone of critical elasticity” (ZCE), fig1A,1B) is required for this to occur.⁷

With significant scarring at ZCE, the vector forces (backward arrows, figure 2) are directly transmitted via the scar to overcome the weaker forward vector PCM. In consequence, the posterior urethral wall is forcibly pulled open, resulting in a sudden rush of urine typically on straining or getting up off a chair. With coughing there may be little or

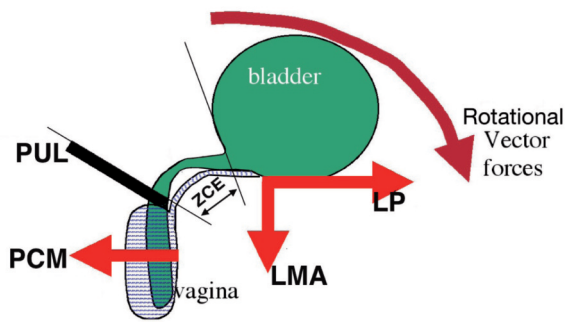


Figure 1A. – Normal urethral closure in the female during coughing or straining⁶ PCM = m.pubococcygeus. LP= levator plate ;LMA= conjoint longitudinal muscle of the anus; PUL=pubourethral ligament. ZCE (zone of critical elasticity), allows separate action of forward and backward vectors.

no urine loss, as there may be just sufficient elasticity for the rapid opposite motion of the fast twitch fibres. This explains why post VVF incontinence patients often leak when downward pressure is exerted with a speculum in the vagina. This action removes any remaining elasticity in ZCE. In women such as many of those from AAFH who wet constantly, the tethering effect may be sufficiently severe as to keep the urethra in a constantly ‘open’ position even at rest, so leakage is continuous.

OBJECTIVE FINDINGS CONSISTENT WITH THE HYPOTHESIS

The only objective anatomical study of which we are aware is the 4D ultrasound study performed by Dietz et al.⁴ Dietz mentioned scarring throughout the study “assessment was often difficult due to extensive scarring, a common feature after VVF (vesicovaginal fistula)”. However, Dietz et al did not quantify the amount and incidence of scarring, as their objectives were to determine the effects on muscle function. The finding of extensive scarring supports our hypothesis.

Though 52/95 women were said to have symptoms of urinary stress incontinence (USI), only 3 had hypermobility on ultrasound examination), of whom 2 had a positive

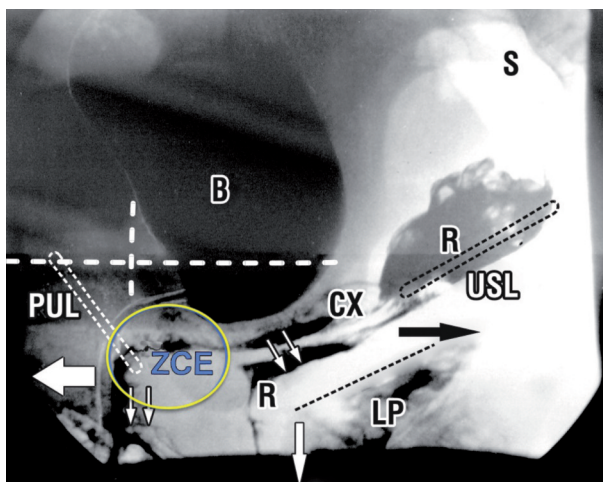


Figure 1B. – Xray Normal patient, sitting position, straining. Oppositely acting vector forces during straining (arrows) indicates the imperative of an elastic zone at ZCE so as to allow the vector closure forces to operate independently. Labelling as in 1A. CX = cervix; R = rectum; B = bladder; USL = uterosacral ligaments; S = sacrum.

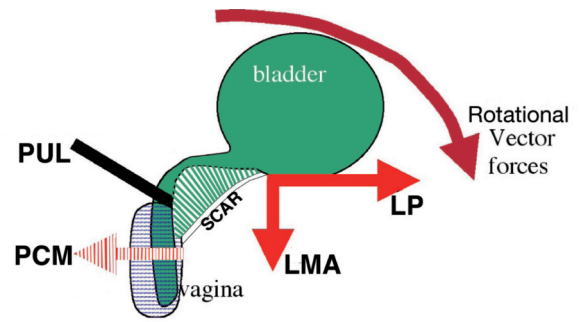


Figure 2. – Mechanism of scar induced incontinence During effort, LP/LMA vectors overcome the weaker PCM vector (weakness indicated by broken lines) to open out the urethra as per micturition.⁶

clinical stress test, urine loss not being through the urethra.⁴ If a loose pubourethral ligament (hypermobility) was a major cause of post incontinence surgery urine loss, there would have been a far greater number with hypermobility than the 2/95 recorded.

Abnormal levator function and anatomy in women patients with vesicovaginal fistula was found.⁴ Levator avulsion was 28% (unilateral) and 11% (bilateral), no more than in unselected urogynecological patients in the developed world. There was no evidence of permanent denervation of the levator ani, nor was there any muscle weakness detected on palpation of the puborectalis muscles.⁴ The finding of normal muscle strength is consistent with our hypothesis of an external factor, scarring, disturbing the urethral closure function.

Proposed surgical methodology for prevention and treatment of post-incontinence surgery incontinence

Because of tissue necrosis and destruction, scarring and deficit of the tissues is generally present. The dissection techniques applied for cure of VVF generally involve the mobilization of neighbouring tissues. Although it is taught that the tissues be closed with no tension, often the vaginal defect is stretched to cover the tissue deficit. Unfortunately such tissues are subject to viscoelastic creep and tend to migrate back whence they came. A new gap is created below the epithelium and scarring occurs with secondary intention creating the conditions for scar-induced incontinence.

PREVENTION

It is our belief that the focus of treatment for post-fistula incontinence should, above all, be on prevention: ensuring that there is adequate elasticity in the bladder neck area of the vagina during the primary fistula repair.

In this endeavor, only a single principle should be observed: if, after dissection, there is a natural gap between the two walls of vagina, the tissues should not be forcibly closed. Rather, a skin graft should be applied to cover the gap. Ideally, the graft should come with its own blood supply.^{5,6} A skin-on Martius graft (or similar, e.g. Singapore graft), fig3, needs to be applied to the bladder neck area of the vagina (ZCE), as this is the only way to restore the elasticity required in this area for independent function of the opposite vector forces.

Because of language and infrastructure issues, there will be problems in performing a systematic objective study using validated questionnaires, pad tests, adequate post-operative review.

A simple test, dryness or not, may possibly be sufficient assessment.

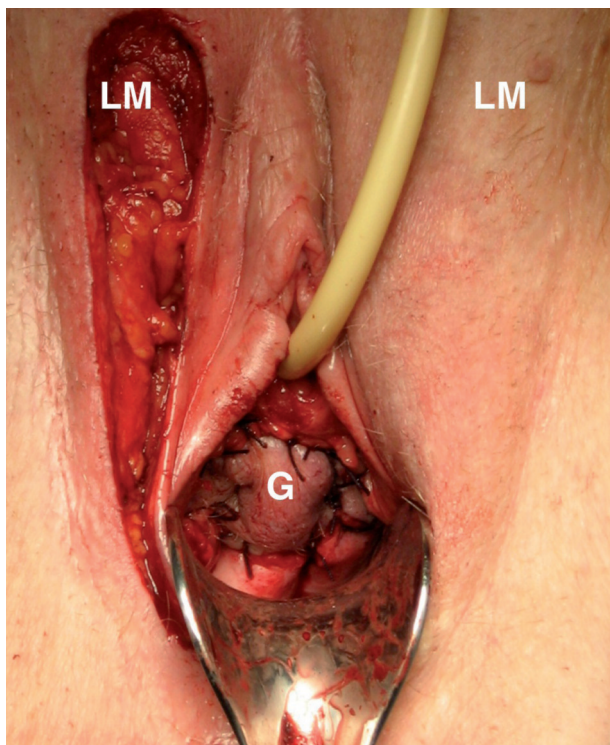


Figure 3. – Augmentation of ZCE with a skin-on Martius Graft restores independent movement of the vector forces. LM=labium majus ; G=graft sutured to bladder neck area of vagina to cover the tissue deficit.

Though we have successfully tested the hypothesis in a small handful of patients with promising initial results, further testing is required.

A NEW CLASSIFICATION

A classification has to be useful as a predictor and guide to treatment. As we see it, the whole issue of post-fistula incontinence is essentially a biomechanical problem deriving from vaginal tissue deficit and scarring.

In this context, we believe that there is only one issue as regards classification. If, after full dissection of the vagina off the pubic bones and urethra the two sides of vagina remain separated, then a skin-on flap is required. Any forcible approximation of tissue will lead to problems.

Separate to this is the status of the organ, bladder, urethra, ureters, rectum. A classification is not required here. Any repair has to mimic the anatomy. If a urethra is destroyed, a smooth muscle tube has to be fashioned which connects with the detrusor; a pubourethral ligament-like structure has to be fashioned at midurethra to prevent urinary stress incontinence and a layer of skin fashioned below the urethra to re-constitute a suburethral vaginal hammock.

A skin-on Martius graft or similar can augment vaginal tissue in cases of rectal damage.

If after the anatomy has been restored a patient complains of urgency, pain, nocturia, these symptoms are dealt with according to the protocols of the treating surgeon.

CONCLUSIONS

We have proposed a new direction for prevention and cure of post vesicovaginal fistula incontinence. The methodologies proposed are biomechanically based and are simple to perform. However, they await a properly planned RCT, performing the graft or not, dryness or not, in a well co-ordinated series of patients. Short term results would be available. Longer term results may be logistically difficult to assess.

POSTSCRIPT 1. Dr Andrew Browning inserted skin grafts on 5 patients cured of fistula but still leaking urine. Mean pre-op one hour pad loss was 184ml; post-op loss was 22ml in one patient and 4 were completely dry. The study is proceeding.

POSTSCRIPT 2. Cure of massive urine loss with a skin graft we see as the ultimate test of the Integral Theory.

CONFLICTS, FUNDING

None.

CONTRIBUTIONS

Other than the diagrams, all authors contributed equally, hypothesis, writing, revision.

REFERENCES

1. Wall LL Obstetric vesicovaginal fistula as an international public-health problem *Lancet* 2006; 368: 1201-09.
2. Ascher-Walsh CJ Capes TL Lo Y Idrissa A Wilkinson J Echols K Crawford B Genadry R, Sling procedures after repair of obstetric vesicovaginal fistula in Niamey, Niger, *Int Urogynecol J.* 2010; 21: 1385-1390.
3. Petros PE & Ulmsten U. The free graft procedure for cure of the tethered vagina syndrome. *Scandinavian Journal of Urology and Nephrology*, 1993; 27 Supp. 153: 85-87.
4. Dietz HP Tekle H, Williams G Pelvic Floor Structure and Function in Women with Vesicovaginal Fistula *J Urol.* 2012; 188: 1772-1777.
5. Goeschen K, Müller-Funogea A, Petros P. Tethered vagina syndrome: cure of severe involuntary urinary loss by skin graft to the bladder neck area of vagina. *Pelviperrineology* 2010; 29: 100-102.
6. Petros PE. The split labium minus flap graft technique. *Int J Urogyn.* 2004; 15: 95-98.
7. Petros PE & Ulmsten U. An Integral Theory and its Method, for the Diagnosis and Management of female urinary incontinence. *Scand. J. Urol. Nephrol.* 1993; 27 Supp. 153-1-93.

Correspondence to:

Peter Petros
E-mail: pp@kvinno.com