

# Transobturator four arms mesh for simultaneous treatment of stress urinary incontinence and cystocele

NAAMA MARCUS BRAUN<sup>4</sup>, ANTOINE BOURRET<sup>3</sup>, CLAIRE DE VIENNE<sup>1</sup>, ANGELIQUE CHERET<sup>1</sup>, PETER VON THEOBALD<sup>2</sup>

<sup>1</sup>Centre Hospitalier Universitaire de Caen - Ob/Gyn

<sup>2</sup>Centre Hospitalier Universitaire Reunion Island - Ob/Gyn

<sup>3</sup>Port Royal, Hospital Group Cochin-Broca-Hôtel Dieu, University Hospitals of Paris, France-Ob/Gyn

<sup>4</sup>Ziv Medical center, Faculty of medicine, Safed - Ob/Gyn

**Abstract:** *Objective:* Stress urinary incontinence associated with pelvic organ prolapse is a frequent condition. The aim was to evaluate whether insertion of the anterior arms of transobturator four arms mesh under the mid-urethra can treat simultaneously the cystocele and incontinence without causing de novo urgency symptoms or voiding dysfunction. *Methods:* A comparative prospective study was conducted. The study group included patients treated for stress urinary incontinence and cystocele with the same mesh. The control group included all patients treated with a separated suburethral sling for stress urinary incontinence. Evaluation included POP-Q for prolapse documentation and cough stress test with full bladder for stress urinary incontinence. All patients completed the PFDI-20 and PFIQ-7 forms for prolapse symptoms and the PISQ-12 form for sexual function before and after the operation. *Results:* Fifteen patients in the study group were compared with 25 in the control group. The success rate of stress urinary incontinence treatment at the six-month follow-up was 93% for the study group and 84% for the control group. No signs of de novo urgency symptoms or persistent voiding dysfunction were detected. Significant improvement in mean total score and urinary score was detected in both groups on both pelvic floor questionnaires, and there was no difference between the groups before and after the operation. Sexual function improved in both groups. *Conclusions:* Stress urinary incontinence accompanied by cystocele can be treated in one operation with the same transobturator mesh, achieving both anatomical and functional cure and improvement in the patient's quality of life.

**Key words:** Cystocele; Life Quality Questionnaires; Stress Urinary Incontinence; Transobturator Four Arms Mesh.

## INTRODUCTION

Stress urinary incontinence (SUI) associated with pelvic organ prolapse (POP) is a frequent condition. When considering surgical correction, it is important to assess not only the surgical strategies but also the definition and the diagnosis of SUI in the presence of POP (occult SUI). Postoperative SUI is significantly more likely to occur in patients with a positive pre-operative test, which means that these patients have an anatomical defect that requires a treatment.<sup>1-3</sup> When performing both repairs at the same time, two options are available: inserting a sub-urethral sling through a second incision on the anterior vaginal wall or inserting the anterior arms of the cystocele mesh as a sub-urethral sling through a single incision.<sup>4,5</sup> This latter approach is debatable, mainly concerning the position of mesh under the trigon, which theoretically can cause de novo urgency symptoms (unstable bladder). We have previously described cystocele repair with a transobturator four arms mesh in 57 patients treated for cystocele and SUI with the same mesh and demonstrated SUI cure rate of 87.7% without causing de novo urgency symptoms.<sup>6</sup>

At the CHU of Caen we have been treating cystocele and SUI in the same procedure and with the same mesh since 2004. The special surgical technique is further described. Starting in 2009, all patients with POP and SUI complete life quality questionnaires (LQQ). Our aim was to determine whether insertion of the anterior arms of the transobturator four arms mesh under the mid-urethra can treat simultaneously the cystocele and the SUI without causing de novo urgency symptoms and to compare this solution with treatment of SUI with a separate sling with respect to SUI cure rates, functional results, and quality of life.

## MATERIALS AND METHODS

A comparative prospective study was conducted at the CHU of Caen, including all patients treated for SUI be-

tween January 2009 and January 2010 and completed LQQ forms. The study was approved by the local ethical committee. The study group included all patients who had cystocele and SUI, and who were treated with the IVS Tunneler™ 04 with quadra mesh (Polypropylene Monofilament Mesh, Covidien) in order to repair the SUI and cystocele with the same mesh. The control group included all patients who were treated with a suburethral sling for SUI alone or with correction of prolapse with a separate mesh.

Patients were evaluated before the operation, and postoperatively after six weeks and six months. Evaluation included Pelvic Organ Prolapse Quantification (POP-Q) for prolapse documentation and cough stress test with full bladder for evaluation of SUI. Occult SUI was determined by cough stress test after reduction of the prolapse. Urodynamic tests were conducted as needed, but not routinely. Furthermore, all patients were interviewed for urgency symptoms and voiding dysfunction before and after the operation. All patients completed the following LQQ forms: Pelvic Floor Distress Inventory (PFDI-20), Pelvic Floor Impact Questionnaire (PFIQ-7), and Pelvic Organ Prolapse/Urinary Incontinence Sexual Questionnaire (PISQ-12) before the operation and six months after it.

The main outcome measures were: post-operative SUI, post-operative de novo urgency symptoms, post-operative voiding dysfunction, and differences in life quality assessed by LQQ.

## Surgical technique

A midline incision of full thickness is performed on the anterior vagina, extending up to 1 centimeter from the urethral meatus. The bladder is dissected away from the vaginal wall, leaving Halban's fascia on the epithelium. The paravesical fossas are opened until the ischial spine and the arcus tendineus of the levator ani are reached. The paraurethral spaces are opened up to the ischiopubic rami. Between the paravesical fossas and the paraurethral spaces,

the internal part of the levator ani plate, the pubo coccygeous muscle, is visible and adhesive to the proximal urethra and the vaginal wall. Its thickness varies from one patient to another but it is usually about 1 centimeter at mid-line. The pubococcygeous muscle will serve as a barrier between the levels and support the suburethral part of the mesh, preventing any shifting toward the bladder neck (Figure 1A). The two anterior arms of the mesh (Polypropylene Monofilament Mesh, Covidien) are inserted with the IVS Tunneler™ 04 through the paraurethral dissection space, as in the case of a transobturator suburethral sling, exercising special care to ensure the absence of tension to treat the SUI (Figure 1B). The same tunneller is used for the insertion of the posterior arms, one centimeter lateral to the ischial spine on the arcus tendineus levator ani. The posterior part of the mesh is sutured to the uterine cervix or the vaginal vault with one or two absorbable sutures. The posterior arms are then pulled to create a subvesical hammock to treat the cystocele. The pubococcygeous muscle prevents direct contact with the vesical trigone. Finally, the vaginal epithelium is sutured without colpoectomy. The differences in the position of the four arms mesh for cystocele repair alone and for cystocele and SUI are illustrated in figure 2.

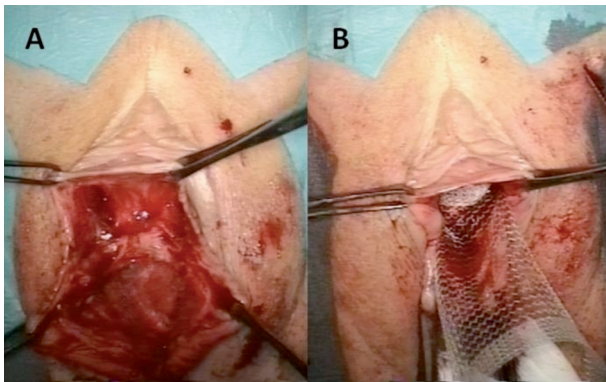


Figure 1. – Paraurethral and paravesical spaces separated by the pubococcygeous muscle (A). The anterior arms of the mesh are inserted through the paraurethral spaces as in the case of suburethral slings (B).

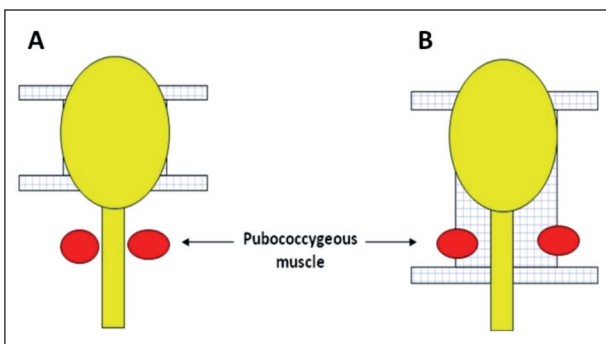


Figure 2. – Four armed transobturator mesh for cystocele (A) and four armed mesh for cystocele with concomitant SUI (B).

TABLE 1. – Mean urinary symptoms score on PDFI-20 and PFIQ-7 and sexual score on PISQ-12 before and after operation for study (Cystocele + SUI) and control (SUI) groups. \* non-significant.

	PDFI-20 urinary symptoms			PFIQ-7 urinary symptoms			PISQ-12		
	Pre-op	Post-op	p	Pre-op	Post-op	p	Pre-op	Post-op	p
SUI	38.37	12.915	0.0003	33.6	10.68	0.005	37.5	40.2	0.44*
Cystocele +SUI	50.67	18.91	0.01	41.36	12.09	0.009	26.58	37.56	0.012

RESULTS

In the study group, 15 patients underwent simultaneous correction of SUI and cystocele using the IVS Tunneler™ 04 and quadra mesh (Covidien). The patients completed LQQ forms before the operation and six months after it. Grade III cystocele was found in 13 patients, with Ba from +1 to +4, and Grade II in 2 patients, with Ba at 0. In the control group, 25 patients had a separate suburethral sling inserted for SUI: 9 transobturator tape (TOT) (Covidien) and 16 MiniArc (AMS). Seventeen had correction of SUI alone, one had laparoscopic sacrocolpopexy with TOT, two had additional posterior vaginal repair with mesh, and four had anterior and posterior vaginal repair with meshes (Endofast, IBI) and separate TOT. Mean age for the study group was 61.5 (range 38-82) and for the control group 55.4 (range 31-84). In the study group, at the 6-month follow-up anatomical correction was excellent for all 15 patients, with Ba at -3 for 12 patients, at -2 for two patients, and at -1, non-symptomatic, for one patient. The functional results at 6 months are presented in Figure 3. The success rate of the SUI treatment at the 6-month follow-up was 93% for the study group and 84% for the control group. Postoperative success rate was determined by a negative cough stress test with full bladder. In the study group, 5 of 15 patients had mixed urinary incontinence associated with urgency before the operation. All 5 were cured by the operation. There was one patient with de novo urgency after the operation, which was resolved after treatment with antimuscarinic medication. Nine patients had voiding dysfunction (VD) associated to the cystocele before the operation. They were all cured after the operation. One patient had de novo VD after the operation, which was resolved spontaneously after ten days. No signs of unstable bladder or persistent VD were detected. All patients completed the PDFI-20 and PFIQ-7 forms for prolapse, urinary, and colorecto-anal symptoms. Significant improvement in mean total score and urinary score was detected in both groups on both questionnaires (Table 1). There was no difference between the groups when comparing the total or the urinary score before and after the operation (p values range between 0.12-0.8, CI 95%). PFIQ-7 scores were found to correlate more with the clinical interview than did PDFI-20

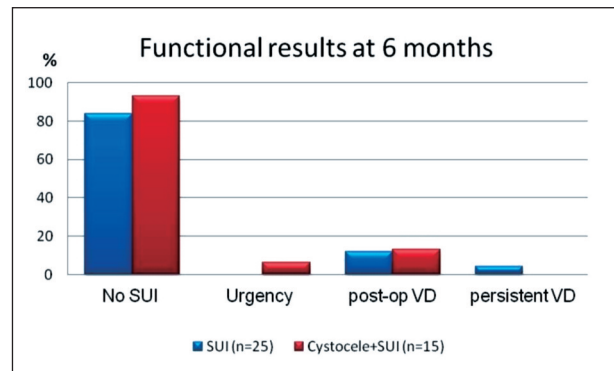


Figure 3. – Functional results 6 months after the operation for study and control groups.

scores. The sexual function questionnaire, PISQ-12, was relevant for 10 of the 15 participants in the study group and for 11 of 25 participants in the control group. Sexual function improved in both groups but was significant only in the study group.

## DISCUSSION

SUI (obvious or occult) and cystocele are often present together and can exist simultaneously, but SUI can also appear de novo after correction of cystocele. In the CARE study, a prophylactic Burch colposuspension at the time of abdominosacrocolpopexy (ASC) reduced significantly the rate of de novo SUI.<sup>7</sup> However, in the CARE study patients were not checked for occult SUI pre-operatively, which can explain the high rate of de novo SUI in the control group. When the two conditions coexist, involving either obvious or occult SUI, some surgeons prefer to correct only the cystocele, without additional correction for SUI. This approach is based on several observations showing that correction of cystocele alone, mainly using a transobturator mesh, can cure the SUI in up to 75% of cases.<sup>8-11</sup> In the presence of pre-operative SUI, there is a good chance that following this approach the patient will still require a second operation for SUI.

Correction of cystocele and SUI in the same operation can be performed in two ways: addition of a suburethral sling to the cystocele repair (with or without mesh) or correction of the cystocele with the four arms transobturator mesh and insertion of the upper arms as in the case of the insertion of the midurethral sling described here. Our earlier results with that latter technique have shown an almost 88% cure rate for SUI, although the results were obtained with a retrospective series.<sup>6</sup> When correcting both conditions in the same operation, the SUI cure rate is not the only parameter of interest; voiding dysfunction (VD) and de novo urgency symptoms are of major concern. VD is a common complication after incontinence and anterior prolapse repair. The rate of postoperative VD varies in different series and depends on the procedures used and on the definition of VD.<sup>12,13</sup> The addition of a suburethral sling in prolapse surgery has not been found to increase the risk of VD.<sup>14</sup> De novo urgency symptoms can occur after suburethral sling procedures or prolapse repair<sup>15,16</sup> and greatly affect women's quality of life.<sup>17</sup> Our special technique for performing both corrections, grading the pubococcygeous muscle and preventing direct contact with the bladder trigon, can theoretically prevent the appearance of de novo urgency symptoms caused by unstable bladder. Our results from the current study have confirmed what we had observed during routine follow-up: a high cure rate for both cystocele and SUI, without causing unstable bladder or VD. Indeed, the SUI cure rate in the study group was higher than in the control group, implying that correction of both conditions with one mesh may provide better anatomical correction and better results.

Improvement in the quality of life is difficult to assess after prolapse and incontinence surgery mainly because of the complexity of the symptoms. Improvement in anatomical results does not necessarily indicate improvement in functional results. Occasionally, even sub-optimal anatomical results can result in great relief for the patient. The symptoms that are frequently associated with POP can affect the quality of life of women in different ways. In assessing women's pelvic floor, it is of great important to use LQQs addition to interrogation and clinical examination. Asking patients repeatedly about their symptoms may result in a bias, whereas LQQs are designed to circumvent such biases. Moreover, the quality of life reflected in the LQQ may be quite different from that which transpires

from the clinical interview. In 2001, two condition-specific LQQs were developed for women with various forms of pelvic floor disorders, the Pelvic Floor Distress Inventory (PFDI) and the Pelvic Floor Impact Questionnaire (PFIQ). Clinicians and researchers use PFDI and PFIQ together to measure the extent to which lower urinary tract, lower gastrointestinal tract, and pelvic organ prolapse symptoms affect the quality of life of women who suffer from disorders of the pelvic floor. Each LQQ has been shown to be psychometrically valid and reliable.<sup>18,19</sup> In 2003 PISQ-12 was published. The questionnaire is used to evaluate sexual function in women with pelvic organ prolapse and/or urinary incontinence.<sup>20</sup>

The results of the present study demonstrate improvement in quality of life assessed by specific LQQs for POP and incontinence. The mean general score and the urinary symptoms score improved in both groups after the operation, without difference between the groups. We have found that PFIQ-7 correlated more with the clinical interview at follow-up than did PFDI-20. The difference can be explained by the nature of the questions in the two questionnaires.

One of the limitations of the current study has to do with the fact that the control group was heterogenic, with few patients treated also for prolapse and not only for SUI. Four patients underwent correction of cystocele using another system (Endofast, IBI) in which it is not possible to correct both the cystocele and the SUI with the same mesh. These patients were treated with a separate suburethral sling and were enrolled in the control group. In the control group we used TOT and MiniArc for the treatment of SUI. Several randomized studies have demonstrated the equivalence of MiniArc to transobturator types.<sup>21-23</sup> Therefore we enrolled the patients treated with various types of suburethral slings in one group. In the present study we used the IVS Tunneler™ 04 with quadra mesh (Polypropylene Monofilament Mesh, Covidien), which was out of the market at the end of 2010. Although this particular kit no longer exists, the concept of a transobturator mesh with 4 arms, the upper arms of which can be placed under the midurethra as a suburethral sling, remains.

This prospective study was designed to determine whether the simultaneous repair of cystocele and SUI with a cystocele mesh is equivalent to treatment of SUI alone as far as the results of the SUI treatment are concerned, and whether it can cause more bladder instability or voiding difficulties. Our results have demonstrated that in the combined procedure the success rates were even higher than in the case of treatment of SUI alone, without causing more bladder instability or voiding dysfunction. LQQ scores improved in all areas, including sexual function.

We conclude that SUI accompanied by cystocele can be treated in one operation with the same transobturator mesh, ensuring both anatomical and functional cure as well as improvement in the patient's quality of life.

## REFERENCE

1. Brubaker L, Cundiff GW, Fine P, et al; Pelvic Floor Disorders Network. Abdominal sacrocolpopexy with Burch colposuspension to reduce urinary stress incontinence. *N Engl J Med.* 2006; 354:1557-66.
2. Burgio KL, Nygaard IE, Richter HE, et al; Pelvic Floor Disorders Network. Bladder symptoms one year after abdominal sacrocolpopexy with and without Burch colposuspension in women without preoperative stress incontinence symptoms. *Am J Obstet Gynecol.* 2007; 197:647.e1-6.
3. Costantini E, Zucchi A, Giannantoni A, Mearini L, Bini V, Porena M. Must colposuspension be associated with

- sacropexy to prevent postoperative urinary incontinence? *Eur Urol* 2007; 51:788-94.
4. Sergent F, Sentilhes L, Resch B, Diguët A, Verspyck E, Marpeau L. Prosthetic repair of genito-urinary prolapses by the transobturator infracoccygeal hammock technique: medium-term results. *J Gynecol Obstet Biol Reprod (Paris)*. 2007; 36:459-67.
  5. Sentilhes L, Sergent F, Resch B, Verspyck E, Descamps P, Marpeau L. Midterm follow-up of high-grade genital prolapse repair by the trans-obturator and infracoccygeal hammock procedure after hysterectomy. *Eur Urol*. 2007; 51:1065-72.
  6. Eboue C, Marcus-Braun N, von Theobald P. Cystocele repair by Transobturator four arms mesh: monocentric experience of first 123 patients. *Int Urogynecol J*. 2010; 21:85-93.
  7. Brubaker L, Cundiff GW, Fine P, et al; Abdominal sacrocolpopexy with Burch colposuspension to reduce urinary stress incontinence. *N Engl J Med* 2006; 354:1557-1566.
  8. Nauth MA, Fünfgeld C. Correction of cystocele and stress incontinence with anterior transobturator mesh. *Eur J Obstet Gynecol Reprod Biol*. 2008; 136:249-53.
  9. Sergent F, Gay-Crosier G, Bisson V, Resch B, Verspyck E, Marpeau L. Ineffectiveness of associating a suburethral tape to a transobturator mesh for cystocele correction on concomitant stress urinary incontinence. *Urology*. 2009; 74:765-70.
  10. Sergent F, Sentilhes L, Resch B, Verspyck E, Medeiros R, Descamps P, Marpeau L. Treatment of concomitant prolapse and stress urinary incontinence via a transobturator subvesical mesh without independent suburethral tape. *Acta Obstet Gynecol Scand*. 2010; 89:223-9.
  11. Shek KL, Rane A, Goh J, Dietz HP. Stress urinary incontinence after transobturator mesh for cystocele repair. *Int Urogynecol J*. 2009; 20:421-5.
  12. Dawson T, Lawton V, Adams E, Richmond D. Factors predictive of post-TVT voiding dysfunction. *Int Urogynecol J*. 2007; 18:1297-302.
  13. Duckett JR, Patil A, Papanikolaou NS. Predicting early voiding dysfunction after tension-free vaginal tape. *Journal of Obstetrics and Gynaecology*. 2008; 28:89-92.
  14. Sokol AI, Jelovsek JE, Walters MD, Paraiso MF, Barber MD. Incidence and predictors of prolonged urinary retention after TVT with and without concurrent prolapse surgery. *Am J Obstet Gynecol*. 2005; 192:1537-43.
  15. Kershner RT, Appell RA. De novo urge syndrome and detrusor instability after anti-incontinence surgery: current concepts, evaluation, and treatment. *Curr Urol Rep*. 2002; 3:345-53.
  16. Lee JK, Dwyer PL, Rosamilia A, Lim YN, Polyakov A, Stav K. Which women develop urgency or urgency urinary incontinence following midurethral slings? *Int Urogynecol J*. 2013; 24:47-54.
  17. Mahajan ST, Elkadry EA, Kenton KS, Shott S, Brubaker L. Patient-centered surgical outcomes: the impact of goal achievement and urge incontinence on patient satisfaction one year after surgery. *Am J Obstet Gynecol*. 2006;194:722-728
  18. Barber MD, Kuchibhatla MN, Pieper CF, Bump RC. Psychometric evaluation of 2 comprehensive condition-specific quality of life instruments for women with pelvic floor disorders. *Am J Obstet Gynecol* 2001;185:1388-95
  19. Barber MD, Walters MD, Bump RC. Short forms of two condition-specific quality-of-life questionnaires for women with pelvic floor disorders (PFDI-20 and PFIQ-7). *Am J Obstet Gynecol* 2005; 193:103-13.
  20. Rogers RG, Coates KW, Kammerer-Doak D, Khalsa S, Qualls C. A short form of the Pelvic Organ Prolapse/Urinary Incontinence Sexual Questionnaire (PISQ-12). *Int Urogynecol J*. 2003; 14:164-8.
  21. De Ridder D, Berkens J, Deprest J, Verguts J, Ost D, Hamid D, Van der Aa F. Single incision mini-sling versus a transobutator sling: a comparative study on MiniArc and Monarc slings. *Int Urogynecol J*. 2010; 21:773-8.
  22. Kennelly MJ, Moore R, Nguyen JN, Lukban JC, Siegel S. Prospective evaluation of a single incision sling for stress urinary incontinence. *J Urol*. 2010; 184:604-9.
  23. Pickens RB, Klein FA, Mobley JD 3rd, White WM. Single incision mid-urethral sling for treatment of female stress urinary.

*Correspondence to:*

Naama Marcus Braun, Safed – Safed 13000 - Israel  
naama.m@ziv.health.gov.il