

Cardinal ligament: a live anatomical study

FLORIAN WAGENLEHNER¹, PETER PETROS², ALFONS GUNNEMANN³,
PETER A. RICHARDSON⁴, YUKI SEKIGUCHI⁵

¹ Clinic for Urology, Pediatric Urology and Andrology, Justus-Liebig-University, Giessen, Germany

² University of NSW Sydney, Australia

³ Clinic for Urology, Klinikum-Lippe Detmold, Germany

⁴ Central Queensland University, Rockhampton, Queensland, Australia

⁵ Yokohama, Motomachi Women's Clinic LUNA, Japan

Abstract: Background: The cardinal ligaments insert onto the anterior surface of cervix and pubocervical fascia. They support the bladder base, preventing cystocele, and are a key support for the uterus, helping to prevent prolapse. Many cadaveric studies doubt the existence of the cardinal ligament. **Objective:** To define the live anatomy of the cardinal ligament (CL). **Patients and Methods:** A live anatomical study during routine surgical dissection involving 3 groups of patients. Group 1: 61 women with cystocele and/or uterine/apical prolapse. Group 2: 30 women with uterine pathology undergoing vaginal hysterectomy. Group 3: 3 women undergoing abdominal hysterectomy. The course of the CLs was assessed during surgery using the Tissue Fixation System (TFS), by rectal palpation under traction, by approximating them medially using Allis forceps to monitor the effect on the cystocele and uterine prolapse. **Results:** The CLs attach onto the anterior surface of the cervix and are laterally displaced in patients with high cystocele. The cardinal ligament is attached to a point 2cm above the ischial spine. Approximation of the laterally displaced CLs ("simulated operation") in the operation room prior to commencing surgery restored a high cystocele, anteverted the uterus, and partially restored a 3rd or 4th degree uterine prolapse. **Conclusions:** As well as inserting into the lateral part of the cervix, the cardinal ligaments also insert into the anterior part of the cervix. This insertion plays a major role in retaining the uterus in an anteverted position, in preventing a high cystocele, and to assist in uterine/apical support.

Key words: Cardinal Ligament; Retroverted Uterus; Uterine Prolapse; High Cystocele; Cervical Ring; Tissue Fixation System.

INTRODUCTION

According to Robert Zacharin, the first usage of the name "cardinal ligaments" was by Kocks in 1880, while its alternative description, "Ligament of Mackenrodt", followed Mackenrodt's 1885 anatomical dissections in the newborn.¹ Mackenrodt described transverse ligaments from the lateral part of the cervix to the pelvic sidewalls. Based on cadaveric and histological studies, the very existence of the cardinal ligament has been questioned. This debate, initiated by Winter in 1896,¹ has continued to the present day.² In line with previous investigators, Kato et al.² demonstrated a structure which corresponded to the cardinal ligament by gross dissection of the paravesical and pararectal spaces. In their histological examination, however, they described the superolateral part of the ligament as a "vague area".

Irrespective of such histological studies, Mengert in 1936³ demonstrated the importance of the parametrial tissues in uterine support by attaching a 1 kg weight to the cervix, and measuring the descent on severing the following ligaments in turn, round, ovarian, uterosacral, upper and lower thirds of the broad ligament.

General and specialized anatomy textbooks invariably show the cardinal ligaments inserting into the lateral part of the cervix. Almost all these anatomical studies have been in fresh or treated cadavers.

Our early experience with the TFS (Tissue Fixation System) minisling operation for correction of high cystoceles and uterine prolapse^{4,5} indicated that the cardinal ligaments are attached to the anterior part of the cervix. Furthermore, whatever the histological evidence for non-existence of these ligaments, we found that antero-lateral suspension was an essential element in the anatomical support of the uterus and bladder.

Our aim was to identify and define the cervical attachments and function of the cardinal ligaments in 3 groups of patients undergoing cystocele repair, vaginal or abdominal hysterectomy.

As this was part of a clinical audit, Ethics Committee approval was not sought. The principles outlined in the Declaration of Helsinki were followed. Written informed consent was obtained from all the study participants.

PATIENTS AND METHODS

The cardinal ligament anatomy was examined in three groups of patients using the Baden Walker classification.

Group 1. Sixty-one patients, underwent cardinal ligament repair using the Tissue Fixation System (TFS) either for 3rd degree cystocele alone (n=10), or as part of a uterine/vaginal prolapse operation (n=51). The cardinal ligament was repaired first, and the change in prolapse noted; following this, the uterosacral ligament was repaired as indicated.^{4,5}

Group 2. Thirty patients with uterine prolapse of varying degrees (1st & 2nd n=27; 3rd & 4th n=3) who had vaginal hysterectomy for uterine pathology. The insertion of the cardinal ligament (CL) onto the anterior part of cervix was examined following separation of the vaginal mucosa.

Group 3. The course of the cardinal ligament to the side wall of the pelvis and the ureter were assessed in 3 patients, who had no prolapse, and who had abdominal hysterectomy for uterine pathology.

Assessment of medial insertions of CL Groups 1 and 2 were assessed for cardinal ligament dislocation from the anterior cervical ring by inspection, contralateral traction on the cervix/vaginal apex during rectal examination, by "simulated operations" whereby the dislocated ends of the cardinal ligaments were approximated, figures 1 and 2, and by surgical dissection.

Assessment of sidewall insertions of CL Rectal examination to assess the lateral insertions of the CL. The cervix was stretched contralaterally. The index finger located the ischial spine, and was then directed 2cm upwards to locate the lateral insertion of the ligament.

"Simulated" (or "virtual") operation A high cystocele (cervical ring/cardinal ligament defect) was differentiated

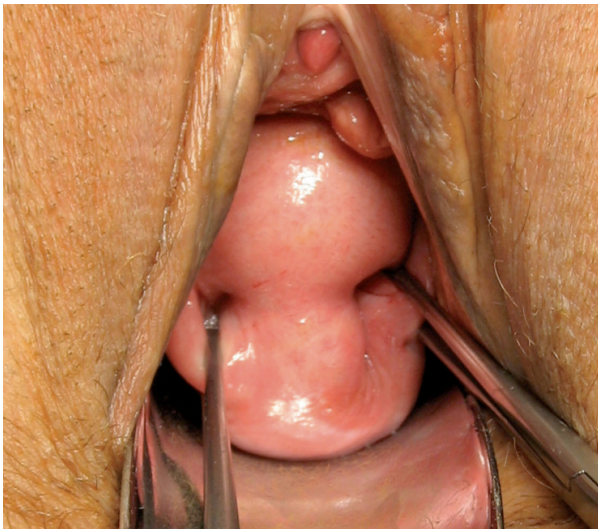


Figure 1. – Diagnosing a cardinal ligament/cervical ring defect. The vaginal tissues prolapsed along the sides of the cervix are grasped approximately 2cm lateral to the cervix, and approximated medially.

from a central or paravaginal cystocele defect using a ‘simulated’ operation in the operation room. The vaginal tissue was grasped laterally in the position of the dislocated cardinal ligaments (usually 2cm lateral to the cervix) and approximated medially, figures 1&2. This manoeuvre will not restore a central cystocele or paravaginal defect, which continues to bulge.

A model of the pelvis with elastic “ligaments” attached to the cervix, figure 3, was used to model how the uterine prolapse altered the insertion angle of the cardinal ligament, an important detail as regards the surgical technique for prolapse.

Surgical technique

During cystocele repair, an inverted “T” incision was made extending from 1cm above the anterior lip of cervix (or hysterectomy scar) to 1cm short of bladder neck. The vagina was dissected off the bladder, and the bladder off the cervix (or anterior vaginal wall in patients with previous hysterectomy). Using Allis forceps, firm tissue was identified laterally, grasped and stretched so as to define its course towards the pelvic sidewall.

In patients undergoing vaginal hysterectomy, the anterior vaginal wall was reflected off the anterior wall of the uterine cervix, and the bladder was dissected off the vagina and uterine cervix so that the attachments of the cardinal ligament to cervix could be inspected and defined.

In the 3 patients undergoing abdominal hysterectomy, the broad ligament was opened out between the round and broad ligaments to identify the ureter, uterine vessels and vein, the cardinal and uterosacral ligaments.

RESULTS

The mean age of the patients was 61 years (33–85); median age was 59 years; mean weight was 63kg (49–102 kg); mean parity was 3 (0–7). The anterior attachment of the cardinal ligaments was most evident in patients undergoing vaginal hysterectomy. In patients with 3rd or 4th degree uterine prolapse, and no cystocele, the cardinal ligament was often intact, but extended (Figure 4).

Group 1. Sixty-one patients underwent cardinal ligament repair using the Tissue Fixation System (TFS) either for 3rd degree cystocele alone (n=10), or as part of repair of uterine prolapse (n=51), 24 of which were 3rd or 4th degree. In

patients with cystocele (n=32), the anterior insertion of the cardinal ligaments was not recognizable, and the ligaments were displaced laterally.

In almost all cases, it was possible to identify and grasp a firm band of tissue, 2cm lateral to the cervix. When this tissue was stretched, it could be felt proceeding 30 degrees inferolaterally in a direction above and forward of the ischial spine, as described by Curtis. In those patients with prolapse and no significant cystocele, (n=29), the prolongation of the cardinal ligament anteriorly was more evident (Figure 3).

Group 2. In the 30 patients who had vaginal hysterectomy for uterine pathology, a clearly fibromuscular structure, the cardinal ligament, was seen ascending onto the anterior part of the cervix, with the uterine artery pedicles below, figure 4. More laterally, the cardinal ligament merged with the uterosacral attachment to the posterior part of the cervix.

Group 3. Three patients had abdominal hysterectomy for uterine pathology. The ureter was situated between 1cm and 2cm lateral to the cervix, passing below the uterine artery, then proceeding in a forwards and upwards direction, well away from the insertion of the cardinal ligament which was directed 30 degrees downwards. When the uterus was stretched contralaterally, a firm structure could be felt below the uterine arteries, proceeding in the direction of the spine. Because of the complexity of structures in the broad ligament, we could not visually identify the lateral insertions of cardinal ligament.

Differentiation of cystocele by inspection. Prolapse of the vaginal epithelium laterally around the cervix is characteristic of a cardinal ligament/cervical ring defect, and reflects the lateral displacement of the ligament, figure 5. A central cystocele, being caused by rupture or thinning of the pubocervical fascia (PCF), has a shiny appearance on examination. A ‘high cystocele’, like a pure lateral defect, frequently has transverse rugae.

“Simulated operation”. We found the “simulated operation”, figures 1 and 2, was an accurate predictor of cardinal ligament defect as a cause of cystocele in the 32 patients with cystocele. The cystocele almost completely disap-

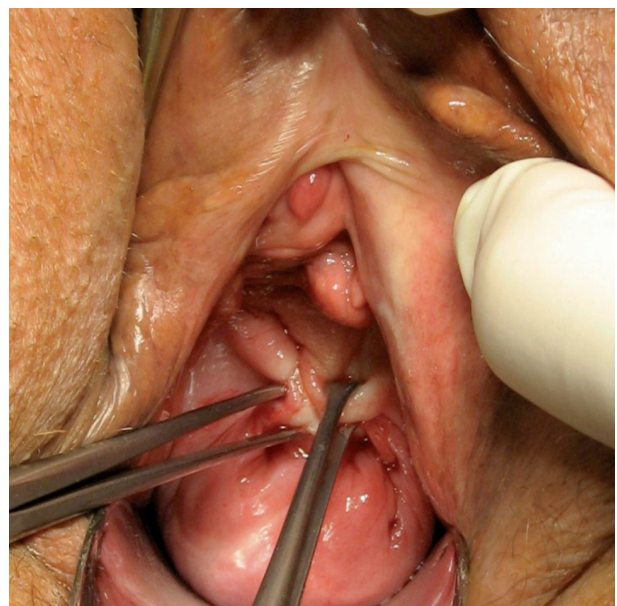


Figure 2. – “Simulated” operation. Disappearance of the cystocele following approximation of the forceps confirms cardinal ligament/cervical ring defect as the cause of the cystocele.

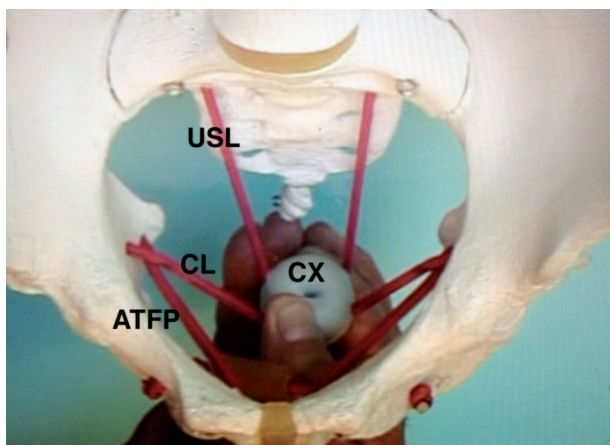


Figure 3. – Modelling uterine prolapse The “Cervix” (CX) has been stretched downwards. Note how both cardinal (CL) and uterosacral ligaments (USL) are stretched downwards. ATFP= arcus tendineus fascia pelvis. A :”simulated operation” brings together the medial parts of the CL, effectively shortening them, bringing CX back into the vagina.

peared on approximation of the cardinal ligaments with Allis forceps in 23 patients. The other 9 patients also had a central/lateral defect, as diagnosed by a persistent anterior bulge.

Rectal examination to assess lateral insertion of the cardinal ligament. When the cervix was stretched contralaterally, the index finger located the ischial spine, and was then directed 2cm upwards. A tense firm structure could be followed towards the bony side wall and cervix.

Pelvic Model. Stretching the model of the cervix downwards beyond the level of the ischial tuberosities elongated

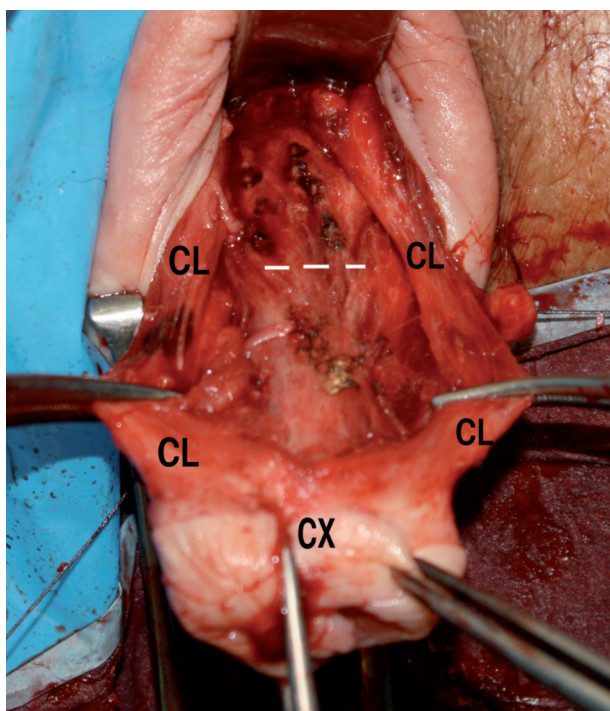


Figure 4. – Pathologically stretched Cardinal Ligaments (CL) attaching to the anterior part of cervix (CX) in a patient with 4th degree uterine prolapse. The vagina has been dissected away from the anterior part of an elongated cervix. The level of the endocervix is indicated by white broken lines. The cardinal ligament has been stretched laterally with forceps.

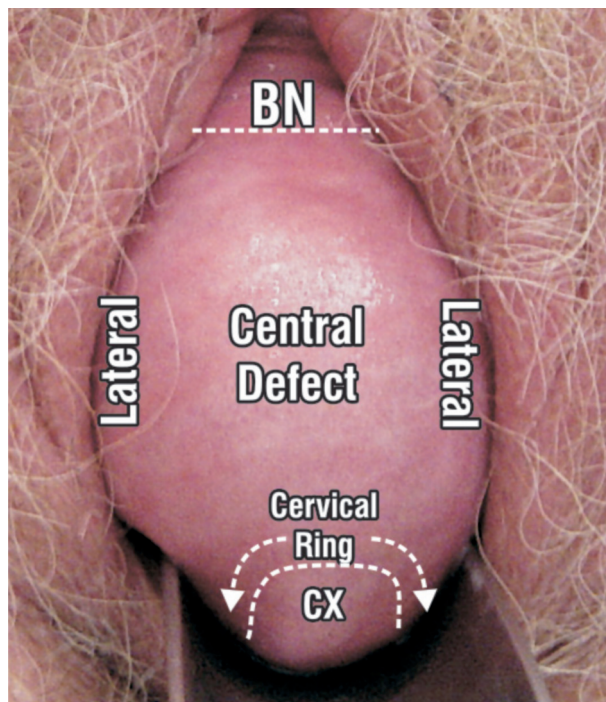


Figure 5. – Prolapse, 3rd degree, of bladder and uterus. A large central defect extends laterally. Prolapse of bladder around cervix (CX) (curved arrows) is characteristic of CL/cervical ring defect. The central defect remained after the Allis forceps test (see figures 1&2). BN=bladder neck.

both cardinal and uterosacral ligaments, indicating that both are important elements for uterine support, figure 3. On pressing down on an inflated balloon, the cardinal and ATFP ligaments became distorted, indicating that both are important supporting structures of the pubocervical fascia, and therefore, bladder base.

The simulated surgical operations performed using the model indicated how shortening and strengthening the elongated ligaments, anteverted the uterus, strengthened the pubocervical fascial supports, and restored the cervix to its correct anatomical position.

DISCUSSION

Our study, carried out in live patients as part of normal surgical dissection, demonstrated that the cardinal ligaments were attached to the cervix anteriorly, but not in all patients, in particular, those presenting with cystocele.

The key to deeply understanding the structure and function of the cardinal ligaments was the “simulated operation” technique, which reduced a high cystocele, and uterine prolapse. Per rectum palpation of the cardinal ligament while stretching of the tissues, and direct identification during surgery provided further insights. (see earlier website references).

We found that a torn or displaced cardinal ligament was a significant cause of high cystocele, uterine retroversion, and uterine prolapse, as detailed in figure 6. Essential to this pathogenesis is the anterior insertion of both cardinal ligaments. Standard anatomical textbooks invariably show attachment of the cardinal ligaments to the lateral side of the cervix, rather than its anterior part. Based on cadaveric histology, Buller et al,⁶ described fibres spreading anteriorly in their study of the uterosacral ligaments, but do not mention insertion of cardinal ligaments onto the anterior part of the cervix. In his drawings, Curtis⁷ (1942) clearly shows a fascial envelope attaching anteriorly and posteriorly into what

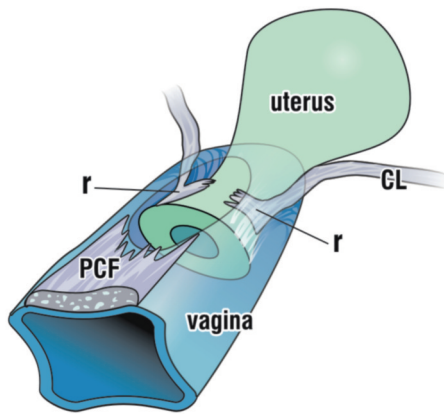


Figure 6. – Dislocation of the cardinal ligaments from their insertion into the anterior part of the cervical ring allows the uterine body to retrovert. At the same time, the insertion of the musculoelastic fascial layer of the vagina tears, allowing prolapse of the bladder (high cystocele).

appears to be a circular cervical ring attached to the vagina. However, no special function was assigned by Curtis to this anatomical relationship. Curtis considered that the endopelvic fascia is defined as a ridge which sweeps forward from the region of the spine of the ischium and obturator muscle dividing into an inferior fascial arch, the white line, and the somewhat superiorly placed slightly curved arcuate (cardinal) ligament. He stated that there was a double layer of fascia between adjacent organs. Each fascial envelope is in intimate relationship with the musculature of the corresponding viscus, receiving muscle fibres from it.

Mengert's serial transections of adjacent structures underlined their importance in maintaining the position of the uterus. Yet, on histology, there is a well-established paucity of a definitive cardinal ligament structure. Zacharin,¹ Curtis,⁷ Kato,² and others, discuss the importance of the connective tissue surrounding blood vessels as an important structural component.

Perhaps the answer to this anatomical dilemma lies in the physical characteristics of Collagen 1. In bundles, Collagen I has a breaking strength of 18,000 lbs /square inch or 1300 Kg/q cm.⁸ Therefore very little collagen is required to support a uterus weighing a few hundred grams.

From a structural perspective, the debate on whether or not a cardinal ligament really exists is not really relevant. From a practical reconstructive surgical perspective, we have found that a broken or stretched insertion of cardinal ligament to the cardinal/cervical ring complex, figure 6, may result in bladder base descent (high cystocele), uterine retroversion, and a varying degree of uterine descent. It is evident on examination of figure 4 that a tensioned tape will shorten the cardinal ligaments, "reglue" the pubocervical fascia and cardinal ligaments to the anterior cervical ring, restore the uterine axis to an anteverted position, and partially restore uterine prolapse. These surgical principles are similar to those described in 1907 by Fothergill in his "Manchester Repair" operation.¹⁰ The main difference is that Fothergill was attaching weakened ligaments to weakened ligaments, whereas use of the tape creates a permanent collagenous neoligament.

It is clear from figures 3 and 7, however, that the major supports for the uterus are the uterosacral ligaments. The cardinal ligament does, however, have an important subsidiary supporting role.

CONCLUSIONS

Contrary to accepted thought, the cardinal ligament inserts into the anterior part of the cervix. It plays a major ro-

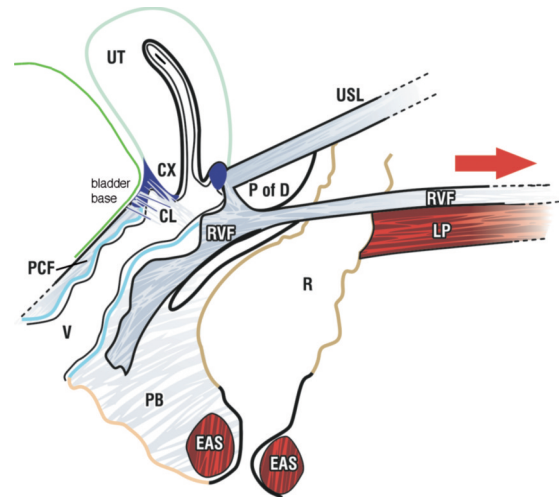


Figure 7. – The principal supporting elements of the uterus are the uterosacral ligaments (USL) rectovaginal fascia (RVF) which attaches to the levator plate muscle (LP), a posterior vector which tenses the rectum (R) and uterus backwards. Clearly the cardinal ligament (CL) has only a subsidiary role. It is also clear that dislocation of CL and pubocervical fascia (PCF) from cervix (CX) will result in rotation downwards of bladder base into vagina (high cystocele).

le in retaining the uterus in an anteverted position, a major role in retaining the bladder and preventing cystocele, and a variable, but important role in uterine support.

REFERENCES

1. Zacharin RF. Anatomy, In: Zacharin RF, Pelvic floor anatomy and cure of pulsion enterocoele, Springer-Verlag, Wien, 1985; 18-31.
2. Kato T, Murakami G, Yabuki Y Does the cardinal ligament of the uterus contain a nerve that should be preserved in radical hysterectomy. *Anat Sci Int* 77 2002; 161-8.
3. Mengert WF. Mechanics of uterine support and position. *Am J Obstet Gynecol.* 1936; 31; 775-782.
4. Petros PEP, Richardson PA, Goeschel K and Abendstein B, The Tissue Fixation System (TFS) provides a new structural method for cystocele repair- a preliminary report. *ANZJOG*, 2006; 46: 474-478.
5. Abendstein B, Petros PE, Richardson PA Ligamentous repair using the Tissue Fixation System confirms a causal link between damaged suspensory ligaments and urinary and fecal incontinence. *J. Pelviperineology*, 2008; 27;114-117.
6. Petros PE Richardson PA "A 3 year follow-up review of uterine/vault prolapse repair using the TFS minisling, *RANZJOG*, 2009; 49;4: 439-440.
7. Buller, J.L., Thompson, J.R., Cundiff, G.W., Sullivan, L.K., Schön Ybarra, M.A., and Bent, A.E. Uterosacral ligament: description of anatomic relationships to optimize surgical safety. *Obstet Gynecol* 2001; 97; 873-79.
8. Curtis HA & Anson BJ. The anatomy of the pelvic and urogenital diaphragms in relation to urethrocele and cystocele. *Surgery Gynecol & Obstets.*, 1942; 74:708-727.
9. Florey H. General Pathology, 1971, 4th Ed, Lloyd Luke London, p. 457.
10. Fothergill WE. Pathology & the operative treatment of displacements of the pelvic viscera. *Journal of Obstets & Gynaecol of the British Empire*, 1907; 13:410-419.

Correspondence to:

FLORIAN WAGENLEHNER
Clinic for Urology, Pediatric Urology and Andrology
Justus-Liebig-University
Giessen, Germany
Phone: +49 64198544516
Email: Wagenlehner@AOL.com

Multidisciplinary Uro-Gyne-Procto Editorial Comment

To improve the integration among the three segments of the pelvic floor, some of the articles published in **Pelvipерineology** are commented on by **Urologists, Gynecologists and Proctologists/Colo Rectal Surgeons** with their critical opinion and a teaching purpose. Differences, similarities and possible relationships between the data presented and what is known in the three fields of competence are stressed, or the absence of any analogy is indicated. The discussion is not a peer review, it concerns concepts, ideas, theories, not the methodology of the presentation.

Uro... In this study the Authors identified and defined the cervical attachment and function of the cardinal ligaments in three groups of patients undergoing cystocele repair, vaginal or abdominal hysterectomy respectively. In particular they conclude, contrary to what was previously thought, that the cardinal ligament inserts into the anterior part of cervix and plays the major role in retaining both the uterus in an antverted position and the bladder, and finally in preventing cystocele. The information obtained from this paper is absolutely important for the surgical correction of cystocele and the correction of uterine prolapse as well. In this context, the Authors' experience with TFS minisling operation in the correction of high cystocele and uterine prolapse is to substantiate the above.^{1,2} The results reported in this manuscript could be the starting point for a new philosophy of approach using this type of minimally invasive surgery even though the role of the cardinal ligament remains controversial and at the same time fascinating both for its function as morphological support of pelvic viscera and for the neurofunctional aspect as reported in the past.³ A study with MRI performed before and after the TFS minisling operation would be extremely interesting to confirm from an anatomical point of view the topographic displacement of the cardinal ligament.

1. Petros PEP et Al. ANZJOG, 46: 474-478, 2006.
2. Abendstein B et Al J Pelvipерineology, 27: 114-117, 2008.
3. Tomoyasu K et Al Jpn J Clin Oncol 33: 589-591, 2003.

SALVATORE SIRACUSANO
Department of Urology Trieste University, Italy
siracus@units.it

Gyne... The paper of Wagenlehner et al. is a brilliant anatomical research on the existence and the physiopathological role of the cardinal ligament. They performed a live on site anatomical study, which oversteps the bounds of both cadaveric studies and live imaging studies. They give us an anatomical picture of pelvic supports in women with and without genital prolapse. In brief, authors compared women undergoing vaginal surgery for uterine/bladder prolapse (group I) and women undergoing vaginal (group II) or abdominal (group III) hysterectomy for uterine pathology, the II group either with or without prolapse. They confirm the role of cardinal ligaments in supporting the uterus – in antverted position – and bladder. This was elicited by the clearest evidence of the fibromuscular structure in patients without prolapse. Conversely, the ligaments were intact but extended in patients with high grades of prolapse and not recognizable in those with cystocele. These findings foster the open debate on cystocele as a consequence of uterine descent. Authors' analysis goes deeper on a biochemical level: the properties of collagen ultra-structure seem

to be the cause of the anatomical finding. The link between the two levels could be a biomechanical study of pelvic support.

In conclusion this work gives a contribution not only in the anatomical debate, but open the doors to further discussions about a defect-tailored surgery for prolapse. In fact, once known the anatomical pattern, the surgical aspect should be analyzed in order to assess the best management of our patients.

STEFANO MANODORO
Obstetrics and Gynecology Department,
San Gerardo Hospital, Monza, Italy, University of Milano-Bicocca
stefano.manodoro@gmail.com

Procto... The article by Wagenlehner et al. is interesting and intriguing for proctologists. The Authors have shown that the cardinal ligaments as well as inserting into the lateral part of the cervix, also insert into its anterior part. They suggest that a torn or displaced cardinal ligament may be a significant cause of high cystocele, uterine retroversion and uterine prolapse, whereas surgical correction of the ligaments restores the cervix to its correct anatomic position. Cardinal ligaments therefore are anatomical cornerstones to the prevention of pelvic organ prolapse.

The importance of uterine prolapse is well known to proctologists. Rectoanal intussusception is present in 40.3% of women affected by uterine prolapse and concurrent descending perineum syndrome. These women have a positive correlation between the severity of fecal incontinence (Jorge score) and the degree of genital relaxation, and this is most probably indicative of a link between pelvic organ prolapse and anorectal dysfunction. 1 Finally, both pelvic organ prolapse and anorectal dysfunction are influenced by the damage of the connective tissue and this can be proven by the evidence that repair of damaged ligaments cures idiopathic fecal incontinence.² Therefore knowledge of the role of cardinal ligaments in assisting uterine/apical support becomes determinant in understanding how the loss of the integrity of the pelvic fascia may interfere with anorectal dysfunction. Useful suggestions might be provided for the performance of laparoscopic ventral rectocolpopexy.

1. Pucciani F, Boni D, Perna F, Bassotti G, Bellini M. Descending perineum syndrome: are abdominal hysterectomy and bowel habits linked? *Dis Colon Rectum* 2005; 48: 2094-99.
2. Petros PE. The female pelvic floor function, dysfunction and management according to the integral theory. Heidelberg: Springer, 2004:180-90.

FILIPPO PUCCIANI
Department of Surgery and Translational Medicine,
University of Florence, Italy