

# An anatomical basis for vaginal remodelling without excision of vaginal tissue

PETER PETROS

UNSW Academic Dept of Surgery, St Vincent's Hospital Clinical School, Sydney, Australia

**Abstract:** The vagina is an elastic tube which is stretched around the penis by 3 directional muscle forces in the manner of an elastic glove. These are reflex contractions and no learning is required. In contrast, narrowing the vagina by “squeezing upwards” is a learnt activity activated by voluntary contraction of the puborectalis muscle (PRM) which functions normally even with a loose vagina. The 3 striated muscle forces require adequate insertion points into the pubourethral (PUL) / uterosacral (USL) ligaments and perineal body (PB) in order to function properly. Loose suspensory ligaments/perineal body may result in the sexual partner feeling a “looseness” on entering the vagina. Based on this anatomy, the keys to vaginal remodelling are repair of the suspensory ligaments (to restore muscle force) and conservation of vagina (to preserve elasticity). Restoration of PUL/USL and PB restores the 3 directional muscle forces which contract to reflexly narrow the vagina.

**Key words:** Vaginal remodelling; Pubourethral ligament; Puborectalis; Uterosacral ligament; Sexual function.

## INTRODUCTION

The core element of my thesis is based on the Integral Theory:<sup>1</sup> the vagina is an elastic tube which is stretched around the penis by directional muscle forces in the manner of an elastic glove. These striated muscle forces require adequate insertion points into the suspensory ligaments and perineal body in order to function properly. Loose suspensory ligaments/perineal body may result in the sexual partner feeling a “looseness” as he enters the vagina.

The keys to vaginal remodelling, as I see it, are

1. Repair of the suspensory ligaments (to restore muscle force)
2. Conservation of vagina (to preserve elasticity)

The penis enters the vagina and sets off an involuntary reflex which causes contraction of 3 striated muscles. The forward vector is m. pubococcygeus (PCM). The posterior vectors are m. conjoint longitudinal muscle of the anus (LMA) and m. levator plate (LP). In the context of intercourse, LP stretches the posterior vaginal wall against perineal body (PB), and the anterior vaginal wall against PUL (Figure 1). LMA pulls against the utero-sacral ligaments “USL”. These stretch the vagina backwards/downwards to grasp the penis like a glove. These striated muscles cannot function adequately if their suspensory ligaments, PUL and USL are weak or over-extended.

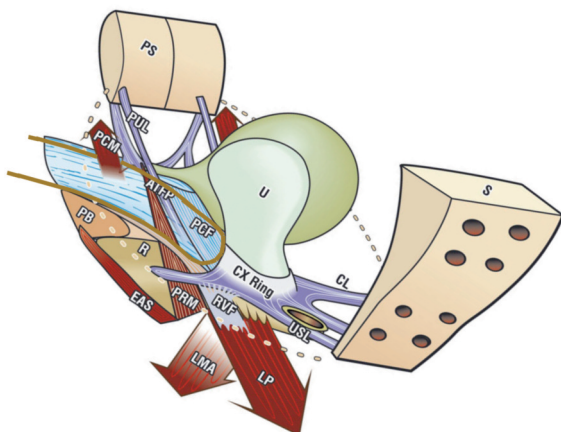


Figure 1. – What happens during intercourse in the normal woman.

## RADIOLOGICAL PROOF OF THE THREE MUSCLE VECTORS

The pelvic muscles contract against the suspensory ligaments PUL and USL to stretch the vagina backwards and downwards to narrow the vagina and constrict the penis. The downward movement creates a rhythmic “pulling” sensation on the penis.

Urine loss during intercourse is a related manifestation. My experience over many years indicates that the principal anatomical defect is laxity in the pubourethral ligament (Figure 1). Cure is simple: insert a midurethral (preferably retropubic) sling.<sup>2,3</sup>

## ROLE OF PUBORECTALIS

Voluntary contraction during intercourse\* is activated by voluntary contraction of m. puborectalis (Figure 5).<sup>2,3</sup> This is quite different from the reflex contraction occurring during exercise, straining, intercourse and other activities which activate the 3 directional muscle forces (Figures 2 and 3). *This action does not depend on intact suspensory ligaments and is an excellent technique for women who have a lax vagina.*

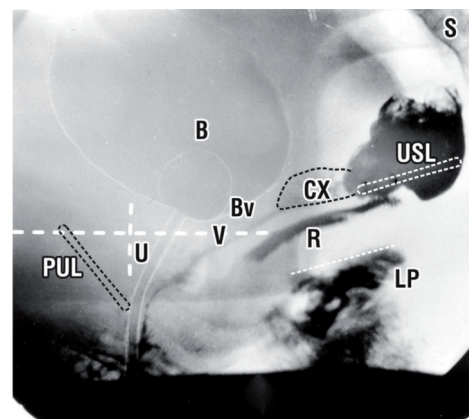


Figure 2. – Resting x-ray. The vagina ‘V’, rectum ‘R’, urethra ‘U’ are stretched backwards by slow-twitch muscle fibres. The gentle downward displacement of the upper border of levator plate (LP) (broken lines) is by the slow-twitch muscle fibres of the conjoint longitudinal muscle of the anus (LMA).

\* “The Shanghai Clip” of Wallis Simpson, Duchess of Windsor. This was an infamous false assertion propagated by certain members of the British Aristocracy. The rumour was that while in Shanghai during her 1st marriage to an American servicemen, she visited a Shanghai brothel and learnt how to voluntarily contract her pelvic floor muscles to narrow her vagina.

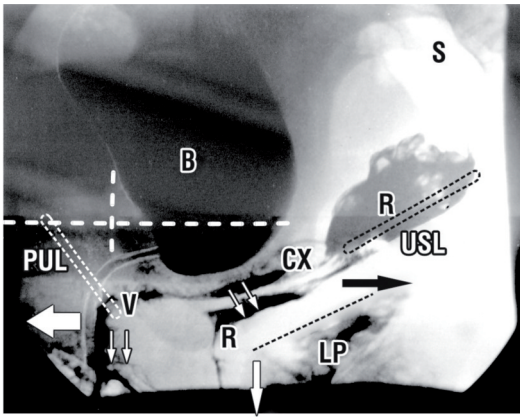


Figure 3. – Straining x-ray. Any stimulus (straining, coughing, intercourse) which stimulates fast-twitch muscle contractions stretch the vagina and rectum backwards and downwards by 3 directional muscle forces acting against PUL and USL. This action narrows the vagina and grasps the penis tightly.

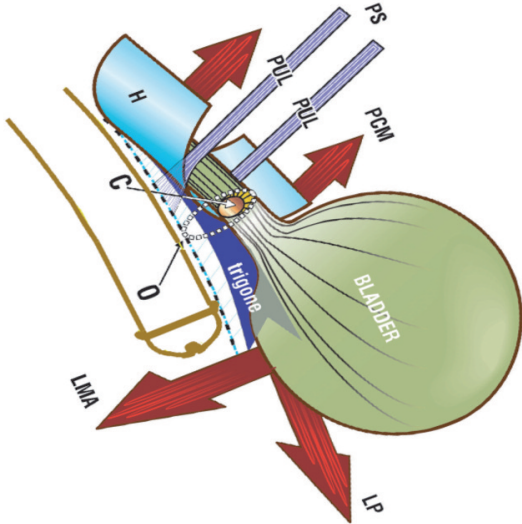


Figure 4. – Mechanism for urine loss during intercourse. The penis stretches the vagina downwards and opens out the posterior urethral wall. If the pubourethral ligament (PUL) is weak or over-extended, the forward vector, m. pubococcygeus (PCM) cannot function. The posterior vectors m. conjoint longitudinal muscle of the anus (LMA) and m. levator plate (LP) stretch the vagina backwards/downwards to open out the posterior wall of the urethra.

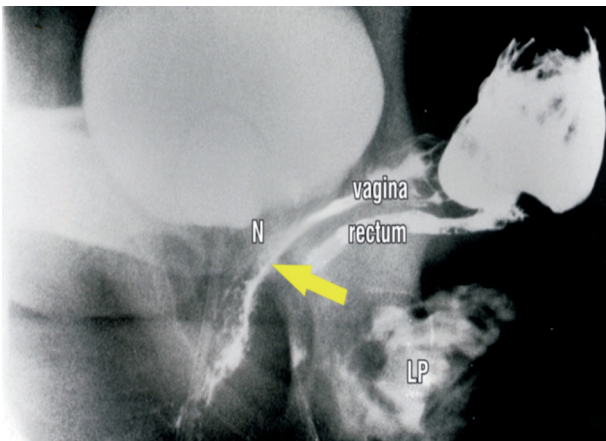


Figure 5. – Voluntary contraction of m. puborectalis during intercourse. The same patient as Figures 2&3. This elevates and narrows the rectum and vagina (forward arrow).

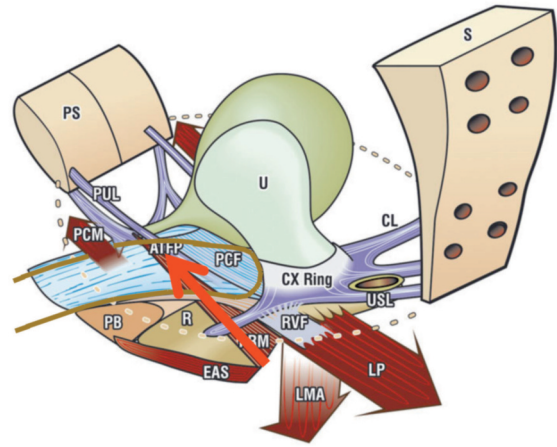


Figure 6. – Forward contraction of m. puborectalis ‘PRM’ against the pubic symphysis (PS).

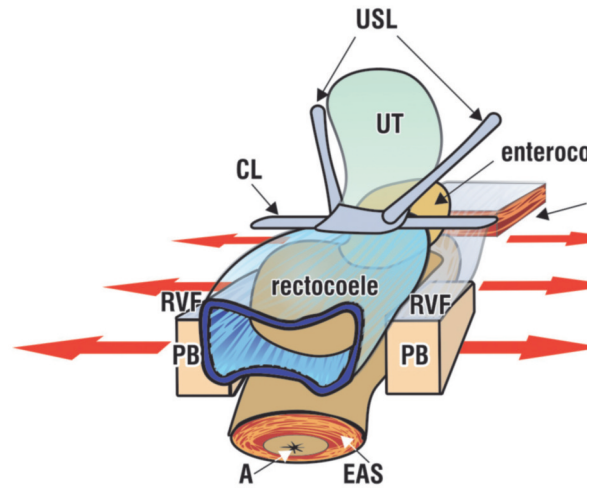


Figure 7. – Role of perineal body. If the two perineal bodies (PB) are separated, the rectovaginal fascia (RVF) is ruptured or over-extended, so that LP cannot stretch the vaginal wall backwards to ‘grip’ the penis.

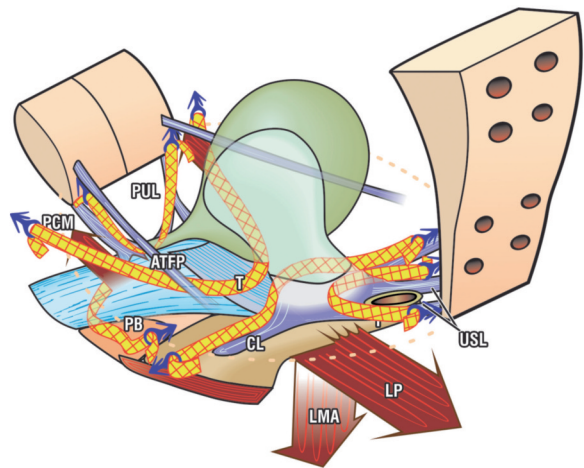


Figure 8. – Surgical treatment. Site specific reinforcement of damaged ligaments/perineal body 3D view of the pelvic cavity from above and behind. The 11x4 mm blue anchors are placed in the precise position of 4 suspensory ligaments, pubourethral (PUL), ATFP, cardinal (CL) uterosacral (USL) and perineal body (PB). At the base of the anchor is a one-way tensioning system which simultaneously shortens and reinforces the damaged ligaments. At the same time, the musculo elastic layer of the vagina- also known as ‘pubocervical’ and rectovaginal’ fascia- which has been split and laterally displaced is brought back into the midline.

#### ROLE OF THE PERINEAL BODY

The perineal body, "PB" (Figure 7) supports 50% of the posterior vaginal wall.<sup>4</sup> Birth-related trauma pushes the two perineal bodies laterally, allowing the anterior rectal wall to protrude as a rectocele. If the trauma occurs along the whole length of the posterior vaginal wall, the uterosacral ligaments are laterally displaced at the upper end, the musculo-elastic layer of the vagina (rectovaginal fascia "RVF") is split and is displaced laterally, Figure 7. The inferior attachment point of RVF (Figure 6) is ruptured and this prevents LP from stretching the vagina around the penis during intercourse.

#### SURGICAL TREATMENT

The aim is to restore the muscle forces which stretch the vagina backwards to "grip" the penis.

1. Reinforce the damaged ligaments, PUL and USL with precisely inserted tapes. This provides a firm insertion point for the directional muscle forces.
2. Bring together the laterally displaced musculo-elastic layers of the vaginal wall.

The TFS tensioned minisling (Figure 8), is the only instrument which can accurately accomplish this task.<sup>5,6,7</sup>

#### REFERENCES

1. Petros PE & Ulmsten U. An Integral Theory and its Method, for the Diagnosis and Management of female urinary incontinence, Scandinavian Journal of Urology and Nephrology 1993;153: 1-93.

2. Petros PE and Ulmsten U. Role of the pelvic floor in bladder neck opening and closure: I muscle forces. Int J Urogynecol and Pelvic Floor 1997; 18: 74-80.
3. Petros PE and Ulmsten U. Role of the pelvic floor in bladder neck opening and closure: II vagina. Int J Urogynecol and Pelvic Floor 1997; 18: 69-73.
4. Abendstein B, Petros PE, Richardson PA, Goeschen K, Doder D. The surgical anatomy of rectocele and anterior rectal wall intussusception, Int Urogynecol J 2008; 5: 513-7.
5. Petros PE, Richardson PA. The midurethral TFS sling- a 'micro-method' for cure of stress incontinence- preliminary report ANZJOG, 2005; 45: 372-375.
6. Petros PE, Richardson PA. The TFS posterior sling for repair of uterine/vault prolapse-a preliminary report ANZJOG, 2005; 45: 376-379.
7. Petros PE, Richardson PA, Goeschen K and Abendstein B. The Tissue Fixation System (TFS) provides a new structural method for cystocele repair- a preliminary report. ANZJOG, 2006 46:474-478.

---

#### Correspondence to:

Professor PETER PETROS  
DSc DS (UWA) MB BS MD (Syd) PhD (Uppsala),  
FRCOG (London) FRANZCOG CU  
UNSW Academic Dept of Surgery,  
St Vincent's Hospital Clinical School,  
Sydney, Australia  
e-mail: pp@kvinno.com