

Interstitial cystitis (painful bladder syndrome) may, in some cases, be a referred pain from the uterosacral ligaments

PETER PETROS

University of Western Australia

Abstract: **OBJECTIVE:** To directly test the hypothesis that painful bladder syndrome/interstitial cystitis may be a referred pain from the uterosacral ligaments. **BACKGROUND TO THE STUDY:** Previous studies have demonstrated high statistical relationships between painful bladder syndrome/interstitial cystitis, and symptoms such as low abdominal pain, dyspareunia, nocturia, urgency, abnormal bladder emptying. These symptoms first described as part of the “posterior fornix syndrome” in 1993, are potentially curable by surgical reinforcement of the uterosacral ligaments. **METHODS:** Five ml of xylocaine 1% local anesthetic solution were injected just lateral to the position of the uterosacral ligaments of 3 patients with symptoms of painful bladder syndrome/interstitial cystitis, all of whom had vascular glomerular changes in the bladder wall vessels observed during cystoscopy and bladder distension. All 3 patients also had symptoms of vulvodynia, low abdominal pain, dyspareunia, nocturia, urgency, and abnormal bladder emptying. **RESULTS:** The abdominal, urethral, introital and cervical tenderness and pain which were demonstrated objectively in all 3 patients immediately before the intervention, disappeared entirely, or were substantially improved, within 5 minutes of the injection. **CONCLUSIONS:** Though only 3 patients were tested, the association of painful bladder syndrome/interstitial cystitis vulvodynia, lower abdominal pain, nocturia, urgency and abnormal emptying symptoms suggests a possible link with previous studies, where such symptoms improved following surgical tensioning of the uterosacral ligaments. The hypothesis concerning this group of IC patients awaits this crucial test.

INTRODUCTION

In 1993, as part of the second exposition of the Integral Theory, the “Posterior Fornix Syndrome” was described, an apparently unrelated group of symptoms, comprising urgency, nocturia, abnormal emptying, frequency, low abdominal pain and deep dyspareunia, arising from laxity in the uterosacral ligaments.¹ A high cure rate was obtained in a group of patients with these symptoms by surgically tightening the uterosacral ligaments.¹ These data were subsequently confirmed by use of a posterior polypropylene sling to reinforce the uterosacral ligaments.²⁻⁴ In a group of 67 patients who had a posterior TFS sling operation for the “Posterior Fornix Syndrome”,⁴ the cure rate was as follows, chronic pelvic pain 86% (n=46), nocturia, 83% (n= 47) urge incontinence 78% (n=36), abnormal emptying 73% (n=56). In 2005, local anaesthetic injection into the uterosacral ligaments in 10 consecutive patients caused disappearance of introital hypersensitivity. This indicated that vulvodynia may also be a referred pain from the uterosacral ligaments.⁵ In the late 1990’s 3 patients with posterior fornix symptoms, and also painful bladder syndrome (Interstitial Cystitis, “IC”) reported more than an 80% improvement of these symptoms following posterior ligament reconstruction with polypropylene tapes. Although the results from these three cases were not in themselves sufficient to draw any conclusions, they were instrumental in initiating a survey of known IC cases. With the assistance of Sandy McNicol, secretary of the Canadian Interstitial Cystitis Society, a structured questionnaire was distributed to members. Of 136 questionnaires completed in the year 2000, besides their pelvic pain, 130 women had two or more symptoms such as urgency, nocturia, abnormal emptying consistent with posterior ligamentous laxity,⁶ figure 1. In a recent retrospective study, Butrick et al⁷ described 408 patients with Bladder Pain Syndrome/Interstitial Cystitis which were classified into 4 groups Interstitial Cystitis (n=157), Chronic Pelvic Pain (n=98), Vulvodynia/Dyspareunia (n=40) “Other” (n=113). Similar findings were found in all 4 subgroups: complaints of voiding dysfunction (70%), dyspareunia (54%), mean PUF (pain, urgency, frequency) score of 15.9 +/- 6.4, and a positive potassium sensitivity test in 83%. Urodynamics revealed a maximal urethral pressure of 131 cm of water and an abnormal uroflow in 80%.

In another study⁸ of 231 patients with painful bladder

syndrome/interstitial cystitis, 48% had symptoms and urodynamic evidence of bladder obstruction, as determined by a flow rate <12ml/sec.

All these data were consistent with the Integral Theory’s original hypothesis, that painful bladder syndrome/interstitial cystitis (PBS/IC) may be another manifestation of the posterior fornix syndrome as detailed in the posterior zone, fig. 1.

The aim of this study was to directly test the hypothesized relationship between Interstitial Cystitis and uterosacral ligaments by injecting local anesthetic solution into the nerves adjacent to the uterosacral ligaments in 3 patients with confirmed painful bladder syndrome/interstitial cystitis.

MATERIALS AND METHODS

Three patients were assessed before and after injection of 5ml 1% Xylocaine into the posterior vaginal fornix in the position of each uterosacral ligament. All 3 patients had a history of glomerulation formation observed by cystoscopy during bladder distension. The aim of the intervention, to see if their bladder pain originated from lax uterosacral ligaments, was explained to the patients prior to the injection. It was also carefully explained that the local anaesthetic injection would cause very minimal pain, as the innervation of that part of the vagina was by visceral nerves, which were almost insensitive to needle penetration. A 21 gauge needle was inserted 1.5 cm into the vagina at 4 and 8 o’clock in a position just lateral to the uterosacral ligaments. Two other physicians were present as observers for validation purposes. As this was an established clinical test,⁵ Ethical Committee review was not sought. All patients agreed to the study and to publication of results.

RESULTS

Mrs GP, aged 42 years, para 2, had an 8 year history of chronic bladder and abdominal pain, and dyspareunia. She had typical symptoms of the posterior fornix syndrome, nocturia x2 per night, urgency (but no incontinence) and abnormal bladder emptying. When assessed she was complaining of low abdominal and bladder pain.

On examination she had tenderness in the centre and right hand side of her lower abdomen, extreme sensitivity at the introitus during assessment with a Q-tip, and tenderness on palpating the urethra and also, the cervix. Within 5 minutes of

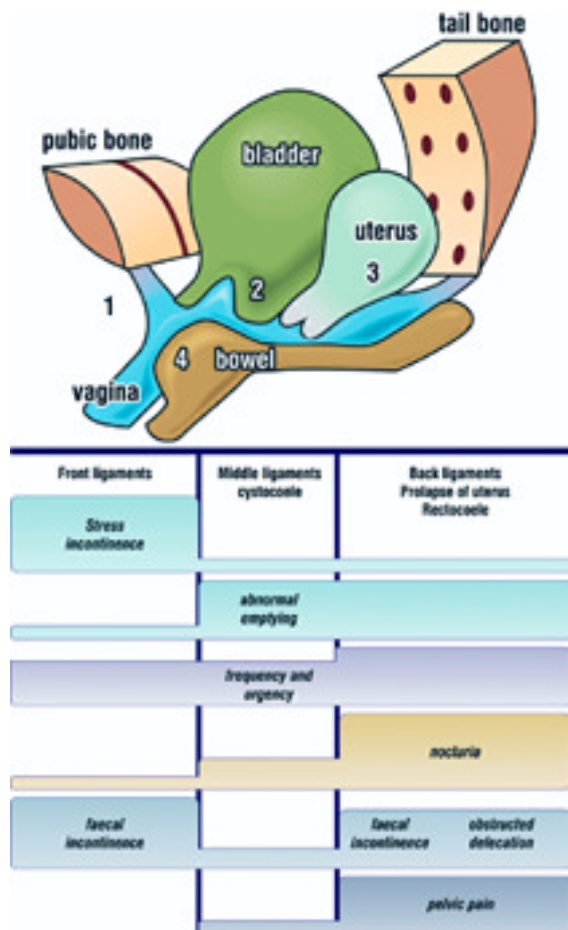


Fig. 1 - Pictorial Diagnostic Algorithm The anterior (pubourethral) and posterior (uterosacral) ligaments are in purple. The middle ligaments (ATFP& cardinal) are not shown in this diagram. There are 3 columns, one for each ligament group and the symptoms and prolapses (lumps) associated with damage to these ligaments. Labelling is 'front' and 'back' instead of 'anterior' and 'posterior'.

the injection, her central pain had moved from a VAS (visual analogue scale) of 8 to 0, and her right-sided pain from a VAS of 9 to 4. Her vulvar hypersensitivity, suburethral tenderness, and cervical excitation pain had all disappeared. There was only 1st degree prolapse on speculum examination, with separation of the uterosacral ligaments.

Mrs AA aged 51 years, para 2, had a 10 year history of chronic bladder pain, left-sided abdominal pain, and dyspareunia. She had typical symptoms of the posterior fornix syndrome, nocturia x3-8 per night, urgency (but no incontinence) and abnormal bladder emptying. On examination she had tenderness on the left side of her lower abdomen, extreme sensitivity on palpating the urethra and the cervix. Within 5 minutes of the injection, her left sided pain had moved from a VAS) of 9 to 0. Her suburethral tenderness, and cervical excitation pain had all disappeared. On speculum examination, there was separation of the uterosacral ligaments, but no obvious uterine prolapse.

Mrs ML aged 40 years, para 2, had undergone a hysterectomy 5 years earlier, and presented with left-sided pain, bladder tenderness, vulvodynia, which had worsened over the past 2 years. She also had nocturia x2 per night, hourly frequency, urgency (but no incontinence). On testing, she had hypersensitivity only on the left side of her introitus, and tenderness over the lower left side of her abdomen and vaginal fornix. Following the local anaesthetic injection, her left-sided pain decreased by an estimated 40% on a VAS scale. The suburethral tenderness, introital sensitivity,

vaginal fornix tenderness found pre-intervention all decreased to zero on a VAS scale.

DISCUSSION

The amelioration of vulvodynia, lower abdominal pain, urethral tenderness, and cervical excitation pain following injection of local anaesthetic into the position of the uterosacral ligaments was emphatic. All 3 patients also had posterior fornix symptoms (fig. 1) nocturia, urgency, abnormal bladder emptying. The association of these posterior fornix symptoms with painful bladder syndrome (Interstitial Cystitis) in these patients and those from other studies^{7,8} support (but do not finally prove) the hypothesis that these separate manifestations of pain may be referred pain from these ligaments.

Another explanation for the disappearance of cervical, bladder and urethral tenderness, is that the nerve block injection into the uterosacral ligaments ligament blocked transmission of pain impulses from these organs. Frankenhauser's plexus located just lateral to the uterosacral ligaments is an important pathway for pain. This explanation cannot account for the disappearance of lower abdominal pain in all 3 patients with the LA injection, nor the cure of chronic lower abdominal and cervical excitation pain following surgical tensioning of lax uterosacral ligaments,¹⁻⁴ which indicate cause and effect. The hypothesis concerning bladder pain causation by lax uterosacral ligaments in this group of IC patients awaits this crucial test.

Acknowledgments

I acknowledge the generous assistance of Professor Mauro Cervigni and Professor Roberto Angioli provided for this study.

REFERENCES

- Petros PE & Ulmsten U. The posterior fornix syndrome: a multiple symptom complex of pelvic pain and abnormal urinary symptoms deriving from laxity in the posterior fornix. Scandinavian Journal of Urology and Nephrology (1993) - Vol 27 Supplement No 153 - PART IV: 89-93.
- Farnsworth BN Posterior Intravaginal Slingplasty (infracoccygeal sacroplexy) for severe posthysterectomy vaginal vault prolapse- a preliminary report, Int J Urogynecol 2002; 13:4-8.
- Abendstein B, Brugger BA, Furtschegger A, Rieger M, Petros PE. Role of the uterosacral ligaments in the causation of rectal intussusception, abnormal bowel emptying, and fecal incontinence- a prospective study, J. Pelviperineology 2008; 27:118-121.
- Petros PEP, Richardson PA, The TFS posterior sling improves overactive bladder, pelvic pain and abnormal emptying, even with minor prolapse – a prospective urodynamic study, Pelviperineology 2010, in press.
- Bornstein J, Zarfati, D, Petros PEP, Causation of vulvar vestibulitis ANZJOG 2005, 45: 538–541.
- Petros PE, Interstitial Cystitis, CHAPTER 7 – Current and Emerging Research Issues, The Female Pelvic Floor 2nd Edition, Petros PE, 2006, Springer Heidelberg, p 209.
- Butrick CW, Sanford D, Hou Q, Mahnken JD. Chronic pelvic pain syndromes: clinical, urodynamic, and urothelial observations. Int Urogynecol J Pelvic Floor Dysfunct. 2009;20:1047-53.
- Cameron A1 Gajewski J Bladder Outlet Obstruction in Painful Bladder Syndrome/Interstitial Cystitis, Neurourology and Urodynamics 2009; 28:944–948.

Correspondence to:

Professor Peter Petros
14A Osborne Pde - Claremont
WA 6010 - Australia
Tel No: M 61-411 181 731
Fax: 61-89-384 0176
E-mail: kvinno@highway1.com.au