

# Clinical and functional results after tailored surgery for rectovaginal fistula

GIUSEPPE GAGLIARDI MD - MARIO PESCATORI MD, FRCS (HON), EBSQ

Coloproctology Unit, Villa Flaminia Hospital, Rome, Italy

**Abstract:** Forty patients were treated for recto-vaginal fistula between 1988 and 2005. Thirty-five patients underwent surgery (sphincteroplasty=12, fistulectomy and layered closure=10, advancement flap=5, diversion only=2, coloanal=2, fistulotomy=1, omentoplasty=1, ileal resection=1, Martius graft=1). Of the 33 patients who underwent fistula repair 25 (76%) healed. Two patients healed after a second procedure, therefore final healing occurred in 27 (82%). Preoperative incontinence improved in 5/7 (71%) patients while 4/32 (12%) patients developed postoperative incontinence. There was no predictor of healing or incontinence. Choice of the appropriate treatment with selective use of sphincters and levators for reconstruction of the rectovaginal septum are likely to be relevant for successful outcome.

**Key words:** Recto-vaginal fistula; Sphincteroplasty; Fistulectomy; Advancement flap.

## INTRODUCTION

Recto-vaginal fistulae (RVF) are complex fistulae particularly difficult to treat. Their frequency is relatively low, representing less than 5% of anorectal fistulae.<sup>1</sup> Obstetric injury is by far the most frequently reported cause of low recto-vaginal fistulae.<sup>2-5</sup>

The outcome after surgery for RVF has been correlated with aetiology, complexity of disease, sphincter function and prior attempts to repair.<sup>6</sup> The type of operation to correct the fistula may be a fistulotomy or an endorectal advancement flap (EAF) in case of simple fistulae.<sup>7</sup> Often, to repair concomitant sphincter defects or to interpose vascularized tissue a sphincteroplasty or a muscle flap is needed.<sup>8</sup> More rarely transabdominal resection with an omentoplasty or a coloanal anastomosis is required.<sup>9</sup>

Because of the diversity of the approach the majority of articles found in the literature deal with a single procedure and often do not include results on anal continence. The aim of the present study was to evaluate the outcome of surgery after a variety of procedures, assessing both healing of the fistula and anal continence.

## MATERIALS AND METHODS

We reviewed the charts of 40 consecutive patients with RVF seen in our Coloproctology Unit between 1988 and 2004. Median age was 43 (range 27-87). Fistula aetiology is outlined in table 1. The height of the fistula in the recto-vaginal septum was low in 24 cases, middle in 15 and high in 1 case. Twenty-six fistulae (65%) were complex according to the Rothemberger classification.<sup>6</sup>

Five patients (13%) had undergone 7 prior attempts at RVF repair (advancement flap=1; fistulotomy=2; fistulectomy and closure=4). Four other patients had undergone fistulotomy and/or drainage procedures for perianal sepsis. Six patients had previously undergone a sphincteroplasty, which was performed because of incontinence in 5 cases and to repair a RVF in one.

Preoperative manometry was available in 17 (42%) patients to measure resting tone and squeeze pressure in the anal canal as well as rectal capacity (sensation at onset of stimulus, call for stool and maximal urgency). Preoperative manometry was performed using water filled catheters connected via pressure transducers to a polygraph (Medtronic, Milan, Italy). Low manometric pressure was defined as a resting pressure of less than 50mmHg or a squeeze pressure of less than 110 mmHg. Rectal volumes were calculated with an air filled balloon and were defined as low if an urge sensation was present with less than 60 cc of air. Anal

and vaginal ultrasonography was available in 12 patients (30%). Anal ultrasound (AUS) was carried out using a 7 mHz rotating probe filled with degassed water and attached to an ultrasound machine (BK Medical, Ahrens, Denmark). Both sphincter muscles and fistula tract were examined. If an opening was identified with anoscopy or vaginoscopy, hydrogen peroxide was injected to highlight fistula tract.

Five patients did not undergo surgery. One because of patient's choice, one because of minimal symptoms and three because fistula healed after medical therapy. Thirty five patients (87%) underwent surgery (Tab. 2). Sphincteroplasty, always combined with levatorplasty, was performed through a perineal incision as described by Corman.<sup>10</sup> Indications for sphincteroplasty were incontinence (n=4), prior sphincteroplasty as cause of fistula (n=3), occult tear on AUS (n=2) and need of vascularized tissue (n=3). EAF was performed using a flap of rectal mucosa and part of the smooth muscle layer as described by Rothemberger et al.<sup>7</sup> Fistulectomy with layered closure was performed transanally with non-overlapping reabsorbable sutures. A transanal or transvaginal levatorplasty was performed in 4/10 fistulectomies and 1/5 EAF. In one patient with RVF from a sphincteroplasty a flap of bulbocavernosus muscle (Martius graft) was interposed between rectum and vagina. One patient (3%) with radiation proctitis underwent permanent diversion. Of the remaining 34 patients 8 (25%) underwent temporary diversion prior to or at time of surgery (sphincteroplasty=5; EAF after failed repair=1; coloanal=2). Perioperative intravenous broad spectrum antibiotics were used in all cases.

TABLE 1. - *Fistula Etiology.*

<i>Etiology</i>	<i>number</i>	<i>(%)</i>
Obstetric	8	(20)
Unknown	8	(20)
Bartholin's cyst	5	(13)
Crohns	6	(15)
Criptoglandular	3	(7)
Radiotherapy	3	(7)
Sphincteroplasty	3	(7)
Ulcerative Colitis	2	(5)
STARR*	1	(3)
Hysterectomy	1	(3)

\* Stapled transanal rectal resection.

TABLE 2. – Surgical procedures in 35 operated patients.

Procedure	number	(%)
Sphincteroplasty	12	(34)
Layered closure	10	(28)
EAF*	5	(14)
Colectomy and coloanal	2	(6)
Omentoplasty	1	(3)
Permanent diversion	1	(3)
Temporary diversion only	1	(3)
Fistulotomy	1	(3)
Ileal resection	1	(3)
Martius flap	1	(3)

\* Endorectal advancement flap.

Mean follow up was 42 months (median 18; range 1-120). Treatment endpoints were fistula healing and anal continence. Anal continence was evaluated using a validated classification (Tab. 3) which takes into account both severity and frequency of symptoms.<sup>11</sup> Variables examined are listed in table 4. Statistical analysis was done using two sided Fisher's exact test and a two tailed t test.

RESULTS

Fistula recurrence

Treatment outcome is outlined in figure 1. Three of 5 medically treated patients healed their fistula (IBD=2; Bartholin=1). One patient with radiation proctitis underwent permanent diversion, and one patient completely healed after temporary diversion. If we exclude the patient with permanent diversion surgery was successful in 25/34 (73%). One patient with Crohn's disease healed her fistula after ileal resection. Of the 33 patients who underwent fistula repair healing occurred after first surgery in 25 (76%). Mean time to recurrence was 4 weeks (median 3 weeks; range 1-42 weeks). Five of the 8 patients with recurrent RVF underwent a second surgery (Fig. 1). Of them, one patient underwent redo sphincteroplasty, 3 patients underwent fistulotomy of residual fistula tracts and one required faecal diversion after dehiscence of sphincteroplasty and declined further treatment. Ultimately 27 of 33 patients (82%) who underwent fistula repair had their fistula healed at last follow-up visit.

TABLE 3. – Pescatori's classification of anal incontinence.

Type of incontinence	Frequency of episodes
A = incontinence to mucus or flatus	1 = sporadic
B = Incontinence to liquids	2 = often
C = Incontinence to solids	3 = always

There were no statistically significant predictors of fistula recurrence after the first surgery. After including the results of second surgery 12/12 patients (100%) after sphincteroplasty healed versus 11/15 (73%) patients treated with either layered closure or advancement flap, but this did not reach statistical significance.

Anal continence

Seven patients (14%) had anal incontinence at time of referral. Postoperative continence in relation to preoperative continence is outlined in figure 2. Of the 7 patients who were incontinent before surgery 5 improved (3 after sphincteroplasty, 1 after fistulectomy and closure, 1 after EAF and levatorplasty), 1 remained incontinent (after sphincteroplasty) and one was still diverted at last follow up

TABLE 4. – Variables examined in statistical analysis.

Age
Fistula height
Fistula complexity
Etiology
Type of surgery
Prior RVF surgery
Prior anorectal surgery
Interposition of vascularized tissue*
Concomitant levatorplasty
Temporary diversion
Preoperative continence score
Postoperative continence score
Low manometric pressure
Low rectal volume
TRUS sphincter defects

\* External sphincter, levator ani, bulbocavernous muscle

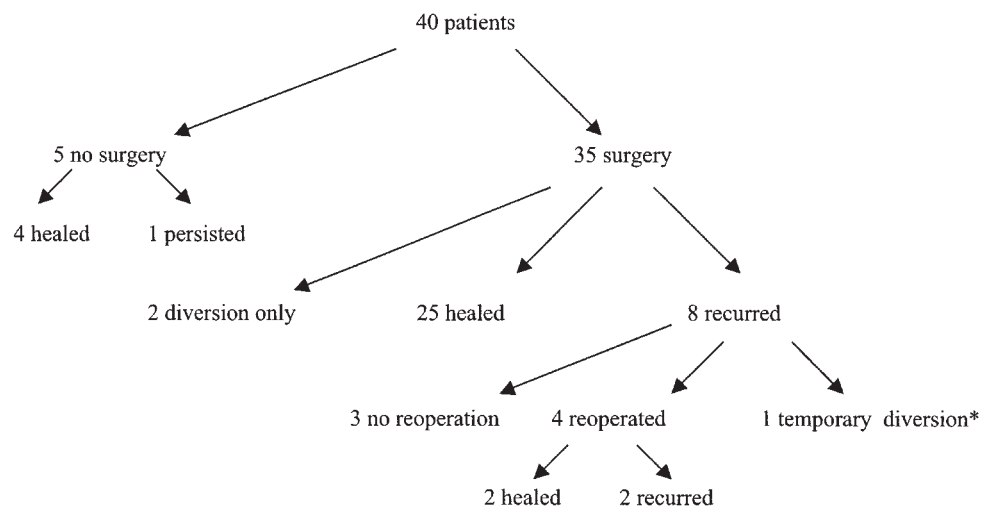


Fig. 1. – Treatment and outcome. - Legend: Treatment outcome in 40 patients with recto-vaginal fistula. \* Refused further surgery.

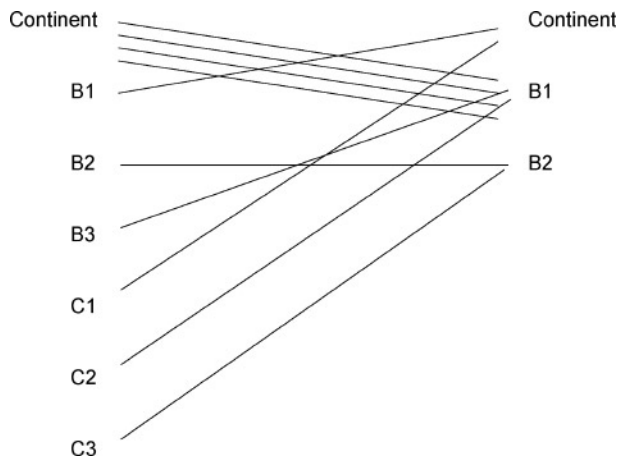


Fig. 2. – Pre and postoperative classification of incontinence. - Legend: Alteration of continence after RVF surgery. Patients with fecal diversion were excluded.

visit. Minor postoperative incontinence developed in 4 patients (sphincteroplasty=2; fistulectomy=1; coloanal=1). There were no statistically significant predictors of postoperative continence.

*Manometry and Ultrasonography*

Manometry results were available in 17 patients. Low squeeze pressure were recorded in 7 patients, five of whom had no symptoms of faecal incontinence. In some of these continent patients low pressures were felt to be secondary to pain caused by the RVF. Low rectal volume was recorded in 3 cases. Because of reduced rectal volume one patient underwent permanent diversion instead of a reconstructive procedure.

AUS correctly identified the fistula tract in 8/12 cases (66%) including 3/4 cases (75%) of occult fistula, and identified associated sphincter defects in 4/12 cases including 2 asymptomatic patients with obstetric trauma. Both of these patients underwent a sphincteroplasty based on ultrasonographic findings.

*Postoperative Complications*

Complications are listed in Table 5. One patient died because of small bowel obstruction and perforation at time of colostomy reversal. Suture dehiscence occurred after sphincteroplasty in 3 cases and after fistulectomy and layered closure in one. This complication required operative revision in one case, temporary diversion in one case and minor outpatient revisions in 2 cases.

**DISCUSSION**

The present series reflects the practice of a specialized coloproctology unit. Twenty-six of 40 fistulae (65%) were complex and 16/40 (40%) patients had already undergone perineal procedures for sepsis, incontinence and obstructed defecation. In this patients population we achieved a healing rate of 81% with fistula repair. Presence of scar tissue

TABLE 5. – Postoperative complications.

Complication	number	(%)
Death	1	(2)
Suture dehiscence	4	(10)
Perianal fistula	1	(2)

Complications within one month of surgery in 35 operated patients.

from previous procedures has been correlated with worse outcome by other authors<sup>8,12</sup> but not in the present series. The use of vascularized flaps in 17/29 (59%) perineal procedures may in part explain these result.

The role of fecal diversion is controversial. While its use is of unproven benefit some authors advocate routine temporary diversion for anastomotic RVF and fistulae secondary to radiation injury.<sup>13</sup> Serious consideration should be given to diversion after large advancement flaps and after a complicated sphincteroplasty.<sup>9</sup> In our series temporary diversion was selectively used in RVF after prior sphincteroplasty, after a failed attempt to RVF repair and in both cases of coloanal procedure. Even if it is impossible to prove its benefits, it is likely that this has contributed to our high healing rate in these difficult patients. Temporary diversion is not without complications, as testified by one postoperative death after colostomy reversal. We therefore recommend to be extremely selective with temporary diversion and to limit its use to the cases with severe tissue inflammation and poorly vascularized tissue in which slow healing is expected.

One hundred % of patients undergoing sphincteroplasty were free of fistula at time of last follow-up compared with 73% of patients undergoing either layered closure or advancement flap, although this did not reach statistical significance. Other studies failed to report an advantage between sphincteroplasty and layered closure or EAF.<sup>7,14,15</sup> Nevertheless it is important to know that in complicated cases of RVF with sphincter involvement excellent results may be achieved by interposing sphincter muscle between rectum and vagina. Five of 13 patients (38%) underwent transvaginal or transperineal levatorplasty in addition to layered closure or EAF. Performing a levatorplasty in addition to a sphincteroplasty increases the chances of success from 33% to 96% according to Tsang et al.<sup>16</sup> This was done routinely in our patients. Adding a levatorplasty to a fistulectomy did not significantly improve healing or continence, but numbers are too small to draw conclusions.

Performing a preoperative AUS allowed us to identify cases of occult sphincter defect. The importance of selecting patients who may benefit from sphincter repair using preoperative AUS has been previously reported<sup>17</sup> and cannot be overemphasized. AUS also helped to guide the surgeon in 3 of 4 cases with occult fistula tract. Our results compare with the literature where identification of fistula tract by AUS is possible in 28% to 96% of cases.<sup>18-20</sup> Sensitivity may be increased by injecting hydrogen peroxide into the tract<sup>21</sup> as in the present series.

We are reporting that measurement of squeeze pressure at manometry may yield false positive results secondary to perineal pain which may be experienced by the patient asked to squeeze during sphincter assessment. Nevertheless volume measurements with manometry helped us identifying a case with reduced rectal capacity in whom a reconstructive procedure would achieve poor functional results. We therefore suggest that both EUS and manometry are routinely performed before attempting RVF repair through either a perineal or an abdominal approach.

Interestingly, half of the cases of RVF secondary to IBD were treated non-operatively and 2 cases were treated through an abdominal approach (colectomy and coloanal=1; ileal resection=1). Healing occurred with medical treatment only (n=2), after a sphincteroplasty (n=1) and in both cases treated through an abdominal approach. High failure rates after attempts to RVF repair are thought to be due to proximal disease and to poorly vascularized chronically inflamed tissue.<sup>22-25</sup> Recently high failure rates after EAF in Crohn's disease have been reported as well as improved results when

proximal bowel resection was simultaneously performed.<sup>26</sup> Our results seem to confirm these findings. Healing of RVF secondary to IBD after medical treatment is thought to be rare.<sup>27</sup> Our finding that 2/4 (50%) healed while medically treated emphasizes that surgical approach in these patients needs to be very selective and that no attempt to local repair should be undertaken in the presence of local or proximal inflammation.

Fistula closure was always performed transanally. The transvaginal approach is routinely used by gynecologists but does not abide by the principle that the repair should be on the high-pressure side, namely the rectum, and thus is not favoured by colorectal surgeons. However no prospective comparison of transanal vs transvaginal repair can be found in the literature.

In conclusion RVF are associated with a variety of conditions to be taken into account for the treatment to be successful. Thorough preoperative anatomical and functional assessment and elimination of all active inflammations are key to succeed. In the present retrospective study we did not find any approach to be superior. The overall healing rate after sphincteroplasty was 100%. Sphincter reconstruction was achieved without difficulty since 80% of these patients had prior sphincter surgery and 50% underwent a diverting stoma. Therefore no single procedure is likely to prove successful in all cases and flexibility in tailoring surgical approach to this variety of factors is required.

#### REFERENCES

- Laird DR. Procedures used in treatment of complicated fistulae. *Am J Surg* 1948; 76: 701-8.
- Lescher TC, Pratt JH. Vaginal repair of the simple rectovaginal fistula. *Surg Gynecol Obstet* 1967; 124: 1317-21.
- Goldabar KG, Wendel PJ, McIntire DD, Wendel GD. Post-partum perineal morbidity after fourth degree perineal repair. *Am J Obstet Gynecol* 1993; 168: 489-93.
- Venkatesh KS, Ramanyam PS, Larson DM, Haywood MA. Anorectal complications of vaginal delivery. *Dis Colon Rectum* 1989;32:1039-41.
- Radcliffe AG, Ritchie JK, Hawley PR et al. Anovaginal and rectovaginal fistulae in Crohn's disease. *Dis of Colon Rectum* 1988; 31: 94-9.
- Tsang CBS, Rothenberger DA. Rectovaginal fistulae. Therapeutic options. *Surg Clin North Am* 1997; 77: 95-114.
- Rothenberger DA, Christenson CE, Balcos EG, et al. Endorectal advancement flap for treatment of simple rectovaginal fistula. *Dis Colon Rectum* 1982; 25: 297-300.
- MacRae HM, McLeod RS, Cohen Z, Stern H, Reznick R. Treatment of rectovaginal fistulae that has failed previous repair attempts. *Dis Colon Rectum* 1995; 38: 921-5.
- Hull T. Rectovaginal fistula. In: Current therapy in colon and rectal surgery. Fazio VW, Church JM, Delaney CP. (Eds) Mosby Philadelphia 2005; 35-40.
- Corman ML. Anal sphincter reconstruction. *Surg Clin North Am* 1980; 60: 457-63.
- Pescatori M, Atanasio G, Bottini C, Mentasti A. New grading and scoring for anal incontinence: evaluation of 355 patients. *Dis Colon Rectum* 1992; 35: 482-7.
- Lowry AC, Thorson AG, Rothenberger DA, Goldberg SM. Repair of simple rectovaginal fistulae: influence of previous repairs. *Dis Colon Rectum* 1988; 31: 676-8.
- Lowry AC. Rectovaginal Fistulae. In: Fundamentals of anorectal surgery. Wexner SD, Beck DE. Eds. Mc Graw Hill, New York. 1992; 197-201.
- Wise WE Jr, Aguilar PS, Padmanabhan A, Meesig DM, Arnold MW, Stewart WR. Surgical treatment of low rectovaginal fistulae. *Dis Colon Rectum* 1991; 34: 271-4.
- Zimmerman DDE, Gosselink MP, Briel JW, Schouten WR. The outcome of transanal advancement flap repair of rectovaginal fistulae is not improved by an additional labial fat flap transposition. *Tech Coloproctol* 2002; 6: 37-42.
- Tsang CB, Madoff RD, Wong WD et al. Anal sphincter integrity and function influences outcome in rectovaginal fistula repair. *Dis Colon Rectum* 1998; 41: 1141-1146.
- Yee LF, Birnbaum EH, Read TE, Kodner IJ, Fleshman JW. Use of endoanal ultrasound in patients with rectovaginal fistulae. *Dis Colon Rectum* 1998; 42: 1057-64.
- Tio TL, Mulder CJ, Wijers OB, Sars PR, Tytgat GN. Endosonography of peri-anal and peri-colorectal fistula and/or abscess in Crohn's disease. *Gastrointest Endosc* 1990; 36: 331-3369.
- Schratter-Sehn AU, Lochs H, Handl-Zeller L, Tscholakoff D, Schratter M. Endosonographic features of the lower pelvic region in Crohn's disease. *Am J Gastroenterol* 1993; 88: 1054-1057.
- Poen AC, Felt-Bersma RJF, Cuesta MA, Meuwissen SGM. Vaginal endosonography of the anal sphincter complex is important in the diagnosis of faecal incontinence and perianal sepsis. *Br J Surg* 1998; 85: 359-363.
- Cheong DM, Nogueras JJ, Wexner SD, Jagelman DG. Anal endosonography for recurrent anal fistulae: image enhancement with hydrogen peroxide. *Dis Colon Rectum* 1993; 36: 1158-60.
- Hellers G, Bergstrand O, Ewerth S, Holmstrom B. Occurrence and outcome after primary treatment of anal fistulae in Crohn's disease. *Gut* 1980; 21: 525-7.
- Heuman R, Bolin T, Sjobahl R, Tagesson C. The incidence and course of perianal complications and arthralgia after intestinal resection with restoration of continuity for Crohn's disease. *Br J Surg* 1981; 68: 528-30.
- Makowiec F, Jehle EC, Becker HD, Starlinger M. Clinical course after transanal advancement flap repair of perianal fistula in patients with Crohn's disease. *Br J Surg* 1995; 82: 603-6.
- Topstad DR, Panaccione R, Heine JA, Johnson DRE, MacLean AR, Buie DW. Combined Seton Placement, Infliximab infusion, and maintenance immunosuppression improve healing rate in fistulizing anorectal Crohn's disease. *Dis Colon Rectum* 2003; 46: 577-583.
- Marchesa P, Hull TL, Fazio VW. Advancement sleeve flaps for treatment of severe perianal Crohn's disease. *British Journal of Surgery* 1998; 85: 1695-1698.
- Poritz LS, Rowe WA, Koltun WA. Remicade.® Does not abolish the need for surgery in fistulizing Crohn's disease. *Dis Colon Rectum* 2002; 45: 771-775.

Correspondence to:  
Dr. MARIO PESCATORI  
Villa Flaminia Hospital  
Via Bodio, 58 - 00191 Roma  
Tel. 0039.3387311044  
E-mail: ucplclub@virgilio.it