

Case report

Can motor urge incontinence be surgically cured?

KLAUS GOESCHEN

University of Hannover, Hannover, Germany

Summary: Urodynamic testing confirmed that surgical restoration of vault prolapse can cure motor urge incontinence as hypothesized by the Integral Theory.

Key words: Urgency; Motor urge incontinence; Integral theory; Posterior intravaginal sling.

INTRODUCTION

Though symptomatic cure of urge incontinence has been previously reported by reinforcing the uterosacral ligaments, no urodynamic evidence of this has been presented to date. The following case is presented. A 60 year old teacher with a history of severe motor urge incontinence had been treated unsuccessfully with drugs over many years. She was very depressed. On straining, the posterior vaginal wall was prolapsed to within 1cm of the introitus. There was no urine loss on cough. Invariably she wet the floor on the way to the toilet. During fast-fill cystometry (100mls/minute) a massive painful detrusor contraction was noted at 180 mls volume, the patients maximal bladder capacity. The patient underwent Posterior Vaginal Slingplasty for repair of her vault prolapse. The day after surgery, she voided volumes of 300-500 mls spontaneously and was entirely dry. Three months later urodynamic testing demonstrated a maximal bladder capacity of 350 mls without urine loss at any stage, and with no evidence of detrusor instability.

CASE REPORT

A 60 years old teacher, presented with a 5 year history of urinary frequency every 15 minutes, nocturia 4-5 times per night, severe motor urge incontinence, difficulty with defecation, and "dragging" lower abdominal pain which varied in intensity. She had no stress incontinence. She had undergone abdominal hysterectomy because of fibroids 8 years earlier, and a laparotomy for a benign ovarian tumour 4 years after the hysterectomy. She delivered 3 infants vaginally, two of which weighed more than 4000 gm. She had consulted several urologists and gynecologists, and had been investigated on several occasions with ultrasound, urodynamics and cystoscopy. She was treated with pelvic floor exercises and several anticholinergic-type drugs without success. From a social impact perspective, she was unable to finish a lesson without several visits to the toilet. She was constantly embarrassed by the urine odour from her pads to the point where she had ceased sexual intercourse, holidays, and all social contact. When first seen, she was very depressed and under psychiatric care because of suicidal thoughts.

She was assessed according to the structured questionnaire and examination^{1, 2}. On the way to the examination couch, she developed an uncontrolled urge and wet the floor. On speculum examination, she had a chronic vulvovaginitis due to irritation from the chronic urine loss. The vagina was only 5cm long. The anterior vaginal wall was anatomically normal. The posterior vaginal fornix and the posterior vaginal wall were prolapsed and bulging 2cm beyond the introitus on straining (Fig. 1). There was no urine loss on cough stress testing and the 24 hour pad test yielded 255 gm of urine loss. The 24 hour diary confirmed her

history of a urinary frequency 30-40 per day. On palpation, the muscle tone of the levator ani was reduced. Ultrasound confirmed normal urethrovesical anatomy and function during coughing and straining, with a normal anterior and posterior shelf, and absence of any cystocele.

Urodynamic testing (Fig. 2) demonstrated a first desire to void at 100 mls, (detrusor pressure 3cm H₂O). At 160 ml the patient experienced a strong desire to void (detrusor pressure 11 cm H₂O). At 180 ml volume the patient developed a massive painful detrusor contraction (detrusor pressure 50 cm H₂O) which resulted in a large urine loss. Maximal urethral closure pressure was 154 cm at rest and 150 cm during coughing, with no urine leakage.

The patient underwent a Posterior Intravaginal Slingplasty (infracoccygeal sacropexy) procedure with rectovaginal fascia and perineal body repair. The catheter was removed 12 hours post-operatively. The patient voided spontaneously, volumes of 300-500 mls. There was immediate cure of all symptoms that continued over the ensuing 4 years of follow-up. Frequency was reduced to 4-5 per day; nocturia, 0-1 per night; pelvic pain was 100% cured; defecation was normal; urge and urge incontinence were cured and the patient was 100% dry.

A structured assessment was performed post-operatively at 3 months. The questionnaire confirmed symptomatic cure. From a social impact perspective, the patient had resumed going to the theatre. She was able to teach without any visits to the toilet, and to travel on bus and plane. There was normal restoration of anatomy on vaginal examination. The vaginal length was now 7cm, with a normal axis and angle. The 24 hour pad test gave a zero gm urine loss.

Urodynamic testing (Fig. 3) demonstrated a first desire to void at 220 mls (detrusor pressure 15cm H₂O) and a second desire to void at 290 mls. Maximal bladder capacity was

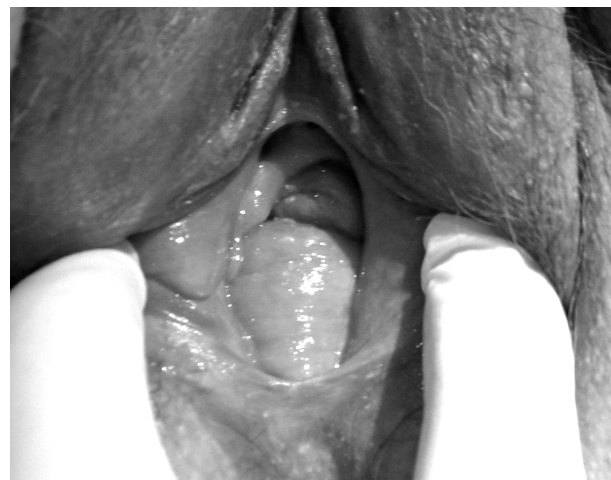

Fig. 1. – Entero/rectocele grade 2-3.

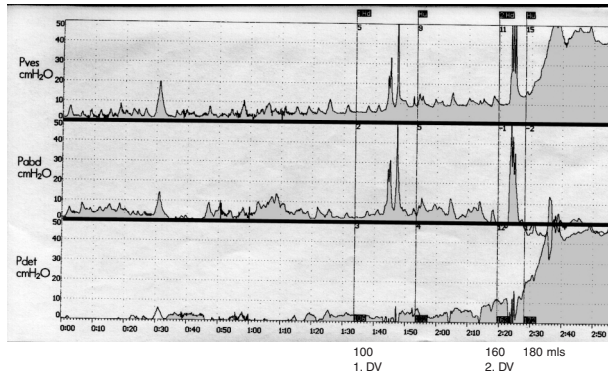


Fig. 2. – Urodynamic testing pre-operatively.

350 mls (detrusor pressure 29cm H₂O). There was no urine loss at any stage.

This patient presented with an everted vaginal vault prolapse, and the classical symptoms of the ‘posterior fornix syndrome’ as described by Petros and Ulmsten in 1993¹. The surgical cure of urge incontinence, frequency and nocturia is controversial. The aim of this operation was primarily to cure the vault prolapse. However, it also presented a unique opportunity to challenge the underlying Integral Theory of Petros & Ulmsten. The symptoms comprising this syndrome include frequency, urgency, nocturia, some types of pelvic pain, and abnormal bladder emptying. Farnsworth³ reported cure of such symptoms with the Posterior IVS operation for repair of uterovaginal prolapse in 80% of cases following restoration of the 3 levels of anatomy.⁴ However, there has not been any objective proof offered to date in any of the previous studies to confirm the basis for cure hypothesized by the Integral Theory. The post-operative urodynamic findings, figure 2, appear to confirm that anatomical restoration of the posterior ligamentous supports of the vagina may not only cure the vault prolapse, but also improve the symptoms of the ‘posterior fornix syndrome’.¹

Sixty years earlier Heinrich Martius⁶ mentioned already in his textbook of gynecology that symptoms of urgency, frequency, nocturia and pelvic pain were potentially curable by restoration of vaginal anatomy, but Petros and Ulmsten⁵ have given the anatomical basis for cure of these symptoms: in essence, the vagina is suspended anteriorly by the pubourethral ligaments, posteriorly by the uterosacral ligaments and in the middle by the pubocervical fascia and the arcus tendineus fascia pelvis ligaments. Three muscle forces stretch the vaginal membrane like a trampoline to support the bladder base stretch receptors. If the membrane is loose, the stretch receptors may fire off prematurely at a low bladder volume to stimulate the micturition reflex. This is interpreted by the cortex as frequency, urgency and noc-

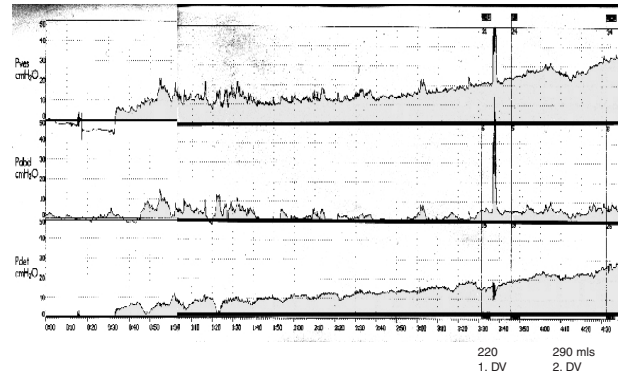


Fig. 3. – Urodynamic testing 3 month post-operatively.

turia. The reason for the pelvic pain is said to be due to inability of the uterosacral ligaments to support the unmyelinated nerve fibres running along the ligaments: gravity pulls the lax ligaments downwards and this stimulates excessive afferent pain impulses from the unmyelinated nerve endings travelling to the cerebrospinal nerve system.

REFERENCES

1. Petros PE and Ulmsten UU. An Integral Theory and its Method for the Diagnosis and Management of Female Urinary Incontinence. *Scandinavian Journal of Urology and Nephrology* 1993; 27: Suppl. 153: 1-93.
2. Petros PE. New ambulatory surgical methods using an anatomical classification of urinary dysfunction improve stress, urge, and abnormal emptying. *Int J Urogynecology* 1997; 5: 270-278.
3. Farnsworth BN. Posterior Intravaginal Slingplasty (infracoccygeal sacropexy) for severe posthysterectomy vaginal vault prolapse- a preliminary report. *Int J Urogynecol* 2002; 13: 4-8.
4. Petros PE. Vault prolapse II: Restoration of dynamic vaginal supports by the infracoccygeal sacropexy, an axial day-care vaginal procedure. *Int J Urogynecol Pelvic Floor Dysf.* 2001; 12: 296-303.
5. DeLancey JOL. Anatomic aspects of vaginal eversion after hysterectomy. *Am J Obstet Gynecol* 1992; 166: 1717-1728.
6. Martius H. *Lehrbuch der Gynäkologie*. 1. Auflage 1946, Georg Thieme Verlag, Stuttgart, 1946

Address for Correspondence:

Prof. Dr. med. KLAUS GOESCHEN
 Uro-Gynaecologist
 University of Hannover
 Hildesheimer Strasse 34-40
 30169 Hannover - Germany
 Tel 49 511 235 8668 - Fax 49 511 235 8671
 e-mail: goeschen@carpe-vitam.info