

Repair of rectovagina fistula consequent on anal coitus

PRABHAT CHANDRA MONDAL

Bankura Sammilani Medical College Bankura, India

Keywords: Rectovaginal fistula; Coital injury

Rectovaginal injury due to coitus is a great challenge to the surgeons, as it could lead to rectovaginal fistula. Apart from child birth, surgeons and gynaecologists in India get many cases of rectal injury due to fall on sharp object, cow horn goring and coitus. Here, we got a case of complete rectovaginal tear due to coitus. A 35/-year-old woman with previous two vaginal deliveries attend at mid night due to vaginal bleeding following sexual relation. She is separated from her husband and has had sexual relations occasionally with her boy friend. It was an anal sex in supine position. Following sudden thrush, she felt pain and saw bleeding per vagina. Immediately, she was admitted in our hospital.

Vagina was packed. Intravenous fluids (IV), antibiotics and analgesics were given. One unit blood was requisitioned as she had haemoglobin of 8 gm%. Under anaesthesia, the wound was evaluated, and washed with antibiotic lotion. Rectum was found empty. Surgeon introduced left index finger per rectum into vagina easily (Figure 1 A). Colostomy was not done, as we managed similar cases previously without colostomy. Vaginal epithelium was separated from

rectum (Figure 1B). Rectal mucosa was sutured with 3 O vicryl interrupted with placing the knots into the rectal lumen (Figure 1C). Denonvilliers' fascia was repaired separately. Vaginal was closed (Figure 1D). As per our hospital protocol, we kept her on IV fluid for two days, on liquid diet for three days. IV triple antibiotics were continued for 5 days. On sixth postoperative day, she was allowed normal diet with laxatives (lactulose).

On 8th day, she was discharged without any fistula with advice to take Vitamin C 500 mg once daily, lactulose for six weeks. She was examined after four months having no symptoms.

Correspondence to:

Prabhat Chandra Mondal MB BS MS (OBG), DGO Assistant Professor (91-9434438618) Jogeshpally Bankura 722101 West Bengal - India

E-mail: prabhatmndl@yahoo.co.in

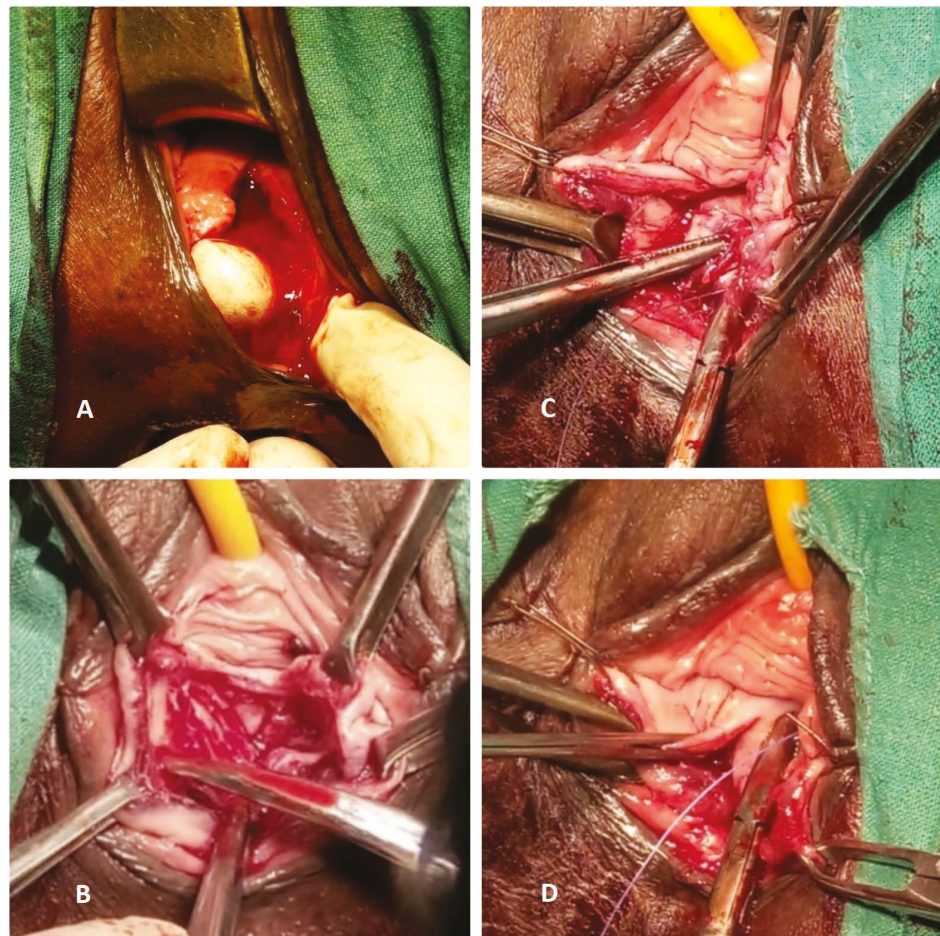


Figure 1

- A. Complete perforation of recto-vaginal septum
- B. Vaginal mucosa was separated from underlying fascia sharply
- C. Rectal mucosa and overlying fascia were repaired separately
- D. Vaginal wall was repaired