

Sphincteroplasty, perineoplasty, anus remodeling

ALVARO OCHOA CUBEROS

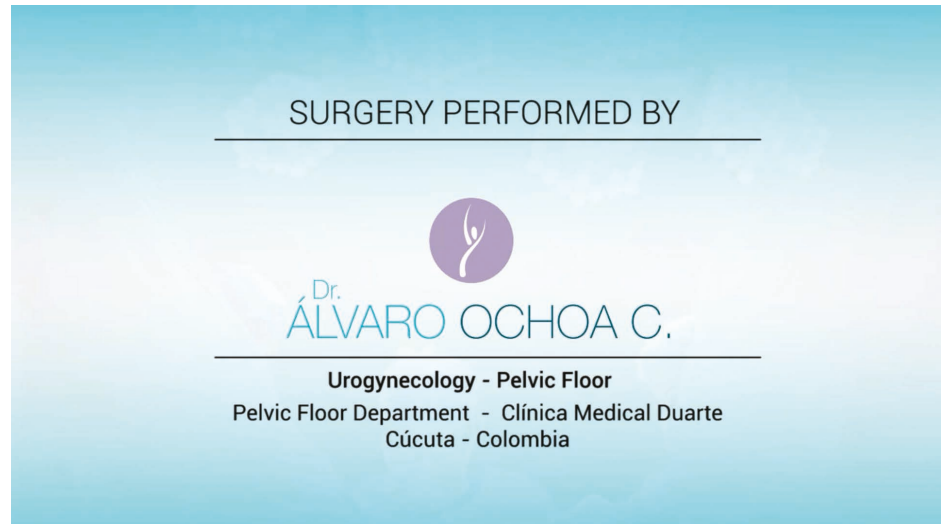
Pelvic Floor Department, Clínica Medical Duarte, Cúcuta - Colombia

Abstract: An 18 year old patient with a history of sexual abuse since she was 11 years old presented with grade IV tear after a vaginal delivery 48 hours before the surgical procedure. Deep involvement of the rectal mucosa, of the entire sphincter and absence of the perineal body was observed.

Keywords: Sphincteroplasty; Perineoplasty; Anus remodeling



<https://youtu.be/UYoIuMkCg34>



Correspondence to:

Alvaro Ochoa Cuberos - Vitta Centro de Especialistas Avenida 1
#7_73. Piso 10 - Cúcuta 540001 Norte de Sabtander - Colombia
E-mail: aocchoa_cuberos@hotmail.com