

PELVIPERINEOLOGY

A multidisciplinary pelvic floor journal

INSTRUCTIONS FOR AUTHORS

The manuscripts including tables and illustrations must be submitted to Pelviperiology only via the Isubmit system www.isubmit.it. This enables a rapid and effective peer review. Full upload instructions and support are available online from the submission site.

In http://www.pelviperiology.org/pelviperiology_authors_instructions.html please find the updated guidelines for the Authors.

Contents

- 34 On the attempted resuscitation of the pressure transmission theory for urethral closure
B. ABENDSTEIN
- 35 Identification of peri-prostatic neurovascular fibers before and after radical prostatectomy by means of diffusion tensor imaging (DTI) with clinical correlations: initial experience
S. SIRACUSANO, A.B. PORCARO, A. TAFURI, R. TALAMINI, A.J. CYBULSKI
- 42 Histopathology findings of the pelvic organ prolapse
F.M.A. CORPAS, A. ILLARRAMENDI, F. NOZAR, B. CASERTA
- 46 Bilateral Sacrospinous Colposuspension (BSC) for the treatment of vaginal vault prolapse – description of a novel method
D.G. KIEBACK
- 49 Introducing a new service of a midwife-led telephone follow-up clinic for 3a & 3b Obstetric Anal Sphincter Injury: retrospective service evaluation and patients' satisfaction survey
S. SHAWER, S. INNAYAT, H. HUTCHINSON, P. BALLARD, A. KHUNDA
- 53 Pathophysiology of the functional constipation in elderly
M.D. LEVIN
- 58 On collagen, ageing and surgical treatment options following commercial kit withdrawals- a critical analysis
B. ABENDSTEIN, D. SHKARUPA, P. PETROS
- 61 Letter to the editor
- 63 ISPP Congress 2019, October 6th-8th – Treviso (Italy)
Pelvic Floor Disorders: Current Status, Technological Advances and Perspectives



A MINIMALLY INVASIVE
AND EFFECTIVE BRIDGE BETWEEN
CONSERVATIVE THERAPY AND SURGERY
FOR BOWEL INCONTINENCE

secca®



EFFICIENT

Performed in an outpatient setting

SAFE

Less than 1% complication rate*

EFFECTIVE

Up to 84% of patients experienced
significant improvement*

QUICK RECOVERY

Return to normal activities in a few days

SECCA PATIENTS } experienced
84% } significant
improvement

Greater
Quality
of Life

Less than 1%
complications



Distributore esclusivo:

INNOVA
medica

PELVIPERINEOLOGY

A multidisciplinary pelvic floor journal

www.pelviperineology.org

Managing Editor GIUSEPPE DODI, *Colorectal Surgeon, Italy*
Assistant Managing Editor ADI Y. WEINTRAUB, *Urogynecologist, Israel*

Editors

ANDRI NIEUWOUTD, *Gynaecologist, Netherlands* - PETER PETROS, *Gynaecologist, Australia*
AKIN SIVASLIOGLU, *Urogynecologist, Turkey* - FLORIAN WAGENLEHNER, *Urologist, Germany*
Senior editor ELVIRA BARBULEA BRATILA, *Romania* - Editor emeritus BRUCE FARNSWORTH, *Australia*

Editorial Board

BURGHARD ABENDSTEIN, *Gynaecologist, Austria*
ANTONELLA BIROLI, *Physiatrist, Italy*
CORNEL PETRE BRATILA, *Gynaecologist, Romania*
SHUKING DING, *Colorectal Surgeon, P.R. China*
TRAIAN ENACHE, *Urogynaecologist, Romania*
ENRICO FINAZZI - AGRÒ, *Urologist, Italy*
KLAUS GOESCHEN, *Urogynaecologist, Germany*
DARREN M. GOLD, *Colorectal Surgeon, Australia*
WOLFRAM JAEGER, *Gynaecologist, Germany*
DIRK G. KIEBACK, *Gynaecologist, Germany*
FILIPPO LA TORRE, *Colorectal Surgeon, Italy*
NUCELIO LEMOS, *Gynaecologist, Brazil*
MICHAEL D. LEVIN, *Pediatric radiologist, Israel*
BERNHARD LIEDL, *Urologist, Germany*
NAAMA MARCUS BRAUN, *Urogynecologist, Israel*
ANDRI MULLER -FUNOGEA, *Gynaecologist, Germany*
MENAHEM NEUMAN, *Urogynaecologist, Israel*
PAULO PALMA, *Urologist, Brazil*

MARC POSSOVER, *Gynaecologist, Switzerland*
FILIPPO PUCCIANI, *Colorectal Surgeon, Italy*
RICHARD REID, *Gynaecologist, Australia*
GIULIO SANTORO, *Colorectal Surgeon, Italy*
YUKI SEKIGUCHI, *Urologist, Japan*
MAURIZIO SERATI, *Urogynaecologist, Italy*
DMITRY SHKAPURA, *Urogynecologist, Russia*
SALVATORE SIRACUSANO, *Urologist, Italy*
MARCO SOLIGO, *Gynaecologist, Italy*
JEAN PIERRE SPINOSA, *Gynaecologist, Switzerland*
MICHAEL SWASH, *Neurologist, UK*
VINCENT TSE, *Urologist, Australia*
PETER VON THEOBALD, *Gynaecologist, Reunion Island, France*
PAWEL WIECZOREK, *Radiologist, Poland*
QINGKAI WU, *Urogynaecologist, P.R. China*
ANASTASIYA ZAYTSEVA, *Urogynecologist, Russia*
CARL ZIMMERMAN, *Gynaecologist, USA*

Editorial Board

Aesthetic gynecology - RED ALINSOD (USA)
Andrology - ANDREA GAROLLA (Italy)
Challenging cases - VITO LEANZA (Italy)
Chronic pelvic pain - MAREK JANTOS (Australia)
Imaging - VITTORIO PILONI (Italy)
Medical Informatics - MAURIZIO SPELLA (Italy)
NeuroGastroenterology and Intestinal Rehabilitation -
GABRIELE BAZZOCCHI (Italy)

Pediatric Surgery - PAOLA MIDRIO (Italy)
Pelvic floor Rehabilitation - DONATELLA GIRAUDO (Italy),
GIANFRANCO LAMBERTI (Italy)
Psychology - SIBYLLA VERDI HUGHES (Italy)
Sacral Neurostimulation - MARIA ANGELA CERRUTO (Italy)
Sexology - OSCAR HORKY (Australia)
Statistics - CARLO SCHIEVANO (Italy)
Systematic Reviews - STERGIOS K. DOUMOCHTSIS (UK)

Official Journal of the: International Society for Pelviperineology (www.pelviperineology.com)
Asociación Latinoamericana de Piso Pelvico
Perhimpunan Disfungsi Dasar Panggul Wanita Indonesia
The Israeli Society of Urogynecology and Pelvic Floor
Romanian Uro-Gyn Society
Pelvic Reconstructive Surgery and Incontinence Association (Turkey)

Editorial Office: BENITO FERRARO, LUISA MARCATO

e-mail: benito.ferraro@sanita.padova.it - luisa.marcato@sanita.padova.it

Quarterly journal of scientific information registered at the Tribunale di Padova, Italy n. 741 dated 23-10-1982 and 26-05-2004

Editorial Director (Direttore responsabile): The President of the International Society for Pelviperineology

Printer: Litocenter Srl - Via Guido Rossa 17 - 35016 Piazzola sul Brenta (Padova) - e-mail: info@litocenter.it

On the attempted resuscitation of the pressure transmission theory for urethral closure

BURGHARD ABENDSTEIN

Gynäkologie und Geburtshilfe
Akademisches Lehrkrankenhaus Feldkirch, Feldkirch, Austria

There have been several recent attempts to resuscitate the pressure transmission theory closure mechanism for the bladder*^{1,2} and with it, the Integral Theory (IT) itself. How theories can be validated or invalidated has been defined by the lifetime work of Karl Popper, the most eminent philosopher of science of the 20th Century³. Popper's view is that no theory is perfect, and that only by being continually challenged, can it be improved, modified or discarded. All these outcomes are good for science.

In 1990, The late Ulf Ulmsten and Peter Petros disproved the main prediction of Enhorning's theory, elevating the bladder into the "pressure equalization zone". Stress incontinence cure was demonstrated in 30/30 patients with no evidence of bladder elevation on post-operative x-ray⁵. This finding emphasizes one key rule for validation or invalidation of theories, it has to be done by experiment, which has never been done by any critic of the Integral Theory. I report two more studies which experimentally invalidate the pressure equalization theory.

A 1995 study concerned an experiment during a mid-urethral sling operation performed under LA⁶. Two Galectec catheters, measured urethral and bladder pressures in equivalent positions inside and outside the bladder and urethra during coughing (Table 1). The pressures inside the bladder were slightly less than outside, but universally greater inside the urethra. Only an active reflex muscle action can explain these findings, which are not possible with a passive "pressure transmission" mechanism.

In a 2009 study by Kamo et al.⁷, urethral closure mechanisms during abrupt elevation of intravesical pressure P(ves) were investigated in a rat experiment. During sneezing, the middle urethral closing response was observed and remained intact even after opening the abdomen. According to the pressure equalization theory, there would be no response to sneezing if the abdomen was open.

Conflict of interest NIL

REFERENCES

1. Bergstrom BS More about the urethral hanging theory (UHT) and a response to Dr. Peter Petros' comments Article in Neurourology and Urodynamics. March 2019 doi: 10.1002/nau.23960
2. Wen L, Shek KL, Nishamini S, Talia F, Dietz HP, Correlations between sonographic and urodynamic findings after mid-urethral sling surgery, The Journal of Urology® 2018; doi: 10.1016/j.juro.2017.12.046.
3. Popper KR. A Survey of some fundamental problems. On the problem of a theory of scientific method. Theories. Falsifiability. The problem of the empirical basis. Degrees of testability. Simplicity. The Logic of Scientific Discovery. Unwin and Hyman, London, 1980, 27-146.
4. Liedl B, Inoue H, Sekiguchi Y, Gold D, Wagenlehner F, Haverfield M, Petros P Update of the Integral Theory and System for Management of Pelvic Floor Dysfunction in Females European J of Urology EURLUP-738 <http://dx.doi.org/10.1016/j.eur-sup.2017.01.001>
5. Petros PE, Ulmsten U. The combined intravaginal sling and tuck operation. An ambulatory procedure for stress and urge incontinence. Acta Obstetrica et Gynecologica Scandinavica 1990; Supplement 153, 69: 53-59.
6. Petros PE & Ulmsten U. Urethral pressure increase on effort originates from within the urethra, and continence from musculo-vaginal closure. Neurourology and Urodynamics, 1995; 14:337-350.
7. Kamo I, Kaiho Y, Miyazato M, Torimoto K, Yoshimura N. Two kinds of urinary continence reflexes during abrupt elevation of intravesical pressure in rats. Low Urin Tract Symptoms. 2009 Sep 1;1(s1):S40-S43.

Correspondence:

Burghard Abendstein MD PhD
burghard.abendstein@lkhf.at

* It is important to note that this debate on the pressure transmission theory closure mechanism for the bladder concerns only a small part of the 2018 iteration of the IT⁴, which states: "Prolapse, bladder, bowel and idiopathic pain symptoms mainly derive, for different reasons, from laxity in the vagina or its suspensory ligaments, a result of altered collagen/elastin."

Table 1 ⁶Intraoperative Cough Pressure Transmission, Vagina Intact*

Patient	Outside bladder (T ₁)	Inside bladder (T ₂)	Outside urethra (T ₁)	Inside urethra (T ₂)
ER	30.00	26.00	18.00	23.00
KW	22.00	20.00	4.00	10.00
PB	75.00	73.00	40.00	60.00
TH	70.00	65.00	80.00	100.00
MF	22.00	19.00	24.00	45.00
Mcan	44.00	41.00	33.00	47.60

*T1 is positioned outside the organ and T2 inside the organ

Identification of peri-prostatic neurovascular fibers before and after radical prostatectomy by means of diffusion tensor imaging (DTI) with clinical correlations: initial experience

SALVATORE SIRACUSANO¹, ANTONIO B. PORCARO¹, ALESSANDRO TAFURI¹, RENATO TALAMINI³, ADAM J. CYBULSKI²

¹ Department of Urology, AOUI Verona, University of Verona, Verona (VR), Italy;

² Department of Radiology, AOUI Verona, University of Verona, Verona (VR), Italy;

³ Epidemiology Unit CRO Aviano, Italy

Abstract: *Aim* To evaluate if Diffusion Tensor Imaging (DTI) is able to detect morphological changes of peri-prostatic neurovascular fibers (PNF) before and after robot-assisted radical prostatectomy (RARP) and if these changes are related to urinary incontinence (UI) and erectile dysfunction (ED). *Materials and methods:* From October 2014 and August 2017 26 patients with biopsy-proven prostate cancer underwent prostatic multi-parametric magnetic resonance imaging (mp-MRI) including DTI sequencing before and six months after, RARP. Images were analyzed by placing six regions of interest (ROI) respectively at the base, mid-gland and apex, one for each side, to obtain tractography reconstruction of the PNF. Patients were asked to complete an International Consultation Incontinence Questionnaire – Short Form (ICIQ-SF) and International Index of Erectile Function (IIEF-5) questionnaires before RARP and 6 months postoperatively. Fractional anisotropy (FA), number (N) and length (L) of PNF before and after RARP were compared by means of Student's t-test; Spearman test was used to evaluate the correlation between DTI parameters and questionnaires scores. We observed a significant difference in N values before and after RARP ($p < 0.001$) and a negative correlation between IIEF-5 score and post-operative FA values at both the right ($\rho = -0.42$; $p = 0.0456$) and left ($\rho = -0.66$; $p = 0.0006$) base of the prostate. DTI with tractography of PNF is able to detect quantitative changes in N, L and FA values in PNF after RARP. In particular we observed an inverse correlation between FA of PNF and ED at 6 months after RARP. Further investigations are needed to confirm this trend.

Keywords: MRI; Diffusion Tensor Imaging; RARP; Urinary continence; Erectile dysfunction

INTRODUCTION

In clinical practice, robot-assisted radical prostatectomy (RARP) is an effective option for treating prostate cancer (PCA) along with all clinical risk classes¹. However, drawbacks related to the procedure include urinary incontinence (UI) and erectile dysfunction (ED)¹. Nerve-sparing techniques during RARP have shown to reduce the risk of both UI and ED, whose rates vary from 89% to 42% and 32% to 18% for unilateral and bilateral nerve sparing, respectively^{1,2-6}. Because the number of preserved periprostatic neurovascular fibers (PNFs) associates with erectile function recovery^{7,8}, imaging visualization of these fibers is becoming an emerging issue⁹.

Multiparametric magnetic resonance imaging (mMRI), which combines T2-weighted (T2W) with dynamic contrast-enhanced (DCE-MRI) and diffusion-weighted imaging (DWI), has an important role for diagnosing and staging PCA^{1,10}. Furthermore, MRI provides an excellent depiction of pelvic anatomy and also predicts the extent of NVB involvement^{8,11-12}. Although MRI is able to assess extracapsular invasion of PCA, the visualization of PNFs remains still difficult^{12,13}. Diffusion tensor imaging (DTI) is a new MRI modality in the field of Neuroimaging, it is noninvasive and provides a sharp depiction of central and peripheral nervous fibers¹⁴⁻²⁴. Recently, it has been shown that DTI, which is based on the sensitivity of "anisotropic diffusion" of the water protons measured in a micro-structural environment of biological tissues, is able to map PNFs^{9,26-8}. Indeed, the anisotropic diffusion represents a condition in which the diffusion of water protons is not casual or "Brownian" but oriented along a determined axis; furthermore, this condition occurs in biological tissues with a strictly orientated texture, such as nervous central and peripheral fibers, including the PNFs¹⁵. DTI is able to quantify this phenomenon throughout the measurement of Fractional Anisotropy (FA) for each single voxel in at least 6 non-collinear and

non-coplanar directions; by the integration of FA of all voxels it becomes possible to represent the direction of nerve fibers in all three dimensions of space, giving both quantitative and qualitative anatomic information. The aim of the study is to evaluate if DTI is able to detect the changes of the PNFs before and after nerve-sparing RARP, and if these changes are related to UI and ED.

MATERIALS AND METHODS

Study population

A prospective study was carried out in collaboration between the Institute of Radiology and the Urology Department of the University of Verona. The study had institutional review board approval. Each patient provided informed consent for all MRI examinations.

In a period ranging from October 2014 to August 2017, the study collected 31 PCA patients underwent RARP with "nerve-sparing" intent. Exclusion criteria were absolute contraindications for the conduct of the MRI, severe post-surgical complications, failure to adhere to 6-month follow-up, disease relapse or death. Patients were classified according to the D'Amico cancer class risk categories²⁹. Clinical staging was computed according to the 2002 American Joint Committee on Cancer staging system for PCA. RARP, which was associated with the unilateral or bilateral nerve-sparing technique, was delivered by the Si da Vinci Robot System (Intuitive Surgical, Inc, Sunnyvale, CA, USA) and was performed through the transperitoneal approach with antegrade prostatic dissection^{30,31}. A transurethral 18 Fr Foley catheter was placed in all cases and the balloon was inflated with 7 cubic centimeters (cc) of physiologic solution. Before March 2017, a postoperative drain was placed in the pelvis, which was removed on a postoperative day (POD) one if the output was less than 150 mL/24 h. If the postoperative outcome was unevent-

Table 1. MRI protocol

Pulse Sequence	Plane	Repetition & Echo Time (ms)	Section Thickness (mm)	FOV (mm)	Flip angle	Duration
T2 TSE	Axial	4100/100	4	380x340	90°	1'30"
T2 TSE (HR)	Sagittal	2650/90	3.5	200x200	90°	1'40"
T2 TSE (HR)	Coronal	2500/100	3.5	160x160	90°	3'25"
T2 TSE (HR)	Axial	3730/90	3.5	160x160	90°	4'10"
DWI	Axial	4000/90	3.5	300x300	90°	7'47"
DTI	Axial	1449/88	3	220x220	90°	3'14"
T1 DIXON Dynamic phase	Axial	4/2	3.5	200x220	90°	3'17"
b-SSFP	Axial	5000/80	6	400x350	90°	51'

ful, patients were discharged on POD 4 with the catheter removed on POD 12 without cystography. Extended PLND was performed according to a standard template, which included the obturator fossa, external, internal and common iliac lymph nodes. The operating time was calculated as the interval between incision of the first laparoscopic port and suture of the last laparoscopic port. The surgical procedures were performed by two experienced surgeons. Prophylaxis of deep venous thrombosis with low molecular weight heparin was performed in all cases elected to RARP with extended PLND and with comorbidity risk factors³⁰. In all cases, early mobilization was activated starting from the day

of surgery (POD 0). Deep venous thrombosis prophylaxis was prolonged till POD 28. In the surgical specimen, tumors were graded and staged according to the modified Gleason score system and TNM classification system¹. All patients, before and six months after surgery, were assessed by the International Index of Erectile Function (IIEF-5 questionnaire)³² and International Consultation Incontinence Questionnaire-Short Form, (ICIQ-SF)³³.

MRI technique with DTI study

All MRI investigations were performed with DTI sequences on 1.5T (Ingenia, Philips Medical Systems, Eindhoven,

Figure 1A. Prostate apex

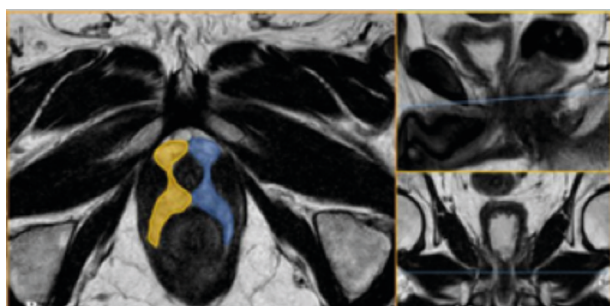


Fig. 1B. Equivalent plane to prostate apex in a post – RP MRI exam

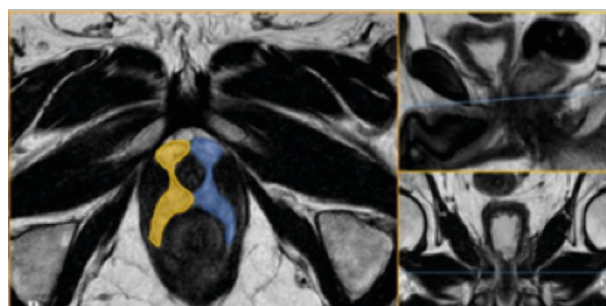


Figure 1C. The middle third of the prostate gland

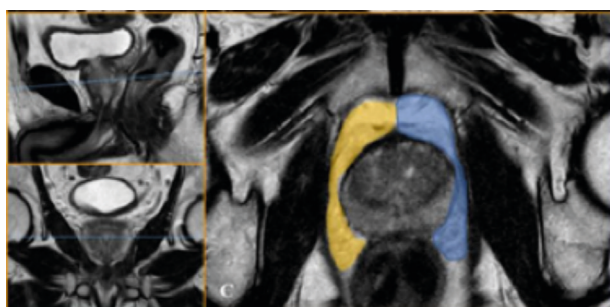


Fig. 1D. Equivalent plane to the third medium in post-RP MRI exam

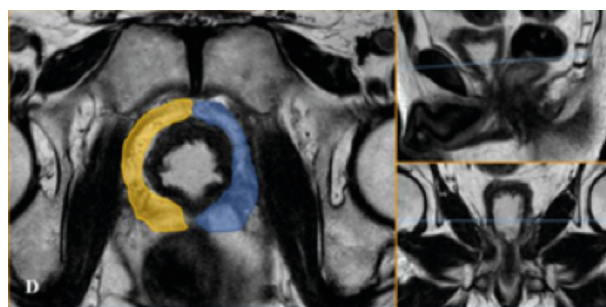


Figure 1E. Prostate base

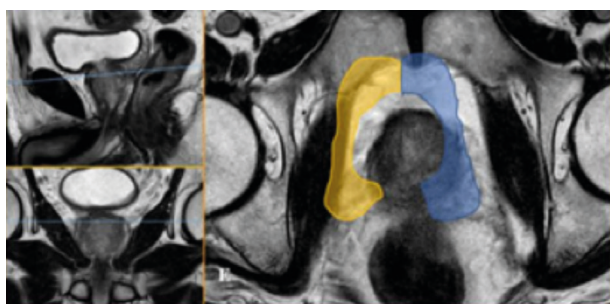


Figure 1F. Plane equivalent to the prostate base in post-RP MRI exam

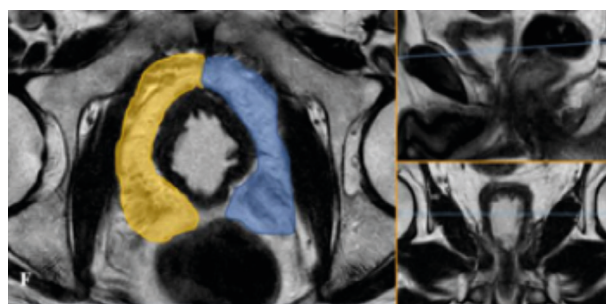


Table 2. Some clinical and pathological characteristics of 31 patients to undergo an radical prostatectomy nerve-sparing

Characteristics	
N. patients	31
Age (years): Mean (\pm SD)	64.03 (\pm 7.05)
Total prostatic volume: Mean (\pm SD)	45.72 (\pm 22.18)
PSA*: Mean (\pm SD)	9.05 (\pm 11.42)
Nerve-sparing right: N. (%)	24 (77.4)
No nerve-sparing right: N. (%)	7 (22.6)
Nerve-sparing left: N. (%)	25 (80.6)
No nerve-sparing left: N. (%)	6 (19.4)
Marginal resection: N. (%)	
Negative	20 (64.5)
Positive	11 (35.5)
Pathological TNM: N. (%)	
pT2aNxMx	3 (9.7)
pT2bNxMx	1 (3.3)
pT2cNxMx	19 (61.2)
pT3aNxMx	4 (12.9)
pT3bNxMx	4 (12.9)
Gleason score: Median (range)	
Sum	7 (4-9)

Netherlands) using a 32 multi-channel surface coil placed on the lower abdomen. All Patients were fasting with solid foods from 4 to 6 hours before the examination. Peristalsis was suppressed by administering 20 mg intramuscular scopolamine butyl bromide (Buscopan, Boehringer Ingelheim, Yamagata, Japan). Patients were asked to empty the bladder about half of its volume in order to limit involuntary movements. The total duration of the examination was approximately 26 minutes.

The individual sequences and their duration are summarized in Table 1. All MRI investigations were evaluated independently at least by two radiologists who received brief training on PNP. For each RM survey, each operator performed at least two sets of measurements. Prior to the reconstruction of the hinterland, an image recording was performed to correct any artifacts from motion. Track reconstructions were performed directly on the MRI control console, using the Philips Fiber Track application includ-

ed in the 4.1.3 release of machine management software by designing regions of interest (ROI) of different shapes in the periprostatic adipose tissue using as reference the T2-dependent axial images fused with the DTI recorded images and taking care of not to include muscle fibers of the bladder or shutter muscles to avoid being included in the reconstruction.

The input parameters assigned to the software to perform the track-back reconstruction were: FA minimum of 0.15, angle threshold of 45 °, and the minimum length of 5 mm. The output parameters calculated by the software were 5 for each ROI: (i) number of nerve fiber reconstructed (N), (ii) number of voxels (V), (iii) mean FA values, (iv) average ADC values, and (v) average length of reconstituted nerve fibers (L). The PNP modifications after RARP were evaluated by using T2-dependent axial images fused with DTI 6 ROI images in the periprostatic adipose tissue for each of the 2 RM controls. The ROIs, subdivided into right and left, have been positioned at three predetermined levels of the prostate: (i) prostate apex and plane equivalent to prostate apex in post RP MRI exam (Figure 1: A, B), (ii) middle third of prostate gland and plane equivalent to the third medium in post RP MRI exam (Figure 1: C, D), (iii) prostate base and plane equivalent to the prostate in post RP MRI exam (Figure 1: E, F).

Statistical analysis

All statistical analyses were performed using SAS statistical software, version 9.4 (SAS Institute, Inc., Cary, NC). Descriptive statistics included frequencies, means values with standard deviation (\pm SD), median and range for continuous variables. Correlation coefficients were calculated using Spearman’s correlation method (r). Results were considered to be statistically significant when $p \leq 0.05$ (two-sides).

RESULTS

The study included 31 patients who were assessed by pre-operative MRI and underwent RARP with nerve-sparing intent. Table 2 shows the clinical and pathologic features of the study population. Mean clinical features were as follows: age 64.03, prostate volume 45.72 cc, total prostate-specific antigen (PSA) 9.05. Neurovascular bundles were preserved on the right and left side in 77.4% and 80.6% of cases, respectively. Involvement of a surgical margin was detected in 11 cases (35.5%). In the surgical specimen, the disease was extraprostatic in 8 cases (28.8%) with extracapsular extension in 4 (12.9%) and seminal vesicle invasion in 4 cases (12.9%). The median Gleason score was 7. Five of the 31 patients were not evaluated by MRI after RARP. Table 3 illustrates the results (mean \pm SD) of MRI measurements related to anisotropic fraction, number and length of fibers for each level of the prostate gland (base, mid-gland and apex) at six months from RARP in 26 patients. In par-

Table 3. Mean and Standard Deviation (\pm SD) of anisotropic fraction, N. of fibers and fibers length for each level of the prostate gland at 6 months from radical prostatectomy nerve-sparing.

	N. patients	Level of prostate gland					
		Base right	Base left	Mid right	Mid left	Apex right	Apex left
		Mean (\pm SD)	Mean (\pm SD)	Mean (\pm SD)	Mean (\pm SD)	Mean (\pm SD)	Mean (\pm SD)
Anisotropic fraction	26	0.46 (\pm 0.05)	0.44 (\pm 0.05)	0.46 (\pm 0.07)	0.46 (\pm 0.05)	0.40 (\pm 0.05)	0.41 (\pm 0.06)
N. of fibers	26	87.35 (\pm 31.35)	90.92 (\pm 31.66)	66.58 (\pm 25.83)	62.15 (\pm 23.82)	42.62 (\pm 16.19)	41.00 (\pm 15.79)
Fibers length	26	13.16 (\pm 2.63)	13.18 (\pm 2.36)	14.17 (\pm 2.96)	13.79 (\pm 2.85)	14.38 (\pm 3.27)	13.84 (\pm 2.95)

Table 4. Pearson correlation coefficients (r) between anisotropic fraction, N. of fibers, and fibers length for each level of the prostate gland and erectile dysfunction at 6 months from radical prostatectomy nerve-sparing.

	Level of prostate gland					
	Base right	Base left	Mid right	Mid left	Apex right	Apex left
N. patients	23	23	23	23	23	23
	Anisotropic fraction (r)					
Erectile dysfunction	-0.42068	-0.66120	-0.25438	-0.37252	-0.38025	-0.38739
	p=0.0456	p=0.0006	p=0.2415	p=0.0800	p=0.0735	p=0.0678
	N. of fibers (r)					
Erectile dysfunction	0.25587	0.30807	0.13434	-0.12201	0.33809	-0.00850
	p=0.2386	p=0.1527	p=0.5411	p=0.5792	p=0.1146	p=0.9693
	Fibers length (r)					
Erectile dysfunction	0.25737	0.19402	0.23542	0.30084	0.42546	0.15761
	p=0.2358	p=0.3750	p=0.2795	p=0.1631	p=0.0430	p=0.4726

ticular, at six months the number of fibers tracts was significantly decreased at base, mid-gland and apex for both right and left side (p= 0.01 – data not shown). Three of the 26 cases who were evaluated by MRI before and six months after RARP did not have nerve-sparing surgery. Table 4 shows correlations of IIEF-5 score with MRI measurements including anisotropic fraction, number and length of fibers for each level of the prostate gland (base, mid-gland and apex) at six months from RARP with nerve-sparing intent in 23 patients. There was a significant negative correlation between IIEF-5 score and anisotropic fraction measurements at both right (Pearson’s coefficient = - 0.420068; p=0.0456) and left (Pearson’s coefficient = - 0.66120; p=0.0006) base of the prostate, respectively. It was not detected any significant correlation between IIEF-5 score and anisotropic fraction at the other levels of the gland as well as the number of fibers. Finally, the IIEF-5 score test correlated positively to the length of fibers located at the right apex of the gland (Pearson’s coefficient = 0.42546; p=0.0430), but no significant correlation was detected at the other levels of the prostate. Table 5 shows correlations of ICIQ-SF score test with MRI measurements including anisotropic fraction, number and length of fibers for each level of the prostate

gland (base, mid-gland and apex) at six months from RARP with nerve-sparing intent in 23 patients. As shown, no significant correlations were detected between ICIQ-SF score with any of the MRI measured parameters including anisotropic fraction, number and length of fibers for each level of the prostate gland.

DISCUSSION

The aim of the present study was to evaluate if DTI is able to detect the changes of the PNFs before and after prostatectomy and if these changes are related to postsurgical complications, such as urinary incontinence and erectile dysfunction. Despite conventional MRI has proven to be a useful modality for the diagnosis of extracapsular invasion of prostate cancer, the visualization of the PNFs remains still difficult^{16,17}. Recently, Diffusion Tensor Imaging (DTI) has been successfully adopted for mapping of the PNFs^{2,30,31}. Although the recent introduction of “nerve-sparing” techniques has shown to be able to reduce the incidence of these complications in comparison with the “non-nerve-sparing” approaches⁵⁻⁸, their incidence is still not negligible and directly related to the number of the preserved fibers during prostatectomy¹⁰⁻¹¹. In our study, in agreement with Kitajima

Table 5. Pearson correlation coefficients (r) between anisotropic fraction, N. of fibers, and fibers length for each level of the prostate gland and incontinence at 6 months from radical prostatectomy nerve-sparing.

	Level of prostate gland					
	Base right	Base left	Mid right	Mid left	Apex right	Apex left
N. patients	23	23	23	23	23	23
	Anisotropic fraction (r)					
Incontinence	-0.14510	-0.23853	0.00781	-0.18938	0.21569	-0.14532
	p=0.5089	p=0.2730	p=0.9718	p=0.3868	p=0.3229	p=0.5082
	N. of fibers (r)					
Incontinence	0.17080	0.15209	-0.06897	-0.00938	0.09586	-0.05818
	p=0.4359	p=0.4884	p=0.7514	p=0.9661	p=0.6635	p=0.7920
	Fibers length (r)					
Incontinence	0.13591	-0.17705	-0.00833	-0.06928	0.09009	0.25777
	p=0.5363	p=0.4190	p=0.9699	p=0.7535	p=0.6227	p=0.2350

et al.², the number of fiber tracts after RARP was significantly decreased at the base, mid-gland, and apex for both right and left side ($p < 0.01$). In this way, an interesting result of our series, which has not been studied before, is exclusively represented by significant negative correlation between IIEF-5 score and anisotropic fraction measurements at both rights ($p = 0.0456$) and left ($p = 0.0006$) base of the prostate. These results allow us to make some considerations. The first of all that the number of fibers is definitely essential for the recovery of erectile function and finally that the persistence of the fractional anisotropy of PNFs at six months is an indicator of probable erectile dysfunction. From a pathophysiologic point of view this aspect could be related to a difficult transmission of the nerve impulse, as normally happens when nerve fibers have a straight course. As known these findings confirm that erection occurs thanks to the preservation of pelvic plexus, as reported in the past by Walsh³⁴, and that sphincteric urethra is not innervated predominantly by autonomic component. On the other hand in our study, this latter aspect is justified by the absence of a clear correlation between fractional anisotropy and urinary incontinence. In this regard, the role of the autonomic nervous component is somewhat uncertain and morphological studies in this direction show that the somatic nervous system, thanks to the pudendal nerve, is the predominant nervous component that is responsible for external sphincter innervation³⁵. In any case, this study shows some limitations. The major one is the potential miscount of nerve fibers because the number of the track on DTI is not the real number of nerve fibers and because linear non-nerve structures such as fibromuscular tissue, arteries, and veins can concur to generate fiber tracts. Finally, the number of patients included in the study is still small and further large-scale prospective studies are needed.

In conclusion, DTI of the periprostatic neurovascular fibers (PNFs) has demonstrated to be a useful and reproducible technique in detecting the changes of the PNFs induced by RARP. In particular, DTI seems to be a fascinating instrumental evaluation that in the future could play the role of predictive investigation for erection recovery after RARP.

REFERENCES

1. EAU - ESTRO - ESUR -Prostate cancer Guidelines 2017.
2. Takenaka A, Leung RA, Fujisawa M, Tewari (2010) Anatomy of autonomic nerve component in the male pelvis: the new concept from a perspective for robotic nerve-sparing radical prostatectomy. *AK World J Urol.* 2006 Jun;24(2):136-43. DOI: 10.1007/s00345-006-0102-2
3. Chabert CC, Merrilees DA, Neill MG, Eden CG (2008) Curtain dissection of the lateral prostatic fascia and potency after laparoscopic radical prostatectomy: a veil of mystery. *BJU Int.* 2008 May;101(10):1285-8. doi: 10.1111/j.1464-410X.2008.07595.x.
4. Vora AA, Marchalik D, Kowalczyk KJ, Nissim H, Bandi G, McGeagh KG, Lynch JH, Ghasemian SR, Verghese M, Venkatesan K, Borges P, Uchio EM, Hwang JJ (2013) Robotic-assisted prostatectomy and open radical retropubic prostatectomy for locally-advanced prostate cancer: multi-institution comparison of oncologic outcomes. *Prostate Int.* 2013;1(1):31-6. doi: 10.12954/PI.12001.
5. Labanaris AP, Witt JH, Zugar V (2012) Robotic-assisted radical prostatectomy in men ≥ 75 years of age. Surgical, oncological and functional outcomes. *Anticancer Res.* 2012 May;32(5):2085-9.
6. Kiyoshima K, Yokomizo A, Yoshida T, Tomita K, Yonemasu H, Nakamura M, Oda Y, Naito S, Hasegawa Y Anatomical features of periprostatic tissue and its surroundings: a histological analysis of 79 radical retropubic prostatectomy specimens. *Jpn J Clin Oncol.* 2004 Aug; 34(8):463-8. DOI: 10.1093/jjco/hyh078
7. Ko WJ, Truesdale MD, Hruby GW, Landman J, Badani KK (2011) Impacting factors for recovery of erectile function within 1 year following robotic-assisted laparoscopic radical prostatectomy. *J Sex Med.* 2011 Jun;8(6):1805-12. doi: 10.1111/j.1743-6109.2011.02237.x.
8. Rabbani F, Stapleton AM, Kattan MW, Wheeler TM, Scardino PT Factors predicting recovery of erections after radical prostatectomy. *J Urol.* 2000 Dec;164(6):1929-34
9. Kitajima K, Takahashi S, Ueno Y, Miyake H, Fujisawa M, Sugimura K Visualization of periprostatic nerve fibers before and after radical prostatectomy using diffusion tensor magnetic resonance imaging with tractography. *Clin Imaging.* 2014 May-Jun;38(3):302-6. doi: 10.1016/j.
10. Weinreb JC, Barentsz JO, Choyke PL, Cornud F, Haider MA, Macura KJ, Margolis D, Schnall MD, Shtern F, Tempany CM, Thoeny HC, Verma S PI-RADS Prostate Imaging - Reporting and Data System: 2015, Version 2. *Eur Urol.* 2016 Jan;69(1):16-40. doi: 10.1016/j.eururo.2015.08.052.
11. Hull GW, Rabbani F, Abbas F, Wheeler TM, Kattan MW, Scardino PT Cancer control with radical prostatectomy alone in 1,000 consecutive patients. *J Urol.* 2002 Feb;167(2 Pt 1):528-34.
12. Bloch BN, Furman-Haran E, Helbich TH, Lenkinski RE, Degani H, Kratzik C, Susani M, Haitel A, Jaromi S, Ngo L, Rofsky NM Prostate cancer: accurate determination of extracapsular extension with high-spatial-resolution dynamic contrast-enhanced and T2-weighted MR imaging - initial results. *Radiology* 2007; 245:176-85. DOI: 10.1148/radiol.2451061502
13. Hricak H, Wang L, Wei DC, Coakley FV, Akin O, Reuter VE, Gonen M, Kattan MW, Onyebuchi CN, Scardino PT The role of preoperative endorectal magnetic resonance imaging in the decision regarding whether to preserve or resect neurovascular bundles during radical retropubic prostatectomy. *Cancer.* 2004; 100(12): p. 2655-63.
14. McClure TD, Margolis DJ, Reiter RE, Sayre JW, Thomas MA, Nagarajan R, Gulati M, Raman SS Use of MR imaging to determine preservation of the neurovascular bundles at robotic-assisted laparoscopic prostatectomy. *Radiology* 2012; 262(3): p. 874-83. doi: 10.1148/radiol.11103504
15. Le Bihan D, Breton E, Lallemand D, Grenier P, Cabanis E, Laval-Jeantet M MR imaging of intravoxel incoherent motions: application to diffusion and perfusion in neurologic disorders. *Radiology.* 1986; 161(2): p. 401-7. DOI: 10.1148/radiology.161.2.3763909
16. Ahn S, Lee SK Diffusion tensor imaging: exploring the motor networks and clinical applications. *Korean J Radiol.* 2012; 12(6): p. 651-61. DOI: 10.3348/kjr.2011.12.6.651
17. Yu CS, Li KC, Xuan Y, Ji XM, Qin W Diffusion tensor tractography in patients with cerebral tumors: a helpful technique for neurosurgical planning and postoperative assessment. *Eur J Radiol.* 2005; 56(2): p. 197-204. DOI: 10.1016/j.ejrad.2005.04.010
18. Jones, D.K. The effect of gradient sampling schemes on measures derived from diffusion tensor MRI: a Monte Carlo study. *Magn Reson Med.* 51(4): p. 807-15. DOI: 10.1002/mrm.20033
19. Yamada K, Kizu O, Mori S, Ito H, Nakamura H, Yuen S, Kubota T, Tanaka O, Akada W, Sasajima H, Mineura K, Nishimura T Brain fiber tracking with clinically feasible diffusion-tensor MR imaging: initial experience. *Radiology* 2004; 227(1): p. 295-301. DOI: 10.1148/radiol.2271020313
20. Okada T, Miki Y, Fushimi Y, Hanakawa T, Kanagaki M, Yamamoto A, Urayama S, Fukuyama H, Hiraoka M, Togashi K Diffusion-tensor fiber tractography: intraindividual comparison of 3.0-T and 1.5-T MR imaging. *Radiology.* 2006; 238(2): p. 668-78. DOI: 10.1148/radiol.2382042192
21. Kulikova S, Hertz-Pannier L, Dehaene-Lambertz G, Buzmakov A, Poupon C, Dubois J Multi-parametric evaluation of the white matter maturation. *Brain Struct Funct.* 2015; 220(6): p. 3657-72. DOI: 10.1007/s00429-014-0881-y
22. Löbel U, Sedlacik J, Güllmar D, Kaiser WA, Reichenbach JR, Mentzel HJ. Diffusion tensor imaging: the normal evolution of ADC, RA, FA, and eigenvalues studied in multiple anatomical regions of the brain. *Neuroradiology.* 2009; 51(4): 253-63. DOI: 10.1007/s00234-008-0488-1
23. Fabri M, Pierpaoli C, Barbaresi P, Polonara G Functional topography of the corpus callosum investigated by DTI and fMRI. *World J Radiol.* 2014. 6(12): p. 895-906. DOI: 10.4329/wjr.v6.i12.895
24. Lin CC, Tsai MY, Lo YC, Liu YJ, Tsai PP, Wu CY, Lin CW, Shen WC, Chung HW Reproducibility of corticospinal diffusion tensor tractography in normal subjects and hemiparetic stroke

- patients. *Eur J Radiol* 2013; 82(10): p. 610-6. DOI: 10.1016/j.ejrad.2013.06.016
25. Vargas MI, Viallon M, Nguyen D, Delavelle J, Becker M Diffusion tensor imaging (DTI) and tractography of the brachial plexus: feasibility and initial experience in neoplastic conditions. *neuroradiology*. 2010; 52(3): p. 237-45. doi: 10.1007/s00234-009-0643-3.
 26. Finley DS, Ellingson BM, Natarajan S, Zaw TM, Raman SS, Schulam P, Reiter RE, Margolis D Diffusion tensor magnetic resonance tractography of the prostate: feasibility for mapping periprostatic fibers. *Urology*. 2012; 80(1): p. 219-23. doi: 10.1016/j.urology.2012.03.027.
 27. Panebianco V1, Barchetti F, Sciarra A, Marcantonio A, Zini C, Saliccia S, Colletini F, Gentile V, Hamm B, Catalano C In vivo 3D neuroanatomical evaluation of periprostatic nerve plexus with 3T-MR Diffusion Tensor Imaging. *Eur J Radiol*. 2013; 82(10): p. 1677-82. doi: 10.1016/j.ejrad.2013.05.013
 28. Farrell JA, Landman BA, Jones CK, Smith SA, Prince JL, van Zijl PC, Mori S Effects of signal-to-noise ratio on the accuracy and reproducibility of diffusion tensor imaging-derived fractional anisotropy, mean diffusivity, and principal eigenvector measurements at 1.5 T. *J Magn Reson Imaging*. 2007; 26(3): p. 756-67. DOI: 10.1002/jmri.21053
 29. D'Amico AV, Whittington R, Malkowicz SB, Schultz D, Blank K, Broderick GA, Tomaszewski JE, Renshaw AA, Kaplan I, Beard CJ, Wein Biochemical outcome after radical prostatectomy, external beam radiation therapy, or interstitial radiation therapy for clinically localized prostate cancer. *JAMA*; 1998; 280:969-74;
 30. Montorsi F, Wilson TG, Rosen RC, Ahlering TE, Artibani W, Carroll PR, Costello A, Eastham JA, Ficarra V, Guazzoni G, Menon M, Novara G, Patel VR, Stolzenburg JU, Van der Poel H, Van Poppel H, Mottrie A Best practices in robot-assisted radical prostatectomy: recommendations of the Pasadena Consensus Panel. *Eur Urol* 2012; 62:368-381. DOI: 10.1016/j.euro.2012.11.036
 31. Menon M, Tewari A, Peabody J Vattikuti Institute prostatectomy: technique. *J Urol* 2003; 169:2289-92. DOI: 10.1097/01.ju.0000067464.53313.dd
 32. Rhoden EL, Teloken C, Sogari PR, Vargas SC The use of the simplified International Index of Erectile Function (IIEF-5) as a diagnostic tool to study the prevalence of erectile dysfunction. *Int J Impot Res* 2002; 14:245-250. DOI: 10.1038/sj.ijir.3900859
 33. Avery K, Donovan J, Peters TJ, Shaw C, Gotoh M, Abrams P ICIQ: a brief and robust measure for evaluating the symptoms and impact of urinary incontinence. *Neurourol Urodyn*. 2004;23(4):322-30. DOI: 10.1002/nau.20041
 34. Rogers CG, Trock BP, Walsh P Preservation of accessory pudendal arteries during radical retropubic prostatectomy: surgical technique and results. *Urology*. 2004 Jul;64(1):148-51. DOI: 10.1016/j.urology.2004.02.035
 35. T, Sooriakumaran P, Takenaka A, Tewari A Neural supply of the male urethral sphincter: comprehensive anatomical review and implications for continence recovery after radical prostatectomy. *Bessede. World J Urol*. 2017 Apr;35(4):549-565. doi: 10.1007/s00345-016-1901

DISCLOSURE STATEMENTS

There was no conflict of interest, informed patient consent was obtained, and the study was approved by the local ethical committee. The authors of the publication did not receive any financial support by any grant/research sponsor

Corresponding Author:

Prof. Salvatore Siracusano
Department of Urology - University of Verona
Piazzale Stefani 1 - 37100 Verona - Italy
email: salvatore.siracusano@univr.it

Multidisciplinary UroGyneProcto Editorial Comment

To improve the integration among the three segments of the pelvic floor, some of the articles published in *Pelviperrineology* are commented on by **Urologists, Gynecologists, Proctologists/Colo Rectal Surgeons or other Specialists**, with their critical opinion and a teaching purpose. Differences, similarities and possible relationships between the data presented and what is known in the three fields of competence are stressed, or the absence of any analogy is indicated. The discussion is not a peer review, it concerns concepts, ideas, theories, not the methodology of the presentation.

Gyneco... In analogy with the surgical procedure of radical prostatectomy, the radical hysterectomy operation for cancer is responsible of numerous negative effects on sexual functioning¹. This is due to the elimination of a large part of pelvic ligaments and pelvic autonomic nerves notoriously involved in clitoral as penile erection (parasympathetic nervous system), and in female orgasm and ejaculation (orthosympathetic nervous system). These autonomic nerves are located in the sacro-coccygeal plexus in the pelvis. Prostate and uterus are organs embriologically correlated, consequently their radical removal causes gender similar sexual, urinary and ano-rectal dysfunctions. In fact women following radical hysterectomy have a high incidence of sexual dysfunctions (sexual desire, sexual arousal, orgasmic, and sexual pain disorders, data obtained by a self-reported sexual function questionnaire). The preoperative, 1- and 2-year postoperative, sexual dysfunction rates were 50.5% , 86.9%, and 92.3% respectively becoming eventually stable as shown

in the recent study of Wang and Chen² and age, preserved ovary, preserved posterior vaginal wall length, preoperative stage, radiotherapy, and education background were risk factors associated with sexual dysfunction. A metanalysis of Xue and Zhu³ demonstrated that the nerve sparing radical hysterectomy was associated with less bladder and ano-rectal dysfunction and a higher score of Femal Sexual Function Index (FSFI) with a similar rate of cancer recurrence. To confirm the result that Siracusano founded in men, it would be very interesting a study on use of Diffusion Tensor Imaging tecnique on MRI in the prognosis of sexual dysfunction after radical hysterectomy.

REFERENCES

1. Danesh M, Hamzehgardeshi Z2, Moosazadeh M3, Shabani-Asrami F4.The Effect of Hysterectomy on Women's Sexual Function: a Narrative Review. *Med Arh*. 2015 69(6):387-392 . doi: 10.5455/medarh.2015.69.387-392
2. Wang X1,2, Chen C3, Liu P1, Li W1, Wang L1, Liu Y1.The

morbidity of sexual dysfunction of 125 Chinese women following different types of radical hysterectomy for gynaecological malignancies. Arch Gynecol Obstet 2018 Feb;297(2):459-466. doi: 10.1007/s00404-017-4625-0. Epub 2017 Dec 27.

3. Xue Z, Zhu X, Teng Y. Comparison of Nerve Sparing Radical Hysterectomy and Radical Hysterectomy: a Systematic Review and Meta-Analysis. Cell Physiol Biochem 2016;38(5):1841-50. doi: 10.1159/000443122. Epub 2016 May 9.

CHIARA ALESSI

Obstetrics and Gynecologic Unit. AO Padova, Italy

Correspondence:

chiara.alessi@aopd.veneto.it

Procto... Surgery for rectal cancer may result in physiologic and psychologic changes that alter a patient's sexual functioning and quality of life. Most studies examine the male sexual issues of erectile dysfunction and retrograde ejaculation, while female sexual dysfunction is relatively ignored. Women with rectal cancer are reluctant to talk about their sexuality, and if they do, it's on dyspareunia. Furthermore, validated instruments for measuring sexual functioning have seldom been used in studies of sexual changes after rectal cancer surgery¹. Data prospectively collected on 295 women who underwent rectal cancer excision², mean age 60.9 years, showed significant impairments in female urinary and sexual outcomes; around half of all cancer survivors experience a decrease in sexual functioning and changes in body image, and with colorectal cancer, the rates can be even higher. In males total mesorectal surgery affects erection and ejaculation in over 82%³. Women after rectal cancer surgery are significantly less likely to be sexually active than prior to surgery, their problems being multi-factorial. The type of surgery

(abdominoperineal excision vs anterior resection) impact sexual function with less frequent coitus, and being less likely to achieve arousal or orgasm.

REFERENCES

1. Samantha K. Hendren, MD,* Brenda I. O'Connor, RN,* Maria Liu, BSc, et al Prevalence of male and female sexual dysfunction is high following surgery for rectal cancer. Ann Surg. 2005; 242(2): 212-223.
2. Tekkis PP, Cornish JA, Remzi FH et al. Measuring sexual and urinary outcomes in women after rectal cancer excision. Dis C R 2009; 52: 46-54
3. Averyt JC, Nishimoto PW . Addressing sexual dysfunction in colorectal cancer survivorship care J Gastrointest Oncol. 2014 Oct; 5(5): 388-394.

GIUSEPPE DODI

Colorectal surgeon, University of Padova, Italy

Correspondence:

giuseppe.dodi@unipd.it

Histopathology findings of the pelvic organ prolapse

FERNANDA M.A. CORPAS¹, ANDRES ILLARRAMENDI²,
FERNANDA NOZAR³, BENEDICTA CASERTA⁴

¹Asistente Clínica Ginecotológica A CHPR, ²Residente de Ginecología, Clínica Ginecotológica A CHPR, ³Profesora Adjunta Clínica Ginecotológica A CHPR, ⁴Jefa del servicio de Anatomía Patológica del CHPR, Presidenta de la Sociedad de Anatomía Patológica del Uruguay, Centro Hospitalario Pereira Rossell (Chpr), Montevideo, Uruguay

Abstract: Pelvic organ prolapse is a benign condition, which is the result of a weakening of the different components that provide suspension to the pelvic floor. Surgical treatment, traditionally involve a vaginal hysterectomy, although over the last few decades the preservation of the uterus has become more popular. The objective of the paper is to analyze the characteristics of those patients diagnosed with pelvic organ prolapse, whose treatment involved a vaginal hysterectomy and its correlation to the histopathological characteristics. Retrospective, descriptive study. Data recovered from the medical history of patients that underwent surgical treatment for pelvic organ prolapse through vaginal hysterectomy, were analyzed in a 2 years period, in the CHPR, and compared to the pathology results of the uterus. At the level of the cervix, 58,2% presented changes related to the prolapse (acantosis, para and hyperqueratosis) and 43,6% chronic endocervicitis. Findings in the corpus of the uterus were 58,2% atrophy of the endometrium, 21% of endometrial polyps and 30,9% leiomiomas and 1 case of simple hyperplasia without cellular atypias. No malignant lesions were found. The pathology results of the uterus reveal the presence of anatomical changes related to the pelvic organ prolapse and in accordance to the age of the patient, as well as associated pathologies to a lesser extent. As we were able to establish, in most cases the removal of the uterus is not due to a pathology of the uterus itself but to a symptom generated by the failure of the suspension system of the pelvis.

Keywords: Genital prolapse; Pelvic Organ Prolapse; Hysterectomy; Conservative treatment; Histopathology

INTRODUCTION

Pelvic organ prolapse is a very common benign condition, unique to the human species, consequence of bipedastation. It is the result of a weakening of the different components that provide suspension to the pelvic floor, affecting the bio-social wellbeing of the woman.

The static of the female genital organs within the pelvis is the consequence between a balance including factors like bipedastation, intrabdominal pressure and structures that provide suspension to the abdominal- pelvic organs. The form and function of these organs is created by a synergy between ligaments, muscles and fascia.

This affliction does not present a clinical-anatomical correlation, that is to say, those symptoms generated by different defects may be very diverse among different patients, existing multiple forms of treatment. Knowing with precision each component of the affected anatomical structures allows to find the origin of the organ dysfunction. The variation of symptoms and cascade of events may be secondary to the sum of small imbalances involving structures that maintain form and function. The severity of these symptoms do not correlate with the severity of the organ prolapse.

Many women are asymptomatic and do not need treatment. The incidence of symptomatic pelvic organ prolapse is approximately 15 %, although it is difficult to estimate due to the lack of methods to evaluate real symptoms and the lack of information regarding patients that in fact make a medical consultation for this matter¹. It is expected that medical consultations due to symptoms regarding pelvic organ prolapse increase over the next few years due to an increase in life expectancy², especially for women over the age of 65³, which means a longer life expectancy post corrective surgery and thus an increase in the possibility of treatment failure and long term complications². This condition presents a recurrence rate in one third of treated patients.

Gynecological consults for problems related to genital prolapse are nowadays more frequent as are greater the expectations and demands in regards to treatment².

There are a great variety of options when it comes to treatment, non surgical (pelvic floor muscle exercises, pessaries), and surgical⁴.

The estimated risk with surgical interventions for prolapse is between 11-19%^{1,3,5,6}, with a 29% risk of a second operation⁶.

Among those prolapsed compartments, the anterior compartment is the most common, three times more frequent than the posterior compartment and two times more than the apical compartment (uterus or vaginal dome). The pelvic organ prolapse is dynamic and in approximately two thirds of woman more than one compartment is involved¹. The probability to develop a grade III or IV prolapse in the female population at some time in their lives is around 3 to 6 %².

The objective of correctional surgery for severe genital prolapse should be the relief of symptoms^{2,6}, maintaining and eventually improving the functionality of the pelvic organs as well as the anatomical reestablishment².

Vaginal hysterectomy, including some type of vaginal dome suspension has traditionally been the most common surgical treatment for prolapse of the uterus^{3,6,7,8}, despite that the descent of the uterus is a consequence and not a cause of the prolapse⁷, but the preservation of the uterus is a technique that is gaining more ground over time^{1,6,8}. Over the last few decades, there have been profound changes among women concerning their beliefs and perspectives towards their sexual and reproductive functionality and many women who undergo genital prolapse surgery wish to preserve their uterus^{7,8}.

At the time of choosing a procedure, various factors should be taken into account such as age, presence of comorbidities, level of physical activity, the patients preference, as well as the surgical experience and preference of the gynecologist³. The objective of this paper is to analyze the clinical and social demographic characteristics of those patients diagnosed with pelvic organ prolapse, who underwent a vaginal hysterectomy and its correlation with the histopathological characteristics of the uterus.

MATERIALS AND METHODS

Descriptive retrospective study. Data taken from medical history charts of patients that underwent a vaginal hysterectomy as a surgical treatment for pelvic organ prolapse and not for pathologies of the uterus itself, between the period

of March 1 2016 through March 1 2017 at the CHPR were analysed and compared to the pathology results of the uterus. The inclusion criteria were those patients who underwent a vaginal hysterectomy as the main treatment for an pelvic organ prolapse .

The variables analyzed among these patients were the age at the moment of consultation, the presence of comorbidities such as hypertension, diabetes, smoking, chronic respiratory disease, body mass index, parity, symptoms that motivated consultation and total grade of organ prolapse, analyzed by component.

RESULTS

55 cases were analyzed. Analysis of the different variables are represented in table 1.

The age range with greater incidence was that between 51 and 69 years (36,4%), followed by 61 to 70 years(30,9%). The forms of presentation were: genital tumor (76,4%) and urinary symptoms (50,9%). 58,2% of patients presented a grade III or IV hysterocoele.

TABLE 1. Demographic characteristics and physical findings in patients.

		N (%)	Middle
Age	≤ 50 years	1 (1.8)	47
	51 – 60 years	20 (36.4)	54.9
	61 – 70 years	17 (30.9)	65.2
	71 – 80 years	16 (29.1)	74.5
	≥ 81 years	1 (1.8)	88
Parity – Vaginal delivery	0	2 (3.6)	-
	1	5 (9.1)	1
	2 – 4	31 (56.4)	2.5
	≥ 5	14 (25.4)	6.6
	No data	3 (5.5)	-
BMI	18,5 – 24,9	3 (5,5)	23,2
	25 – 29,9	8 (14,5)	27
	≥ 30	6 (10,9)	36,3
	No data	38 (69,1)	Σ
Comorbidities	Hypertensión arterial	30 (54,5)	-
	Diabetes Mellitus	8 (14,5)	-
	Smoker	2 (3,6)	-
	Respiratory pathology	3 (5,5)	-
	Dyslipidemia	7 (12,7)	-
	No data	4 (7,3)	-
Symptomatology	Tumoration	42 (76,4)	-
	IU effort	4 (7,3)	-
	IU urgency	8 (14,5)	-
	IU mixed	14 (25,5)	-
	Incontinence gases	2 (3,6)	-
	Incontinence matter	1 (1,8)	-
	Other	4 (7,3)	-
	No data	5 (9,1)	-
Degree of total genital prolapsed	II	10 (18,2)	-
	III	23 (41,8)	-
	IV	17 (30,9)	-
	No data	5 (9,1)	-
Degree of uteri- ne prolapse	II	8 (14,5)	-
	III	16 (29,1)	-
	IV	14 (25,5)	-
	No data	14 (25,5)	-

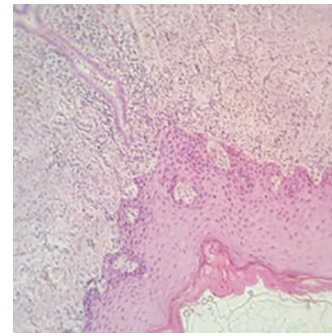


Figure 1. Cervical changes related to the prolapsed

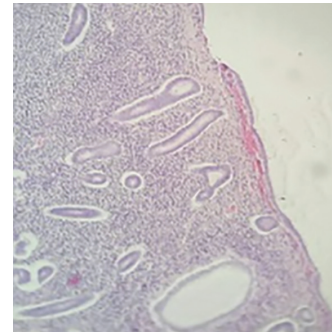


Figure 2. Atrophic endometrium

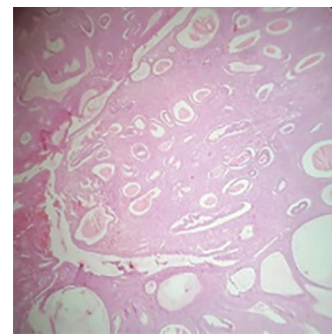


Figure 3. Endometrial polyps

In 50 cases only hysterectomy was performed, in 5 cases hysterectomy with annexectomy, in 2 cases of hysterectomy morcellation corresponding to multiple leiomiomas was performed.

The largest uterine dimension measure was in the range of 35 to 110 mm. The weight in a range that went from 35 to 512 grs. Those greater than 100 grs (7 cases) presented endometrial polyps and/or leiomiomas in posterior studies. At the level of the cervix, 58,2% presented changes related to the prolapse (acantosis, para and hypercheratosis, figure 1) and 43,6% chronic endocervicitis.

Findings in the uterine corpuses were in 58,2% atrophic endometrium (32 cases) figure 2, and 12 cases of endometrial polyps (21%) figure 3, in 17 cases (30,9%) leiomiomas (4 cases associated to polyps) and 1 case of simple hyperplasia without cellular atypias. No malignant lesions were found in this series.

DISCUSSION

The concept that if the uterus is descended it's removal is necessary dates back to the year 1500, considered the hysterectomy in combination with procedures as the primary

procedure of the prolapsed uterus⁹.

Nonetheless, the knowledge of the functional system of support of the pelvic organs, as well as the functional relevance of the uterus beyond its reproductive potential have put and still put to discussion the therapeutic indication of the hysterectomy as a resolution to a hysterocele.

From an anatomical functional point of view, the pericervical ring is a section where main structures come together not only for the suspension of the uterus, but also of the bladder, rectum and Douglas. With this in mind, it is not difficult to imagine the anatomical consequences that a total hysterectomy generates. Thus, the premise of current female pelvic organ prolapse surgery is the preservation and maintenance of function, generating less morbidity. The error perhaps arises in an incorrect diagnostic interpretation of the true structures responsible for the hysterocele, being these the therapeutic objective and not the organ in which its flaw is expressed by.

We must highlight that underestimation of the uterus beyond its reproductive function is not exclusive to physicians, women also consider that a hysterectomy will not affect function or change the anatomical structure¹⁰.

Traditionally, the surgical treatment of patients with prolapse consisted in a vaginal hysterectomy with or without colposuspension techniques. Nevertheless, women present with more frequency an increased desire to preserve their uterus for a variety of reasons.

Even in literature on the matter the effectiveness and effects of a hysterectomy for treatment of a prolapse is debated. Recent literature suggest that the preservation of the uterus is an appropriate option for certain women¹¹ and many of them prefer this⁸.

The analysis of the physiopathology of genital prolapse proposes the question concerning what the best procedure for its correction is². Although hysterectomy is still considered a standard practice for the correction of prolapse, even though the descent of the uterus is a consequence and not a cause of it, over the last decades women's lifestyles, beliefs and perspectives in regard to sexual function and pregnancy have had profound changes and many patients that undergo surgery for the correction of genital prolapse choose to conserve their uterus⁷.

Multiple surgical procedures that conserve the uterus have been described for the correction of an apical prolapse such as: sacrohysteropexia, sacrospinal hysteropexia and procedures based on the use of vaginal surgical meshes, among others^{1,7,8}. The technique may be vaginal, abdominal or laparoscopic¹. Another conservative option is the Manchester Fothergill operation⁷.

The conservation of the uterus is a safe alternative, feasible and effective for women that wish to preserve the uterus^{5,6,12,13}, associating similar results compared to a hysterectomy, both anatomical and functional^{4,12}. Conservative techniques have less morbidity, duration and bleeding, also having the benefit to allow better therapeutic results in the three compartments of the pelvis as well as a smaller chance of recurrence^{14,15,16,17}. There are no differences in results regarding symptoms or concerning the patients satisfaction with the treatment for a prolapsed uterus⁶.

Multiple reasons may be identified in favor of the preservation of the uterus such as: avoiding early and late onset complications of the hysterectomy^{1,3,4,6}, decreasing the rate of erosion of the mesh if used at the time of the hysterectomy¹,

reducing the cost of the surgery due to a shorter surgery, as well as shorter hospital stay^{1,3,4,6,13} and also avoiding the risk of prolapse of the vaginal dome¹. Other reasons are the patients desire to preserve the uterus, either to preserve parity, maintain a personal identity, or cultural and religious considerations¹. The preservation of the uterus contributes positively to the patients self esteem, body image, confidence and sexuality¹.

The Manchester Fothergill Procedure is a good method for uterine preservation, but it elevates the recurrence rate of the prolapse, especially if it is a high grade^{1,5}. It also associates cervical stenosis and its complications such as hematometra and difficulties for the diagnosis of endometrial pathologies^{1,6}.

As a result of the our society's shift in attitude in respect to sexuality and the psychological and emotional value of the sexual organs, is that we should take into consideration the patients wishes to preserve vaginal and uterine functions⁴. An adequate counseling and preoperative evaluation prior to the procedure should be provided⁴.

It is difficult to provide recommendations in this sense due to the fact that there are few high quality studies available. It is in this point in particular that we should take into account that when it comes to surgery it is impossible for class A studies to have not an infinity of confusing variables. Due to current knowledge as well as the need to create surgeries with less morbidity is that we consider that uterine preservation should be a valid option in prolapse surgery.

The risk of not identifying a malignant pathology in the uterus, be it cervical and/or endometrial in patients with a uterine prolapse is low if an adequate preoperative assessment is performed. Even if a hysterectomy or cervical amputation are performed it is recommended that those pieces be sent for pathology study¹⁸.

CONCLUSIONS

The anatomical pathology study of the uterus reveals the presence of anatomical changes related to the pathology and to the age of the patient, as well as associated pathologies to a lesser extent. Although the risk of unidentifying a malignant pathology of the uterus is low, the anatomical- pathology of the surgical piece is recommended.

As we have seen the removal of the uterus in most cases is performed not for the pathology itself but as a symptom of a failure in the suspension system.

REFERENCES

1. Fink K, Shachar IB, Marcus N Uterine preservation for advanced pelvic organ prolapse repair: Anatomical results and patient satisfaction. *Int Braz J Urol*. 2016; 42: 773-8
2. Braun HB, Rojas IT, Gonzalez F et al. Prolapso genital severo: consideraciones clínicas, fisiopatológicas, y de técnica quirúrgica al momento de su corrección. *Rev Chil Obstet Ginecol* 2004; 69 (2): 149-156
3. Detollenaere RJ, den Boon J, Vierhout M et al. Uterussparende chirurgie versus vaginale hysterectomie als behandeling van descensus uteri. *Ned Tijdschr Geneesk*. 2011;155:A3623
4. Kow N, Goldman HB, Ridgeway B Management Options for Women with Uterine Prolapse Interested in Uterine Preservation. *Current Urology Reports*. 2013; 14 (5): 395-402.
5. Marschalek J, Trofaier ML, Yerlikya G et al. Anatomic outcomes after pelvic-organ - prolapse surgery – comparing uterine preservation with hysterectomy. *European Journal of Obstetrics & Gynecology and Reproductive Biology*, 2014; 183: 33-36.

6. Bergman I, Soderberg MW, Kjaeldgaard A, Ek M Cervical amputation versus vaginal hysterectomy: a population-based register study. *Int Urogynecol J* 2017; 28: 257-266
7. Costantini E, Mearini L, Bini V et al. Uterus Preservation in Surgical Correction of Urogenital Prolapse. *European Urology* 2005; 48: 642-649
8. Korbly NB, Kassis NC, Good MM, et al. Patient preferences for uterine preservation and hysterectomy in women with pelvic organ prolapse. *Am J Obstet Gynecol* 2013; 209: 470.e1-6.
9. Swati JHA, Moran PA. National survey of prolapse in the UK. *Neurol Urodyn* 2007; 26: 325-331
10. Good MM, Korbly N, Kassis NC, et al. Prolapse-related knowledge and attitudes toward the uterus in women with pelvic organ prolapse symptoms. *Am J Obstet Gynecol* 2013; 209:481. e1-6
11. Diwan A, Rardin CR, Kohli N. Uterine preservation during surgery for uterovaginal prolapse: a review. *Int Urogynecol J Pelvic Floor Dysfunct*, 2004; 15(4): 286-92
12. Li-Yi Huang, Li-Ching Chu, Hsin-ju Chiang, Fei-chi Chuang, Fu-Tsai Kung, Kuan-Hui Huang. Medium-term comparison of uterus preservation versus hysterectomy in pelvic organ prolapsed treatment with Prolift™ mesh. *International Urogynecology Journal*, 2015; 26 (7): 1013-1020
13. Zucchi A, Lazzeri M, Porena M et al. Uterus preservation in pelvic organ prolapse surgery. *Nature Reviews Urology* 2010; 7: 626-633
14. Maher CF, Cary MP, Slack CJ, Murray CJ, Milligan M, Schluter P. Uterine preservation or hysterectomy at sacrospinous colpopexy for uterovaginal prolapse. *Int Urogynecol J* 2001; 12: 381- 385
15. Brummen HJ, van de Pol G, Aalders CIM, Heintz APM, van der Vaart CH. Sacrospinous hysteropexy compared to vaginal hysterectomy as primary surgical treatment for a descensus uteri: effects on urinary symptoms. *Int Urogynecol J* 2003; 14: 350-355
16. Dietz V, Schraffordt Koops S, Van Der Vaart H. Vaginal surgery for uterine descent; which options do we have? A review of the literature. *Int Urogynecol J* 2009; 20: 349-356
17. Farthmann J, Watermann D, Erbes T, Roth K, Nanovska P, Gitsch G, Gabriel B. Functional outcome after pelvic floor reconstructive surgery with or without concomitant hysterectomy. *Arch Gynecol Obstet* 2015; 291:573-577
18. Wan OY, Cheung RY, Chan SS, Chung TK. Risk of malignancy in women who underwent hysterectomy for uterine prolapse. *Aust N Z J Obstet Gynaecol*. 2013; 53(2): 190-6 characteristics of the uterus.

Disclosure Statements

There was no conflict of interest and the authors of the publication did not receive any financial support by any grant/research sponsor.

Correspondence to:

Andres Illarramendi - gregorio suarez 2723/901
Montevideo 11100 MO - Uruguay
E-mail: fernandanozar@gmail.com

Bilateral Sacrospinous Colposuspension (BSC) for the treatment of vaginal vault prolapse – description of a novel method

DIRK G. KIEBACK

Interdisciplinary Pelvic Floor Center, Department of Obstetrics and Gynecology
Diakonissenkrankenhaus Flensburg, Flensburg, Germany

Abstract: Vaginal vault prolapse is observed with increasing frequency in the era of large ageing populations. Various surgical techniques have been established, varying in performance, difficulty and outcome, specifically complications. A bilateral sacrospinous colposuspension technique (BSC) with a corresponding mesh prosthesis was developed using a direct I-Stitch fixation of the 38 microgram mesh from the vaginal apex or uterine cervix to the sacrospinous ligament or the parasacral tendinous region for the treatment of an anatomical central pelvic floor defect. As a minimally invasive approach with the potential for conservation of the uterus, this technique should be applicable to all age groups including the increasingly frequent elderly patient with significant co-morbidities.

Keywords: Bilateral sacrospinous colposuspension; Operative therapy; Single incision; Vaginal mesh placement; Vaginal vault prolapse; Macroporous; Lightweight

INTRODUCTION

Vaginal vault prolapse is a known clinical entity observed increasingly frequently in the era of large aging populations¹. Historically, treatment options included abdominal surgical interventions such as sacrocolpopexy or fascial slings^{2,3}, and operations via the vaginal approach such as the unilateral Amreich-Richter operation with the vaginal apex sutured to the sacral bone after hysterectomy⁴. More recently, extensive reconstructions using prosthetic mesh for the induction of neo-ligaments and neo-fasciae have been advocated⁵, sometimes also in the context of primary surgical interventions in the untreated patient⁶.

Intravaginal slings (IVS) placed transischiorectally have been proposed by Petros and Farnsworth and shown to be promising in a small series of cases^{7,8}. However, rectal injury and erosions were identified as major problems of this technique which led to the abandonment of IVS⁹. A multi-center series in Austria yielded better results but still described severe complications¹⁰.

It appears that total lack of a formalized anatomically based procedure was a major contributing factor to these unfavorable outcomes, as well as a deficit of education in potential surgeons, potentially even amplified by encouragements and assurances of “simplicity” by the manufacturers. Several parts of the technical description itself already harbored the potential for major complications, for example the para-anal entry point at the six o’clock position where the rectal arteries is found.

In the development of our refined transperineal bilateral sacrospinous colpofixation (TPBCF) technique, we have successfully optimized the surgical procedure of transperineal vaginal sling placement regarding the anatomical and clinical outcome and the potential for complications. Details were published recently^{11,12}.

With the advent of the i-Stitch instrument, finger-guided placement of sutures in the pelvis without extensive dissection became a reality. Equally, lightweight polypropylene mesh as described for the InGynious Mesh¹¹ became available.

These two factors lead to the development of the BSC-Mesh abolishing the transperineal phase of the TPBCF in favour of a direct i-Stitch-sutured fixation to the sacrospinous ligament or to the more cranially located parasacral tendinous insertion of the pelvic floor muscles. The weight of the material was significantly reduced in comparison to the transperineal tape, as no pull-through forces need to be applied in the direct approach. Anatomical studies lead to the deter-

mination of the width of the apical part of the BSC Mesh as well as the angle of the “arms” leading to the points of fixation in the pelvis. These arms were given extra length for adaptability of the positioning of the vaginal apex to the individual pelvic anatomy.

SURGICAL TECHNIQUE

Step 1: Pre-operative treatment

Each patient is treated with vaginal or systemic estriol application for four weeks before surgery. Single dose antibiotic prophylaxis with a combination of a cephalosporin and metronidazole is administered i.v. half an hour before starting the procedure. The vagina is thoroughly disinfected with copious amounts of antiseptic solution during the initial phase of the operation. The anus is thereafter covered with an adhesive sterile impermeable membrane and thereby sealed off from the operative field.

Step 2: Incision in the posterior vaginal wall

A longitudinal incision is made in the midline of the posterior vaginal wall 3 cm distal to (not at) the vaginal apex. The injection of vasoconstricting medication under the vagina before incision may be considered, is, however, by no means necessary as significant bleeding is the exception when choosing this approach.

Step 3: Access to the sacrospinous ligament

A canal designated to admit the index finger of the surgeon is formed by advancing Metzenbaum scissors immediately under the vaginal wall horizontally in the direction of the pelvic side wall. By inserting the finger, a direct access to the sacrospinous ligament can thereafter be developed by blunt dissection. No extensive mobilization of tissue planes or retractor placement, nor visualization of the target structure is required at this point.

Step 4: Dissection of a horizontal space under the cranial vaginal tissue

From the upper end of the longitudinal vaginal incision, the tissues of the rectovaginal septum are dissected off the posterior aspect of the vaginal wall. This will facilitate the subsequent attachment of the prosthetic tape under the intact vagina, thereby removing it from the incision and thus from potential contamination during wound healing and physiological inflammatory reactions, which both would




Figure 1: Original BSC-Mesh

predispose the tape to erosion. If the uterus remains in situ, the space is developed with the goal to expose the posterior surface of the cervix for later tape attachment.

Step 5: Choosing the future fixation points for the BSC Mesh

It is a matter of personal preference, on which side the i-Stitch suture is placed first. Being right-handed, we have mostly placed it first on the right side of the patient and then on the left. This means that the I-Stitch instrument is guided to the surgeon's index finger that is placed on the desired fixation point. We found it advantageous to advance it with the tip up, then turn it to the tissue immediately after anchoring. This minimized tissue resistance during placement. The internal index finger thereafter pushes the tip of the I-Stitch firmly into the tissue, (not the external hand holding the i_stitch instrument), the suture is advanced into the receiving groove, the hollow guiding needle is retracted, the instrument is removed and the suture tested for stability to traction. The sutures are not knotted but guided laterally to the thighs of the patient where they are held i.e. by short Kocher clamps.

Step 7: Fixation of the tape to the underside of the vaginal apex or the posterior aspect of the cervix

It is probably a more philosophical question, whether one should use resorbable or permanent suture for fixing the tape to the underside of the vagina. In an effort to assure suture stability during fibroblast invasion of the graft, while at the same time avoiding permanent multi-knotted strings under the vaginal skin, we have adopted the use of non-resorbable polypropylene threads (USP 3-0) for this purpose.

Two sutures are placed, the first and second in the midline, the second and third 2-3 cm lateral on either side of the midline ("turning point sutures"). The suture technique involves prepositioning of the sutures holding them i.e. with short Kocher clamps centrally and i.e. Overholt forceps laterally for distinction of the sutures during later threading.

As a result six sutures will have been placed for the fixation of the BSC-Mesh: Two I-Stitches (one on each side), two median ones, and two lateral "turning point" ones (one on each side). An identical approach is used when fixing the mesh to the posterior cervix.

Step 8: Threading the sutures through the mesh

The prepositioned sutures are threaded through the mesh from posterior to anterior: The two median sutures first with one thread of each suture on one side of the central marking on the tape, the other on the other side. Again, after threading the sutures are held with the respective clamps and not yet tied. This is followed by guiding the two lateral files

through the mesh in the same posterior to anterior direction at the turning point of the U-shaped BSC Mesh from the nearly horizontal part to the straight part of the "arms". Finally, the I-Stitch sutures are threaded through the mesh at an individually chosen distance from the turning point sutures adapting the later tension of the suspension to the individual anatomical circumstances.

Step 9: Tying of the sutures

The median sutures are tied and cut short first, bringing the mesh in contact with the patient's tissue for the first time. We have found it practical to tie the most cranial of the two median sutures first followed by the second. Thereafter the two turning point sutures are knotted and cut short. The two "arms" of the mesh can now be guided into the designated spaces towards the fixation points. Before tying the I-Stitches we place and tie a braided resorbable suture USP 2-0 across the cranial angle of the colpotomy facilitating later closure after the prolapse is resolved.

In a final step, the two I-Stitch sutures are tied in the process re-elevating the vaginal apex (Figure 2) or the cervix (Figure 3) to their original physiological position.

The vaginal incision is closed with the pre-positioned running suture.

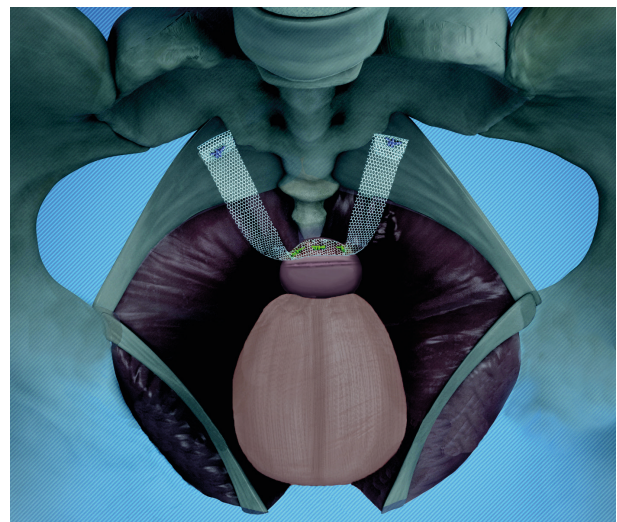
Step 10: Preparation for postoperative care

At the end of the procedure, a vaginal gauze pack liberally coated with estriol ointment is inserted into the vagina over night together with a Foley catheter for bladder drainage. If outpatient treatment is desired, which is definitely an option due to the excellent tolerability of the intervention, this step can probably be safely omitted. In any case, weekly vaginal estriol applications are prescribed, as known from other clinical management guidelines after vaginal mesh placement.

DISCUSSION

Fascia lata slings and suspension procedures using the round ligaments have been abandoned as have resorbable meshes due to the fact, that the body does not maintain neo-ligaments without continuing stimulation of fibroblasts on site. Sacrocolpopexy with or without prosthetic mesh interposition should be combined with a Burch procedure for optimal results as shown by the studies of the NIH Pelvic Floor Disease Network¹³⁻¹⁵. In sum, this amounts to a significant surgical intervention with laparoscopic techniques adding

Figure 2: BSC of the vaginal apex after hysterectomy



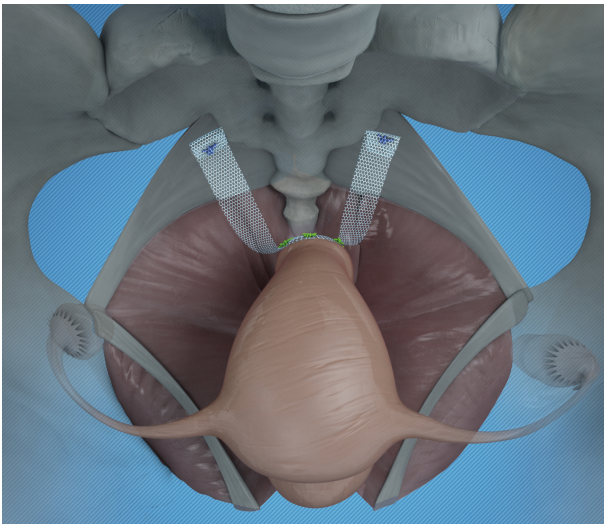


Figure 3: BSC conserving the uterus

their own spectrum of possible complications due to their transabdominal nature.

Amreich-Richter results are known for their surgery-induced dyspareunia, deep pelvic pain and secondary urinary continence problems¹⁶ making them unattractive especially for, but not limited to, the younger patient. While having been in clinical use for a long time, systematic studies of this entity are few. Modifications using unilateral or bilateral non-resorbable sutures that serve as fixing strings suspending the vaginal apex at a distance from the sacrum have never been formally evaluated and remain experimental with anecdotal results.

Large prosthetic implants as a primary treatment approach for female genital prolapse are meeting with increased scepticism due to their potential for complications. The FDA has recently issued a statement to the effect, that large meshes are contraindicated as primary treatment in such situations¹⁷. The TPBCF approach outlined before offered the potential for the generation of an anatomy-analogous support of the vaginal vault or the uterus mimicking the sacrospinous ligaments or creating sacro-vaginal ligaments in its place. Its role is limited by the transperineal phase with its own potential side effects and the requirement of a more densely woven material in order to withstand the traction forces during placement. By contrast the total weight of the foreign material employed in the BSC Mesh is 38 micrograms making it weigh the equivalent of a 0-0 suture used during the Amreich Richter procedure and less than the average postal stamp.

Using suturing instead of an anchor system for fixation inside the pelvis allows for repositioning of the suture if the surgeon is not satisfied with the position of the anchor point after the first placement or the stability to traction is deemed unsatisfactory. Palpatory selection of the anchor point and direct digital control of the suturing results in optimal safety. The indication for BSC is vaginal vault or uterine prolapse, it is not designed to correct anterior, posterior or lateral pelvic floor defects. As a minimally invasive approach with the potential for conservation of the uterus BSC would potentially be applicable to all age groups and from the increasingly frequent elderly patient with significant co-morbidities to the younger woman desiring restoration of a physiological anatomy with minimal use of foreign material.

BSC-Mesh placement can be combined with an anterior and/or posterior colporrhaphy. If indicated, this step should be

performed first, as the performance of vaginal reconstruction becomes markedly more cumbersome after correction of the prolapse.

REFERENCES

1. Wilkins MF, Wu JM. Lifetime risk of surgery for stress urinary incontinence or pelvic organ prolapse. *Minerva Ginecol* 2017;69:171–7.
2. Takacs EB, Kreder KJ. Sacrocolpopexy, Surgical Technique, Outcomes, and Complications. *Curr Urol Rep* 2016;17:90.
3. Ijland MM, Fischer D-C, Kieback DG, McGrath G, Farnsworth B. Midline intravaginal slingplasty for treatment of urinary stress incontinence. Results of an independent audit up to 2 years after surgery. *Int Urogynecol J Pelvic Floor Dysfunct* 2005;16:447–54.
4. Lantzsch T, Goepel C, Wolters M, Koelbl H, Methfessel HD. Sacrospinous ligament fixation for vaginal vault prolapse. *Arch Gynecol Obstet* 2001;265:21–5.
5. de Ridder D. Should we use meshes in the management of vaginal prolapse? *Curr Opin Urol* 2008;18:377–82.
6. Dias FGF, Dias PHGF, Prudente A, Riccetto C. New strategies to improve results of mesh surgeries for vaginal prolapses repair—an update. *Int Braz J Urol* 2015;41:623–34.
7. Farnsworth BN. Posterior intravaginal slingplasty (infracoccygeal sacropexy) for severe posthysterectomy vaginal vault prolapse—a preliminary report on efficacy and safety. *Int Urogynecol J Pelvic Floor Dysfunct* 2002;13:4–8.
8. Petros PP. Medium-term follow-up of the intravaginal slingplasty operation indicates minimal deterioration of urinary continence with time. *Aust N Z J Obstet Gynaecol* 1999;39:354–6.
9. Feiner B, Jelovsek JE, Maher C. Efficacy and safety of transvaginal mesh kits in the treatment of prolapse of the vaginal apex, A systematic review. *BJOG* 2009;116:15–24.
10. Bjelic-Radisic V, Hartmann G, Abendstein B, Tamussino K, Riss PA. The posterior intravaginal slingplasty operation, Results of the Austrian registry. *Eur J Obstet Gynecol Reprod Biol* 2009;144:88–91.
11. Brandt A, Ulrich D, Kuszka A, Niesel A, Lutz H, Funfgeld C, Kieback DG. Treatment of pelvic organ prolapse using a lightweight modified HexaPro Mesh. *Pelviperiineology* 2018; 37/2: 39-41
12. Buerkle B, Ollig S, Kieback DG. Transperineal Bilateral Sacrospinous Colpofixation (TPBCF) for the treatment of vaginal vault prolapse – description of a refined method. *Pelviperiineology* 2018; 37/2: 49-52
13. Brubaker L, Cundiff GW, Fine P, et al. Abdominal sacrocolpopexy with Burch colposuspension to reduce urinary stress incontinence. *N Engl J Med* 2006;354:1557–66.
14. Barber MD, Brubaker L, Burgio KL, et al. Comparison of 2 transvaginal surgical approaches and perioperative behavioral therapy for apical vaginal prolapse, The OPTIMAL randomized trial. *JAMA* 2014;311:1023–34.
15. Barber MD, Brubaker L, Nygaard I, et al. Defining success after surgery for pelvic organ prolapse. *Obstet Gynecol* 2009;114:600–9.
16. Kraus P, Krofta L, Krčmář M, et al. Řešení sestupu tří kompartmentů pomocí syntetického implantátu a sakrospinózní fixace, Kohortová prospektivní studie s délkou follow-up pěti let [The results of five years follow-up prospective study of vaginal prolapse repaired by prolift total mesh surgery or sacrospinous fixation]. *Ceska Gynecol* 2017;82:277–86.
17. FDA. Urogynecologic Surgical Mesh: Update on the Safety and Effectiveness of Transvaginal Placement for Pelvic Organ Prolapse, 2011. (<https://www.fda.gov/downloads/MedicalDevices/Safety/AlertsandNotices/UCM262760.pdf>).

ACKNOWLEDGEMENTS AND DISCLOSURES

The author is member of the Speaker's Board of A.M.I. Austria and receives inventor's royalties from the same source.

Correspondence:

Dirk Kieback
Interdisciplinary Pelvic Floor Center
Department of Obstetrics and Gynecology
Knuthstrasse 1 - D-24939 Fuensburg - Germany
E-mail: dirkkieback@hotmail.de

Introducing a new service of a midwife-led telephone follow-up clinic for 3a & 3b Obstetric Anal Sphincter Injury: retrospective service evaluation and patients' satisfaction survey

SAMI SHAWER¹, SAMREEN INNAYAT¹, HALEY HUTCHINSON², PAUL BALLARD²
AND AETHELE KHUNDA²

¹ North Tees and Hartlepool NHS Foundation Trust,

² South Tees NHS Foundation Trust

Diakonissenkrankenhaus Flensburg, Flensburg, Germany

Abstract: *Background* Most patients with 3a and 3b perineal tears will be asymptomatic. The need for all patients to attend a hospital appointment can be questioned. We set up a midwife-led telephone review clinic for such injuries. We aim to evaluate this service by auditing it and also by analysing patients' satisfaction through a patient satisfaction survey. *Methods* We performed retrospective analysis of the patients' notes over 18 months. We evaluated this service by auditing its adherence to specified standards within the local guidelines and by performing a patients' satisfaction survey of the new service via anonymised postal Friends and Family test. *Results* We looked at 66 sets of notes, of which 48 had datasets with complete clinical/symptomatic data. 14/21 3a and 17/27 3b OASI were asymptomatic and discharged. Only 3 patients with 3a tear and 6 with 3b tear were referred to the consultant-led clinic. From 89 patients who had a midwife-led telephone clinic, 21 responded to the postal survey (23.6%). Two had not received their telephone appointment. 17/19 (89.4%) responded very good or good to the question 'how well do you think your questions and concerns were addressed'. 16/19 (84.2%) responded extremely likely or likely to the question 'how likely are you to recommend this service to friends and family'. *Conclusions* A midwife-led telephone follow-up clinic for patients who sustained 3a and 3b tears seems to be an acceptable service for these patients with high satisfaction rate. We believe that this service has the potential to save time and resources for both patients and healthcare providers.

Keywords: Midwife-led; Perineal clinic; OASI; OASIS; Telephone clinic

INTRODUCTION

The reported incidence of Obstetric Anal Sphincter Injury (OASI) appears to have tripled between 2000 and 2012 from 1.8% to 5.9%, and much of this is likely to be due to better recognition¹. The overall incidence is 6.1% in primiparas and 1.7% in multiparas².

The Royal College of Obstetricians and Gynaecologists (RCOG) guideline has recommended a system for grading the perineal tears³. Approximately 80% of injuries are 3a and 3b tears, and the rest are 3c and 4th degree tears^{4,5}.

The data on the presence of symptoms varies enormously. The presence of symptoms in those with a 3a and 3b injuries can be as high as 31.7% at 3 months postnatal⁴ and as little as 7% at 6 months postnatal⁵ and by far the most common symptom being faecal urgency.

The RCOG guideline recommended that all patients with OASI should have follow-up appointment by clinicians with a special interest in OASIS. However, it did not comment on different methods of follow-up or care for different grades of OASI. The need for routine hospital review of all women with 3a injuries has been called into question, and given that only 8.6% of 3b injuries are symptomatic at 6 months⁵, hospital follow-up may not be required in this subgroup either.

We introduce a new service of a midwife-led telephone follow-up clinic for all patients who sustained 3a and 3b tears. We aim to evaluate this service by auditing its adherence to specified standards within the local guidelines and also by analysing patients' satisfaction with this service through an anonymous patient satisfaction survey.

MATERIALS AND METHODS

The Clinic Process

We introduced the midwife-led telephone follow-up clinic for patients suffering from 3a and 3b OASI in September 2013. This clinic is led by three midwives (band 6/7), who are already

trained to discuss Obstetric trauma and morbidity for the 'Talking about Birth' (TAB) clinic. They use a set proforma to assess and counsel patients over the telephone.

Prior to discharge, all patients who sustained a third or fourth degree tear were provided with a patient information sheet on OASI and pelvic floor muscle exercises.

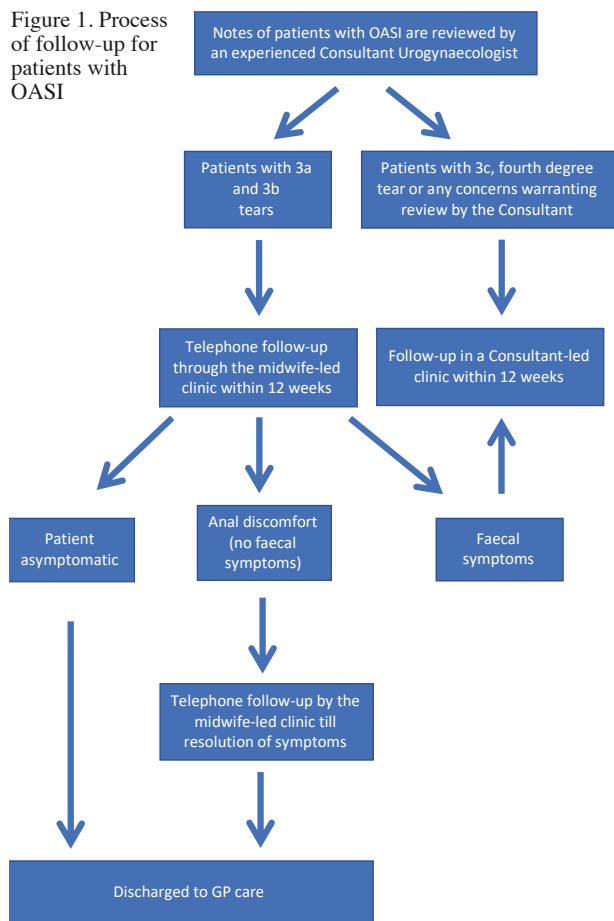
After discharge, all the notes were reviewed by a consultant urogynaecologist with an interest in pelvic floor trauma. Patients with 3a and 3b tears were scheduled to have a midwife-led telephone appointment at 12 weeks postpartum unless they didn't speak English, or if there were any specific reasons warranting their review by a consultant.

An appointment time and date were sent out with the appropriate explanation to be near the telephone and allow minimum of 10 minutes either side of the appointment time. If the midwife could not speak to the patient on the telephone despite trying twice over a 10 minutes period, the patient was sent a further appointment. If on this occasion there was no reply, the patient was classified as having defaulted the appointment (DNA) and therefore discharged back to primary care (Fig. 1).

The telephone discussion included faecal symptoms, pain, intercourse, debrief of the trauma and options for future deliveries. Patients were informed that if they had no symptoms, the chance of developing new symptoms after a further vaginal delivery was low and further discussion regarding mode of delivery could take place in the future pregnancy when other factors could be considered, before the final decision was made. All patients were given the option of attending the consultant clinic if they wished.

All patients who had ongoing faecal symptoms at first review were referred to the consultant clinic. Those with anal discomfort but no faecal symptoms received further telephone reviews from the midwife until resolution and discharge or referral to the consultant. The degree of bothersomeness on a 0-10 analogue scale was recorded for faecal incontinence, faecal urgency, flatal incontinence and perineal pain for each patient.

Figure 1. Process of follow-up for patients with OASI



The Database:

An OASI database had been kept by the trust just prior to the set-up of the midwife-led telephone clinic, to enable contemporaneous audit. This database continued to be used during the period of the study. As part of this service evaluation, we evaluated the outcome data from the database for the index period: 1st January 2014 – 30th June 2015.

The Audit:

The primary standard in this audit of the midwife-led clinic was that all women who had faecal symptoms should be offered a consultant clinic appointment – standard 100%. An additional standard was that 90% of women should have documentation that the mode of delivery was discussed. We

felt that 100% adherence would not be proper for this latter standard as there might be circumstances when it would be inappropriate to discuss this at first consultation.

We performed retrospective data collection for 66 patients (random sample of notes) who sustained OASI in the period from 1st of January 2014 to 30th of June 2015, who had an appointment with the midwife-led telephone clinic, to establish whether these standards had been met. The patients were identified by using our clinic management IT system Camis.

Postal satisfaction survey:

All the patients who had scheduled follow-up by the midwife-led clinic received a trust produced anonymised postal patient satisfaction questionnaire six months following delivery, which included the ‘friends and family’ test (www.england.nhs.uk/ourwork/pe/fft/) with a stamped addressed envelope for its return.

Audit department permission was granted for the notes review and the postal questionnaire. Ethics approval was not required as all data was anonymised for the audit.

RESULTS

1. Outcome data from the database for index period

During the 18 month period under review, there were 6708 deliveries out of which 5339 were vaginal. 147 women sustained OASI which constituted 2.7% of vaginal deliveries. 54 injuries were 3a (36.7%), 59 were 3b (40.1%), 19 were 3c (12.9%), 15 were 4th degree OASI (10.2%).

During that period, 89 of 113 3a and 3b OASI patients were scheduled as new patients for the telephone clinic and the remaining 24 were scheduled for the consultant clinic for various reasons as above. Of the 89 listed for the telephone clinic, 23 (26.1%) ‘did not attend’ (DNA) and an additional 15 patients were scheduled as follow up within the index period, of whom 1 did not attend (6% DNA rate).

Table 1 and Table 2 describe the patients’ demographics and symptoms at the first review respectively.

2. Audit of midwifery clinic adherence to guidelines

We looked at 66 sets of notes, of which 48 had datasets with complete clinical/symptomatic data. In the remaining 18 sets of notes, clinical data were missing for a variety of reasons (see below).

3a Injuries: There were 21 patients who had sustained a 3a OASI, of whom 14 (66.6%) were completely asymptomatic at telephone follow-up and discharged. Seven patients were symptomatic at telephone follow-up, 3 of whom were

Table 1. Graded Obstetric Anal Sphincter Injury for the period 01.01.14 – 30.06.15. Total Unit data collected from local OASI database

	3a (n=54)	3b (n=59)	3c (n=19)	4 (n=15)
Proportion of vaginal deliveries - 5339	1.01%	1.11%	0.36%	0.28%
Proportion of all OASI	36.7%	40.1%	12.9%	10.2%
Age (years) – mean (range)	27.6 (19 – 37)	28.5 (20 – 42)	29 (17 – 35)	28.7 (20 – 33)
Parity	0 = 39 1 = 14 2 = 1	0 = 49 1 = 9 2 = 1	0 = 16 1 = 3 2 = 0	0 = 9 1 = 4 2 = 2
Previous 3 rd degree Tear	4	0	1	0
Mode Of Delivery	Normal = 40 Forceps = 14 Ventouse = 0	Normal = 23 Forceps = 30 Ventouse = 6	Normal = 14 Forceps = 4 Ventouse = 1	Normal = 10 Forceps = 4 Ventouse+forceps = 1
Birth Weight (g) – mean (range)	3654 (2260 – 4600)	3634 (2350 – 4595)	3516 (2910 – 4255)	3690 (2685 – 4375)
Episiotomy rate	16 (29.6%)	18 (30.5%)	6 (31.6%)	6 (40%)

Table 2. Symptoms at First Review for all patients (Total unit data collected from local OASI database) during index period. Symptoms bothersomeness graded 0 – 10, 0 = no bother, 10 = maximum bother.

Grade of OASI	3a	3b	3c	4
No. patients in group	54	59	19	15
No. patients with symptom data	35	41	12	13
No. patients with faecal incontinence	2 (5.7%)	3 (7.3%)	1 (8.3%)	1 (7.7%)
Faecal incontinence bother – Mode	2	4	7	3
Median	2	4	7	3
Interquartile range	2,2	4,1		
No. patients with faecal urge	4 (11.4%)	13 (31.7%)	4 (33%)	3 (23%)
Faecal urge bother – Mode	2	3,9	4	5
Median	4	6	5	5
Interquartile range	2,6	3,9	4,6	4,5
No. patients with flatal incontinence	1 (2.9%)	11 (28.6%)	3 (25%)	3 (23.1%)
Flatal incontinence bother – Mode	2	7	1	
Median	2	7	1	2
Interquartile range		3,7	1,6	2,5
No. patients with pain	5 (14.3%)	10 (24.4%)	3 (25%)	1 (7.7%)

referred on to the consultant clinic. Of the 4 patients ultimately discharged by the midwife clinic, 3 had discomfort around the anal area, which on subsequent telephone review had resolved, the fourth in addition to discomfort also described flatal incontinence but declined further review. Of the 3 patients referred to the consultant clinic, 2 had faecal urgency and the other had pain in the perineum.

The documentation suggests that 19 of the 21 patients had a discussion about the next delivery.

3b Injuries: there were 27 patients who sustained a 3b OASI, of whom 17 (62.9%) were completely asymptomatic at telephone review and discharged. Of the 10 patients who had symptoms, 6 were referred on to the consultant clinic. Of the 4 patients discharged by the midwife, 1 had faecal urgency but declined further follow-up, 1 had pain and rectal bleeding and was referred on to the GP, 1 had rectal bleeding and declined further follow-up and the last one had faecal urgency and rectal bleeding and her outcome was uncertain (inadequate documentation).

Of those 6 patients referred to the consultant clinic, 2 had faecal urgency (1 of whom did not attend the consultant appointment), 1 had flatal incontinence (she did not attend the

consultant appointment), 2 patients had faecal incontinence, faecal urgency and flatal incontinence, and a one patient had a ‘bulge in her perineum’.

The documentation suggests that 24 of the 27 patients had a discussion about the next delivery.

Therefore, in 1 of the 17 symptomatic patients with a 3a or 3b OASI, there is uncertainty from notes review, as to whether they were offered a consultant review, giving a 94.2% adherence to the first standard. In addition, there was evidence of a discussion regarding mode of delivery in 89.6% notes.

Of the 18 sets of notes where there was incomplete data, 11 patients missed their telephone appointments on 2 occasions and were discharged. In 2 notes, the OASI pathway was missing, 2 patients declined follow-up. And in the remaining 3 patients, there was inadequate documentation by the midwife. Overall, when the OASI pathway document was present, there were 4 (6.3%) notes out of the 64 where the documentation was inadequate to determine whether the patient should have been, or was offered a consultant review.

3. Postal satisfaction survey of the midwife-led telephone OASI service

Of the 89 patients scheduled for the midwife-led telephone follow-up, 21 responded to the postal survey (23.6%). Two had not received their telephone appointment. The results of the remaining 19 appear in table 3.

As the response rate was low, the answers have been grouped into 3 groups: 1. very good/good, 2. satisfactory or 3. neither good nor bad/poor/bad/very bad.

Overall, patients’ acceptance of the midwife-led telephone clinic seemed to be high with high satisfaction rates. 89.5% of the patients rated the service as very good, good or satisfactory. 84.2% of the patients answered that they are likely or extremely likely to recommend this service to friends and family.

DISCUSSION

The aim of this service evaluation was to determine whether the adherence to our standards was met, and to determine the acceptability of the service to our patients through the patients’ satisfaction survey.

The audit of adherence to agreed standards revealed few points of practice that could be improved. There was 1 symptomatic patient in whom the documentation appeared to be inadequate to explain why this patient was not referred on to the consultant clinic. 3 further patients appeared to have no documentation. The reason for this is uncertain but could include failure to document or documentation in the incorrect place. The second standard reviewed; evidence of a discussion regarding mode of delivery fell just short of the standard

Table 3: Postal Satisfaction questionnaire results (answers are from a 7 point scale except for question 5, which is from a 5 point scale)

Question	Response	Midwife telephone clinic N=19
1. How well do you think your questions and concerns were addressed?	Very good / Good	17 (89.4%)
	Satisfactory	2 (10.5%)
	Neither good nor bad Poor, Bad or Very bad	0 (0%)
2. How good was the explanation detailing the injury you had?	Very good / Good	16 (84.2%)
	Satisfactory	3 (15.8%)
	Neither good nor bad Poor, Bad or Very bad	0 (0%)
3. How well do you feel your options in a future pregnancy were discussed	Very good / Good	12 (63.2%)
	Satisfactory	3 (15.8%)
	Neither good nor bad Poor, Bad or Very bad	4 (21.0%)
4. Overall rate the service	Very good / Good	12 (63.2%)
	Satisfactory	5 (26.3%)
	Neither good nor bad Poor, Bad or Very bad	2 (10.6%)
5. How likely are you to recommend this service to Friends and Family? (5 point scale)	Extremely likely / Likely	16 (84.2%)
	Neither likely nor unlikely / Unlikely / Extremely unlikely (I don’t know)	3 (15.8%)

set. The need for documentation has been re-emphasised, including reason for non-compliance with guidelines, and these will be re-audited at a later date.

Our data from the postal survey reveals that the patients were generally happy with the midwife-led telephone consultation with 84%, likely or extremely likely to recommend this service to friends and family. The results suggest that appropriately trained midwives can provide the first follow-up consultation over the telephone following an OASI, referring on those patients with continuing symptoms for further assessment.

The published data regarding the management of OASI is mainly retrospective and is often conflicting. Therefore, counselling patients can be challenging. Understandably, much of the published literature infers a worse outcome and a greater frequency of symptoms following a 3c or 4th degree OASI compared to less severe injuries.

Review at 3 months, in one large study, suggested that the frequency of symptoms in the 3a and 3b OASI were similar to 3c and 4th⁴. However, there appears to be an increasing frequency of faecal symptoms with worsening grade of injury at six months review⁵. This may suggest that some of those with symptomatic 3a and 3b OASI become asymptomatic between 3 and 6 months. Several studies have suggested that by twelve months postnatal 60-80% of patients will be asymptomatic³.

The emphasis in the updated version of the RCOG guideline is slightly more pragmatic suggesting, 'Women who have undergone anal sphincter repair should be reviewed at a convenient time (usually 6-12 weeks postpartum). Where possible, the review should be by a clinician with a special interest in OASIS⁷'.

Experienced midwives are performing an increasing number of roles, previously performed by doctors. Although review by an experienced consultant with the appropriate expertise may be optimal, this is of little benefit to some if they struggle to get to the hospital and are therefore more inclined not to attend. Telephone consultations are used in many specialties such as dermatology, ENT, colorectal surgery^{6,8}, and indeed in urogynaecology⁹. Following urogynaecological surgical procedures, the need for routine follow-up has been called into question, suggesting patients will re-present if they have complications¹⁰. However, follow-up after OASI, is for information giving, as much as it is about information gathering and some time is required to allow the new mother to adjust to the changes in her life, so a discussion downstream from delivery is appropriate, as well as immediately post-delivery.

To the best of our knowledge, this is the first paper to introduce and evaluate a midwife-led telephone clinic for the follow-up of patients who sustained 3a and 3b OASI. As the midwife telephone consultation at 12 weeks postnatal is in part a triage service, with symptomatic patients offered a hospital appointment, the authors feel this is a promising service.

The response to the question from the telephone clinic: 'How well do you feel your options for a future pregnancy were discussed', was suboptimal with 63.2% answering very good/good, 15.8% answering satisfactory, but 21.0% answering from neither good nor bad to very bad. Although the clinic is run by experienced midwives, this may be an area, they are less comfortable with, or capable of discussing and this will be explored further at a later date (outwith this paper).

We serve a large geographical area where travelling times can be up to 2 hours to reach our unit. We, therefore feel we can considerably reduce the burden for some patients with new babies, in terms of travel time, parking, and waiting time, by providing a telephone consultation.

One limitation to our study is the poor response rate to our postal survey with only 23.6% responding. A response rate of 56% can be achieved in postal surveys of postnatal women¹¹. We did not send out reminders, which could have improved the re-

sponse rate¹² as our survey was anonymised. Other limitations include the retrospective design resulting in missing data, and the use of non-validated questions. In addition, the three midwives may counsel patients differently, but this reflects 'real life'.

The study, however, suggests that a midwife telephone clinic can be used as a triage service for symptomatic patients and as consultation for non-symptomatic patients. More robust data is required. Fundamental to this clinic set up is the option given to all patients to have a face-to-face consultant consultation.

CONCLUSION

A midwife-led telephone follow-up clinic for patients who sustained 3a and 3b perineal tears at the time of vaginal delivery, seems to be an acceptable service for these patients with high satisfaction rate. We believe that a midwife-led telephone clinic has the potential to save time and resources for both patients and healthcare providers.

REFERENCES

1. Gurol-Urganci I, Cromwell DA, Edozien LC, Mahmood TA, Adams EJ, Richmond DH, et al. Third- and fourth-degree perineal tears among primiparous women in England between 2000 and 2012: time trends and risk factors. *BJOG*. 2013;120(12):1516-25.
2. Thiagamorthy G, Johnson A, Thakar R, Sultan AH. National survey of perineal trauma and its subsequent management in the United Kingdom. *Int Urogynecol J*. 2014;25(12):1621-7.
3. Third- and Fourth-degree Perineal Tears, Management (Green-top Guideline No. 29) [Internet]. 2015. Available from: <https://www.rcog.org.uk/globalassets/documents/guidelines/gtg-29.pdf>.
4. Marsh F, Lynne R, Christine L, Alison W. Obstetric anal sphincter injury in the UK and its effect on bowel, bladder and sexual function. *Eur J Obstet Gynecol Reprod Biol*. 2011;154(2):223-7.
5. Ramalingam K, Monga AK. Outcomes and follow-up after obstetric anal sphincter injuries. *Int Urogynecol J*. 2013;24(9):1495-500.
6. Burch J. Enhanced recovery and nurse-led telephone follow-up post surgery. *Br J Nurs*. 2012;21(16):S24-6, S8-9.
7. Uppal S, Nadig S, Mielcarek MW, Smith L, Jose J, Coatesworth AP. Patient satisfaction with conventional and nurse-led telephone follow-up after nasal septal surgery. *Int J Clin Pract*. 2003;57(9):835-9.
8. Wootton R, Bahaadinbeigy K, Hailey D. Estimating travel reduction associated with the use of telemedicine by patients and healthcare professionals: proposal for quantitative synthesis in a systematic review. *BMC Health Serv Res*. 2011;11:185.
9. Jefferis H, Muriithi F, White B, Price N, Jackson S. Telephone follow-up after day case tension-free vaginal tape insertion. *Int Urogynecol J*. 2016;27(5):787-90.
10. Bateman AG, Neilens H, Gericke CA, George J, Freeman RM. Is there a need for postoperative follow-up after routine urogynaecological procedures? Patients will self-present if they have problems. *Int Urogynecol J*. 2014;25(3):381-6.
11. Sjetne IS, Iversen HH, Kjollesdal JG. A questionnaire to measure women's experiences with pregnancy, birth and postnatal care: instrument development and assessment following a national survey in Norway. *BMC Pregnancy Childbirth*. 2015;15:182.
12. Asch DA, Jedrzewski MK, Christakis NA. Response rates to mail surveys published in medical journals. *J Clin Epidemiol*. 1997;50(10):1129-36.

DISCLOSURE STATEMENTS

There was no conflict of interest, informed patient consent was obtained, and the study was approved by the local ethical committee. The authors of the publication did not receive any financial support by any grant/research sponsor

Correspondence to:

Sami Shower - Hardwick road - Stockton-on-Tees TS19 8PE
Stockton-on-Tees - United Kingdom
E-mail: sami.shower@doctors.org.uk

Pathophysiology of the functional constipation in elderly

MICHAEL D. LEVIN

State Geriatric Center, Netanya, Israel

Abstract: The aim of this study was to investigate the pathophysiology of functional constipation (FC) in the elderly. **Material and methods:** In the State Geriatric Center of Netanya (Israel), 37 patients at the age of 65-93 years with complaints of chronic constipation were examined. This main group did not include patients with tumors and cases after surgery on the rectum and colon. The results of a survey of 15 young people aged 11-17 years with no bowel disease were taken as a control group. A barium enema with a radiopaque marker near the anus was produced. A frontal radiograph of the abdomen as well as an X-ray of the lateral projection of the anorectal zone were made after the administration of 100, 200 and 300 ml of barium. **Results:** In 6 (16%) cases, the width of the rectum was more than 5 cm - megarectum. The length of the anal canal was 2 times less than the minimum normal limit after the injection of 100 ml of barium. In 25 (68%) patients, the width of the rectum was normal and had a normal shape. The functioning anal canal length was shortened during the administration of barium. In 6 (16%) patients, the reason for constipation was high colonic tone. They had the anorectal parameters within the normal range. **Conclusion:** We found 3 types of FC in the elderly. In the structure of FC the cases of self-defined constipation (68%) are dominated, where there is no mechanical obstruction for defecation. The reason for the sense of constipation and incomplete emptying is due to the age-related weakness of the pelvic floor muscles. In 16% of patients, obstructive constipation with a megarectum and a fixed descending perineum syndrome was detected. This pathology originated in childhood or after anal fissures, and childbirth. In 16% of patients, the cause of constipation was a high tone of the colon, what can be the result of an irritable bowel syndrome, the formation of functional sphincters in the colon and diverticula of the sigmoid colon. An increase in the tone of the colon causes a slow transit constipation.

Keywords: Elderly; Barium enema; Functional constipation; Outlet obstruction; Slow transit constipation; Anal canal length

INTRODUCTION

The prevalence of constipation in the general population is approximately 20% although it can range anywhere from 2% to 27%, depending on the definition used and population studied. A population-based study reported that the cumulative incidence of chronic constipation is higher in the elderly (~20%) compared to a younger population. Severe constipation is more common in elderly women, with rates of constipation two to three times higher than that of their male counterparts¹. The new criteria for ROME IV represent another attempt by brain noise to streamline scientific research in order to understand the pathophysiology of chronic constipation in patients of different age and sex, which should improve the diagnosis and treatment of this common disease. The new Rome IV criteria now supersede Rome III. In general, these minor amendments are unlikely to lead to substantial improvement in accuracy and use in routine clinical care.

Clinical criteria for functional constipation (FC) in elderly consist of < 3 bowel movements per week, straining, the presence of lumpy or hard stools, the sensation of anorectal obstruction, the sensation of incomplete defecation, and manual maneuvers¹. Almost all symptoms are subjective. This is so-called self-defined constipation. These criteria are significantly different from the criteria for obstructive constipation in children (1-18 years old), where the stool has a large diameter and emptying occurs with large volumes of feces². It is obvious that the clinical criteria of FC in the elderly do not allow to put a pathophysiological diagnosis. If the organic causes of constipation are excluded (cancer, anal fissure, etc.) and the standard treatment has no effect, these symptoms serve for the initial selection of patients for following examination (digital rectal examination, anorectal manometry, balloon expulsion test, defecography and colonic transit study)³. It is known, that the amount of obstructive constipation in the elderly does not increase, in comparison with the young, but the total number of patients with FC is almost 2 times greater. There is no unambiguous answer about the pathogenesis of this type of FC. Roque and Bouras subdivide FC on pelvic floor dysfunction and slow colonic

transit. Abnormalities in pelvic floor dysfunction include failed relaxation of the pelvic floor, paradoxical contraction of the pelvic floor muscles, or the inability to produce the necessary propulsive forces needed in the rectum to expel the stool completely¹. De Giorgio et al. describe other causes of FC: slow colonic transit, outlet obstruction: constipation by difficult or unsatisfactory expulsion of feces from rectum and constipation in IBS³. Andromanakos et al consider that primary FC can be classified into normal transit constipation, slow transit constipation, and pelvic outlet obstruction⁴. The purpose of this study is to examine the X-ray symptoms of functional constipation in the elderly and to determine their origin.

MATERIAL AND METHODS

The barium enema, as described below, was performed to 37 patients aged 65 to 93 years with complaints of chronic constipation. Twenty-two patients were female, 10 males. This group does not include patients with tumors and rectal fissure. The control group consisted of 15 adolescents (11-17 years) without disturbance of the intestinal function. They had a barium enema to diagnose the cause of anemia, chronic abdominal pain and localization of the space occupation lesion. The results of this study were accepted as a norm. In addition to the standard barium enema, we applied a barium paste to the perineum near the anus or a radio contrast marker attached to the tip, which was located near the anus. On the lateral radiographs of the anorectal zone, the distance between the barium in the rectum and the contrast mark near the anus along the posterior contour of the tip was measured. This non-contrast zone forms an anal canal closed around the tip. Thus, the length of this distance is equal to the length of the functioning anal canal. The width of the rectum was measured in the widest part above the anal canal (Fig.1, A). In patients of the control group, a barium was introduced into the colon up to the reflux into the terminal ileum. In elderly patients, a contrast agent was administered in a volume of up to 300 ml, i.e up to the splenic flexure of the colon. First, because some patients could not retain more of the barium volume, secondly, as our studies have shown, the

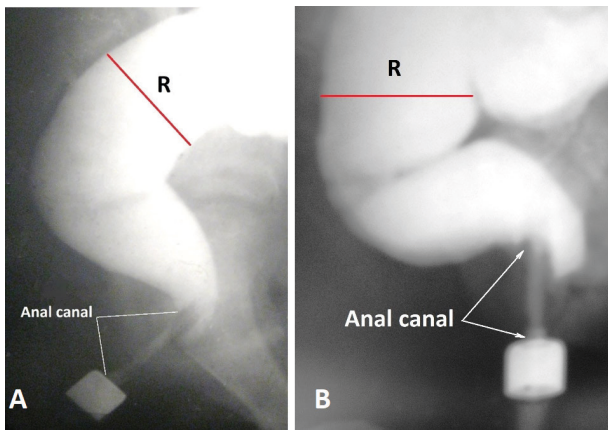


Figure 1. Lateral radiographs of the anorectal zone in patients of the control group. The rectum is bent forward resulting in a vertical and horizontal branch of the rectum can be distinguished. Between the rectum and the marker there is no contrast agent, since the anal canal contracted around the tip of the enema. B. As a result of relaxation of the internal anal sphincter, the barium penetrated into the upper part of the anal canal in front of the tip of the enema. The posterior wall of the anal canal at this level is pressed against the tip of the enema by a contracted puborectalis muscle. This is the X-ray equivalent of the anorectal inhibitory reflex

filling of the colon proximal to the splenic flexure does not change the parameters of the rectum and anal canal. The radiographs were done after the administration of 100, 200, 300 ml of barium. After that, the frontal abdominal radiograph was made. The true dimensions were calculated by multiplying the parameters measured on the roentgenogram by the projection increase factor, which under standard conditions is 0.72. Statistical analysis was performed by the method of the Student's t-test. The level of significance was set as $P < 0.05$.

RESULTS

In the control group, the length of the anal canal along the posterior contour of the tip was within 3.1-3.7 cm (3.43 ± 0.07 cm) and was unchanged throughout the study. Period-

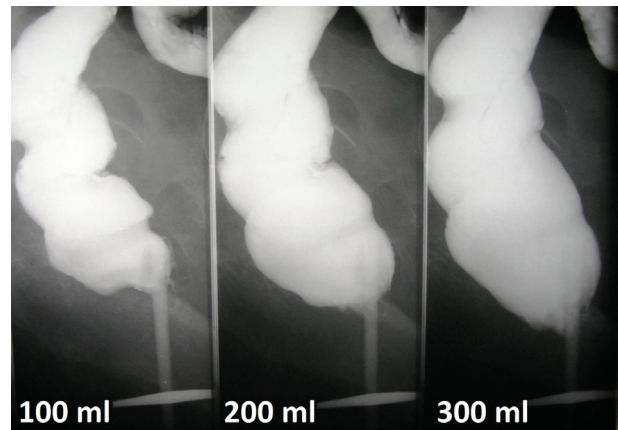


Figure 2. In a woman of 67 years during the barium enema produced three radiographs after the administration of 100, 200 and 300 ml of contrast medium. The more barium was introduced, the shorter was the functioning anal canal. After the administration of 300 ml, the anal canal was reduced by 48% compared to the length after administration of 100 ml.

ically, the barium penetrated into the upper part of the anal canal in front of the enema tip, while the posterior wall of the anal canal at this level densely pressed against this tip (Fig. 1, B). After a few (7-12) seconds the barium was squeezed into the rectum and disappeared from the anal canal.

Only in 3 (8%) patients the length of the anal canal was normal and did not change during the whole study. In the remaining observations, the anal canal was significantly shorter than in the control group (Table 1).

We noticed that in some cases the anal canal decreases during filling of the bowel with barium. The more barium is introduced, the shorter the anal canal becomes (Fig. 2). In other cases, the anal canal was twice shorter the minimum limit norm immediately after the onset of barium administration. They always had an expanded rectum. Therefore, in cases where 300 ml of barium were administered to the colon, we grouped them according to the width of the rectum (Table 2).

In patients with a rectum width of more than 5 cm, which

Table 1. Dependence of the rectal width and the anal canal length on the administration of the barium volumes.

Parameters	Control group	Elderly patients (65-94 years)			
		1st X-ray	2nd X-ray	3rd X-ray	p
The rectal width (cm)	15 3.6-4.6 3.95 ± 0.07	37 1.4-5.7 3.01 ± 0.17	37 2.5-6.7 4.23 ± 0.18	23 3.5-7.4 4.69 ± 0.22	$p^1-p^4 < 0.01$
The anal canal length (cm)	13 3.1-3.9 3.43 ± 0.10	37 2.0-5.1 3.58 ± 0.11	37 1.5-3.9 2.88 ± 0.11	22 1.5-3.7 2.39 ± 0.07	$p^1-p^2 > 0.2$ $p^1-p^3 < 0.001$ $p^1-p^4 < 0.001$
	p^1	p^2	p^3	p^4	

Table 2. Dependence of the anal canal length on the width of the rectum.

Parameters		The rectal width < 5 cm	The rectal width > 5 cm	p
The rectal width (cm)	n fluctuation limits $M \pm n$	17 3.5-5.0 4.16 ± 0.11	6 5.2-7.4 6.21 ± 0.37	$p^{1-2} < 0.001$
The anal canal length (cm)	n fluctuation limits $M \pm n$	17 1.5-3.7 2.55 ± 0.11	6 1.5-2.8 1.97 ± 0.18	$p^{1-2} < 0.02$
		p^1	p^2	

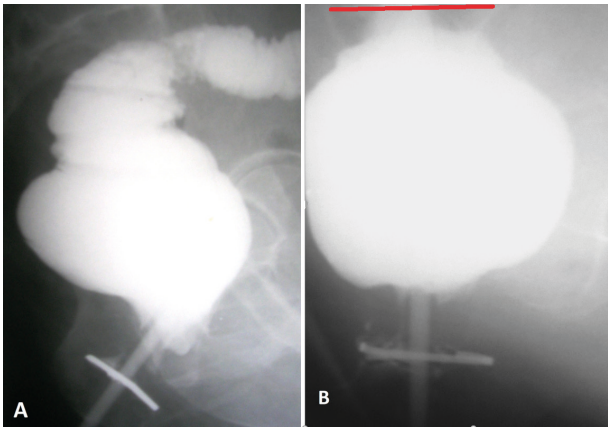


Figure 3. Lateral radiographs of the anorectal zone of two elderly patients with constipation, who have an expansion of the rectum. In both cases, there is no horizontal branch of the rectum. The anal canal is 2 times shorter than the minimum limit of normal. A. Sigmoid colon is narrow, irritated, which can be the result of prolonged use of bisacodyl. B. The width of the sigmoid colon is greatly expanded - megacolon. Sigmoid colon width - red line.

corresponds to the concept of obstructive constipation (Fig. 3), the length of the functioning anal canal was significantly less than in those where the width of the rectum was less than 5 cm, i.e. within the limits of the norm.

Meanwhile, in patients with normal rectal width (up to 5 cm), the length of the anal canal also was significantly less than in the control group ($p < 0.001$). The shortening of the anal canal immediately after the introduction of the first portion of the barium corresponds to the notion of a fixed descending perineum syndrome.

In 6 patients without rectal expansion on the frontal abdominal radiographs, signs of high colonic tone were found, which was the probable cause of slow transit constipation. Among them were 3 women with severe irritable bowel syndrome (Figure 4, A), two patients with several functional sphincters in the colon (Figure 4, B) and one man with diverticula of the sigmoid colon (Fig- 4, C).

DISCUSSION

The gap between the barium into the rectum and the marker near the anus is due to the contraction of the anal canal. In patients of the control group, its length is equal to the length of the anal canal measured by the manometric, ultrasound and MRI methods⁵.

In healthy individuals during the barium enema, the length of the anal canal, along the posterior contour of the enema

tip remains unchanged. Periodically penetration of barium from the rectum into the upper part of the anal canal in front of the enema tip observed, which is accompanied by a decrease in anal pressure. This picture is due to the relaxation of the internal anal sphincter (IAS). At this time, the posterior wall of the anal canal is pressed against the tip of the enema by the contracted puborectalis muscle (PRM), which together with the external anal sphincter (EAS) prevents the leakage of barium. After 7-13 seconds, barium is squeezed back into the rectum, which is accompanied by the restoration of pressure to the basal level. This reaction of the anal canal to an increase in the rectal pressure is the radiographic equivalent of the inhibitory anorectal reflex⁵. In healthy people, the rectum on the lateral roentgenogram unfolds forward and is actually subdivided into vertical and horizontal branches.

Based on the analysis of clinical and radiological data, we found among 37 patients with FC the three homogeneous groups of patients. The first group consisted of 6 (16%) patients with a rectal width more than 5 cm. The second group comprised 25 (68%) patients with normal rectum width, but with a short anal canal. The third group included 6 (16%) patients with increased colonic tone. The width of the rectum and the length of the anal canal were within normal limits in 3 of them but in 3 cases the anal canal was shorter than normal.

In patients with megarectum (1st group), the anal canal was almost 2 times shorter than the minimum limit of norm and was always shorter than in patients in the 2nd group. The shortening was detected immediately after the introduction of a small volume of barium. As shown by us earlier, the shortening of the functional part of the anal canal is due to the weakness of the pelvic floor muscles. Weak PRM cannot close up the upper part of the anal canal, and during a bowel movement a weak LAM cannot wide open the anal canal. Thus, the upper part of the anal canal is expanded and looks as a part of the rectum⁶.

This picture corresponds to concept of a fixed form of the descending perineal syndrome⁷. In the first group there was always no horizontal branch of the rectum. Based on these six observations, we came to the conclusions that the reason of constipation in them is an outlet obstruction that arose either in childhood or in the late period as a result of anal stenosis or fissures. Stool retention in the rectum led to the development of a megarectum. Wide feces under the influence of a strong peristaltic wave stretched the upper part of the anal canal, in which the stool masses begin to accumulate.

In 25 patients of the second group the width of the rectum was within normal limits. They did not suffer from abdominal pain and in the frontal radiograph the large intestine had normal size and shape. They had two branches of the rec-

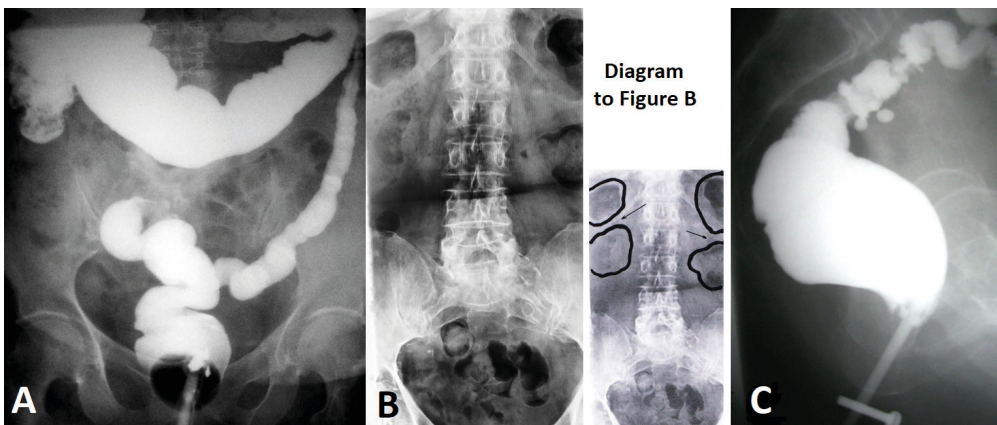


Figure 4. Radiographs of patients with increased tone of different segments of the colon. A. In a patient with irritable bowel syndrome, the left half of the colon is sharply narrowed, without haustration. B. The arrows show functional sphincters in the form of colon contraction, between adjacent chambers containing gas and feces. The rectum is empty. C. High tone of the sigmoid colon with diverticula. The size of the rectum and anal canal is within normal limits.

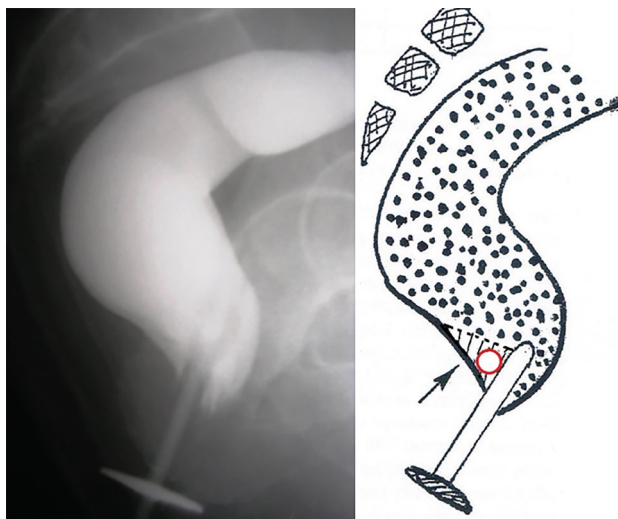


Figure 5. Lateral radiograph of the anorectal zone of an elderly man with complaints of constipation and incomplete emptying. The dynamic descending perineum syndrome with penetration of barium into the upper part of the anal canal behind the tip of the enema is determined (arrow in the diagram). The red ring indicates a fecal bolus that has penetrated the anal canal.

tum: vertical and horizontal. The anal canal was shortened during the introduction of the contrast medium, which corresponds to the dynamic form of the descending perineum syndrome⁷.

Consequently, in these patients, the pelvic floor muscle weakness was less pronounced than in patients of first group with outlet obstruction. It is caused by age-related changes in the muscles of the pelvic floor. The normal width of the rectum indicates that the anal canal did not interfere with the promoting of the stool. We assumed that in these cases there is a so-called self-determined form of constipation, which is characterized by patients' complaints about the difficulty of defecation and a feeling of incomplete emptying. The mechanism of occurrence of these sensations can be explained by the penetration of small fecal boluses into the upper part of the anal canal due to the weakness of the PRM. Irritation of sensory elements in this part of the anal canal by fecal bolus causes a need for defecation, but a small amount of bolus is unable to create a threshold volume of defecation. Because of this, patients are forced to use a finger maneuver, i.e. removal of feces with a finger through the vagina or anus. The rest of small fecal lumps in this part of the anal canal provokes a feeling of incompletely emptying (Fig.5).

In 6 patients of the third group, FC was combined with abdominal pain. The width of the rectum and the length of the anal canal were within normal limits in 3 of the patients, and in the remaining 3 patients with irritable bowel syndrome the rectum was narrow. On the frontal radiographs the signs of an increased tone of the colon of different nature were found, which inevitably caused the slow transit through the colon.

One of the reasons for the high tone of the colon is irritable bowel syndrome (IBS). Some researchers exclude IBS from the analysis of FC⁸. We consider necessary to include it in a differential series for two reasons. First, because there are no clear clinical criteria for diagnosis of IBS. Secondly, as we showed earlier, obstructive constipation, as a form of chronic obstruction, can cause the development of nonspecific inflammation of the colon and an increase its tone. In such cases, chronic constipation may be accompanied by pain in the abdomen (see Fig. 3.A) and

differential diagnosis of FC and IBS is not possible. The main pathognomonic symptoms of IBS are the increased sensitivity of the colon to intestinal irritation (pressure)⁹. It is necessary to distinguish delayed transit through the colon, as a result, of an increase in the tone of its different segments, which is the cause of FC, from delayed transit, which in obstructive constipation is observed as a symptom. Prolonged accumulation of large feces in the rectum and left colon invariably causes a slowing of the movement of feces.

In the process of ontogenesis, functional sphincters appear in the colon. A total of 11 functional sphincters are described. The most extensively studied are colosigmoid sphincter "(CSS) and rectosigmoid sphincter (RSS). Between the descending and sigmoid colon there is a physiological CSS by a length of 2.1 ± 0.9 cm. In this zone, the pressure was significantly higher than in the adjacent segments. After a quick inflation of the balloon of large diameter in the descending colon, the decrease of pressure in the CSS was noted. After inflating the same balloon in the sigmoid colon, the pressure in the CSS increases. On the other hand, inflation with a small balloon did not affects the tone of this sphincter. It is clear that the CSS is involved in a passage of large intestinal contents. CSS retains the feces until it reaches a certain volume¹⁰. Between the rectum and sigmoid is located the intestinal segment of 2.8 ± 0.9 cm length with the layer of circular muscle thickened in comparison to the segments above and below it¹¹. While the pressure in the sigmoid colon increases, this functional RSS relaxes. In response to increased pressure in the rectum, its tonus rises¹². Different reactions of RSS to different volume of the balloon were found. After a quick inflation of the balloon in the sigmoid with 52.1 ± 3.6 ml of liquid, the tone of the RSS increased but the rectal pressure did not change. After the rapid inflation into the balloon of 86 ± 4.1 ml, the RSS relaxed and the balloon was expelled to the rectum. It was accompanied by an increase of the rectal pressure, and the balloon was expelled¹³⁻¹⁴. On the roentgenogram of the spine (Fig.4.B), at least 4 oval chambers containing gas and feces are seen that are separated from each other by contracted functional sphincters. They are opened and passed feces only when a large volume of feces gathers in the chambers above the sphincters. This dramatically slows the passage of feces across the colon, which corresponds to the concept of slow transit constipation.

High pressure in the sigmoid colon can be so strong that diverticula are formed. It is always accompanied by chronic constipation and abdominal pain. However, as can be seen in Fig. 4.C, the rectum and anal canal are of normal size and shape and do not cause chronic constipation. This is also one of the forms of slow transit constipation in the elderly.

CONCLUSION

We found 3 types of FC in the elderly. In the structure of FC are dominated by cases of self-defined constipation (68%), where there is no mechanical obstruction for defecation. The reason for the sense of constipation and incomplete emptying is due to the age-related weakness of the pelvic floor muscles. In 16% of patients, obstructive constipation with a megarectum and a fixed descending perineum syndrome was detected. This pathology originated in childhood or after anal fissures, and childbirth. In 16% of patients, the cause of constipation was a high tone of the colon, what can be the result of an irritable bowel syndrome, the formation of functional sphincters in the colon and diverticula of the sigmoid colon. An increase in the tone of the colon causes a slow transit constipation.

REFERENCES

1. Maria Vazquez Roque and Ernest P Bouras. Epidemiology and management of chronic constipation in elderly patients. *Clin Interv Aging*. 2015; 10: 919–930. Published online 2015 Jun 2. doi: 10.2147/CIA.S54304
2. Elvira Ingrid Levy, Roel Lemmens, Yvan Vandenplas, and Thierry Devreker. Functional constipation in children: challenges and solutions. *Pediatric Health Med Ther*. 2017; 8: 19–27. Published online 2017 Mar 9. doi: 10.2147/PHMT.S110940
3. De Giorgio R, Ruggeri E, Stanghellini V et al. Chronic constipation in the elderly: a primer for the gastroenterologist. *BMC Gastroenterol*. 2015 Oct 14;15:130. doi: 10.1186/s12876-015-0366-3.
4. Andromanakis NP, Pinis SI, Kostakis AI. Chronic severe constipation: current pathophysiological aspects, new diagnostic approaches, and therapeutic options. *Eur J Gastroenterol Hepatol*. 2015; 27(3):204–14. doi: 10.1097/MEG.000000000000288.
5. Levin MD. The role of the external anal sphincter in the physiology of the pelvic floor. *Pelvipерineology*. 2017; 36(4):108–112.
6. Levin MD. Pathophysiology and diagnosis of descending perineum syndrome in children. *Pelvipерineology*. 2018;37(2):52–54.
7. Baek HN, Hwang YH, Jung YH. Clinical Significance of Perineal Descent in Pelvic Outlet Obstruction Diagnosed by using Defecography. *J Korean Soc Coloproctol*. 2010;26(6):395–401. doi: 10.3393/jksc.2010.26.6.395. Epub 2010 Dec 31.
8. Bouras EP, Tangalos EG. Chronic constipation in the elderly. *Gastroenterol Clin North Am*. 2009;38(3):463–80. doi: 10.1016/j.gtc.2009.06.001.
9. Ritchie J. Pain from distension of the pelvic colon by inflating a balloon in the irritable colon syndrome. *Gut*. 1973;14(2):125–32.
10. Shafik A. Effect of rectal distension on the small intestine with evidence of a recto-enteric reflex. *Hepatogastroenterology*. 2000; 47(34):1030–3.
11. Shafik A, Shafik AA, el-Sibai O, Ahmed I. Colosigmoid junction: a study of its functional activity with identification of a physiologic sphincter and involvement in reflex actions. *J Invest Surg*. 2003;16(1):29–34.
12. Shafik A, Assad S, Doss S. Identification of a sphincter at the sigmoidorectal canal in humans: histomorphologic and morphometric studies. *Clin Anat*. 2003 Mar;16(2):138–43.
13. Shafik A. The hypertonic rectosigmoid junction: description of a new clinicopathologic entity causing constipation. *Surg Laparosc Endosc*. 1997;7(2):116–20.
14. Shafik A, Shafik AA, El Sibai O, Ahmed I, Mostafa RM. Role of the rectosigmoidal junction in fecal continence: concept of the primary continent mechanism. *Arch Surg*. 2006;141(1):23–6.

NOTES

For the first time functional constipation in the elderly is assessed from the point of view of the anorectal zone function using mathematical analysis.

DISCLOSURES

There was no conflict of interest, informed patient consent was obtained, the study was approved by the local ethical committee and the author of the publication did not receive any financial support by any grant/research sponsor.

Correspondence to:

Michael Levin MD, Dsc. Radiologist
Amnon veTavar 1/2 - Netanya 42202 - Israel
Tel.: 972-538281393
E- mail: nivel70@hotmail.com
F- michael.levin@dorot.health.gov.il
<https://orcid.org/0000-0001-7830-1944>
<https://www.anorectalmalformations.com>

Multidisciplinary UroGyneProcto Editorial Comment

To improve the integration among the three segments of the pelvic floor, some of the articles published in *Pelvipерineology* are commented on by **Urologists, Gynecologists, Proctologists/Colo Rectal Surgeons or other Specialists**, with their critical opinion and a teaching purpose. Differences, similarities and possible relationships between the data presented and what is known in the three fields of competence are stressed, or the absence of any analogy is indicated. The discussion is not a peer review, it concerns concepts, ideas, theories, not the methodology of the presentation.

Uro... It is well known that human defecation is a complex physiologic mechanism that involves integrated and coordinated sensorimotor functions orchestrated by central, spinal and peripheral neural activities. In this way when the rectum is filled with feces the pressure within it is increased allowing the passage of the fecal material through the anal canal which has further increased by muscles of pelvic floor helping to pull the anal canal walls apart and causing a further filling of the anal canal by feces that can be expelled due to relaxation of internal and external sphincters.

This coordinated neuromuscular activity is analogous also for what concerns filling and bladder emptying phase, since the innervation of the bladder and of sphincteric mechanism is similar to the rectum and of the anal canal one.

A close functional relationship between urinary retention and constipation in the elderly is therefore evident. In fact in this age group it is very probable the presence of a detrusor underactivity like an equally disabling condition to produce the necessary propulsive forces needed in the rectum to expel the stool completely. Most likely the cause, from an uro-

logical point of view, is due to a transformation of the detrusor muscle tissue into collagen tissue due to a prolonged obstruction over time of the bladder neck caused by prostatic hypertrophy or a large vaginal prolapse¹. Much more rarely, instead, the urinary retention in the elderly is due to a failed relaxation of the pelvic floor as this pathological condition is typical of young subjects affected by chronic pelvic pain.

REFERENCE

1. Bellucci CHS, Ribeiro WO, Emerly TS et al. Increased detrusor collagen is associated with detrusor overactivity and decrease bladder and compliance in men with benign prostatic obstruction. *Prostate Int* 2017; 5: 70–74

Correspondence to:

SALVATORE SIRACUSANO
Professor of Urology
University of Verona, Italy
Email: salvatore.siracusano@univr.it

On collagen, ageing and surgical treatment options following commercial kit withdrawals- a critical analysis

¹BURGHARD ABENDSTEIN, ²DMITRY SHKARUPA, ³PETER PETROS

¹FA für Gynäkologie, Geburtshilfe und Chirurgie, Akademisches Lehrkrankenhaus Feldkirch, Feldkirch, Austria

²Saint-Petersburg State University, shkarupa.dmitry@mail.ru

³Faculty of Engineering and Mathematical Sciences, The University of Western Australia

Abstract: The banning of all mesh for prolapse by the FDA has failed to recognize that there is a major difference between mesh sheets applied behind the vagina for POP and repair of POP by shortening and reinforcing damaged suspensory ligaments, much as is used in the midurethral sling (MUS) which retains endorsement by the FDA. Mesh sheets interfere with the vaginal elasticity essential for function and may cause pain and massive urine loss post-operatively, in some cases; tapes far less so, as they have little contact with vagina and work by shortening and reinforcing damaged ligaments in the same way as the MUS operation. The main pathogenesis of POP is leaching out of collagen after the menopause. Weakened ligaments cannot support the organs so they prolapse. Only artificial collagenous neoligaments created by implanted tapes (as per the MUS) can create the new collagen required to repair these ligaments.

The major advances developed over the past 30 years for treatment of POP using these ligament repair techniques has in one stroke been abolished. The treatment of POP has been set back 100 years. In their twilight years, many women will suffer the consequences of loose posterior ligaments, major prolapse, urge, nocturia, chronic pelvic pain, obstructed micturition defecation and fecal incontinence. The FDA needs to reconsider its ban, at least for tapes, which are supported by individual, multicentre and long-term studies.

Keywords FDA; Mesh sheets; Mesh tapes; Neoligaments; Collagen; Menopause

COMMENTARY

The stimulus for this commentary was two news items, withdrawal of Bard's mini sling followed later by the announcement by the FDA of recall of all mesh kits, for pelvic organ prolapse (POP).

<https://news.sky.com/story/major-surgical-mesh-manufacturer-bard-to-pull-vaginal-implant-products-11657919>

<https://www.fda.gov/NewsEvents/Newsroom/PressAnnouncements/ucm636114.htm>

Both are grim reminders of Dr Nager's insightful 2016 predictions¹. The end point of his well-reasoned analysis was that despite overwhelming scientific evidence and recommendations from learned societies, even the midurethral sling (MUS), the most validated operation in history, was in danger of disappearing.

Our aim in this brief commentary is to elaborate on three main points from Nager's article and add a 4th, the rationale behind the MUS, collagen loss in the PUL suspensory ligament in an ageing female population.

1. Midurethral slings 'MUS', tape surgery, is very different from mesh sheets used for repair of pelvic organ prolapse.
2. MUS is minimal surgery. Complications are far less than those of major surgery; no surgery for MUS is disastrous as regards QOL.
3. Disappearance of midurethral slings from the market is a dire situation for women.

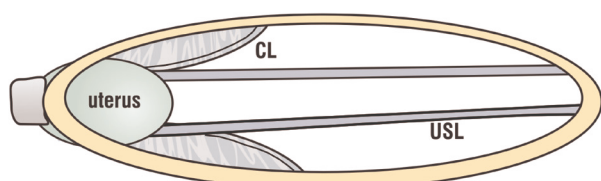


Fig 1. Uterine prolapse caused by weakened level 1 supports. If collagen leaches out of the cardinal (CL) and uterosacral (USL) ligaments, they will elongate. Shortening and reinforcing of ligaments is required. Critical for any long-lasting repair is the quality of ligament collagen.

Collagen 1 (breaking strain 18,000 lbs/sq inch) is the key structural component of the body. At menopause, there is a twofold increase in excretion of urinary collagen I breakdown products, which persists for the entire postmenopausal period². Collagen loss causes joint, osteoporosis and organ prolapse problems, the latter generally attributed to loss of level 1 supports, fig 1. Collagen I is the major structural component of ligaments, (breaking strain 300mg/mm²); collagen III, weaker, more elastic, allows vagina (breaking strain 60mg/mm²) to stretch extensively (VIDEO Xray <https://youtu.be/eiF4G1mk6EA>). We can deduce from collagen breakdown data², that if collagen deficiency in a structural ligament is the cause of a pelvic floor problem, whether it be prolapse or symptoms, no "native tissue repair" will fix it. New collagen needs to be created.

The original hypothesis which led to the MUS was that SUI (stress urinary incontinence) was mainly caused by collagen-deficient pubourethral ligaments. A new surgical principle, using an implanted tape to create artificial collagenous pubourethral ligaments, became the basis of the MUS, now implanted in >5,000,000 women¹.

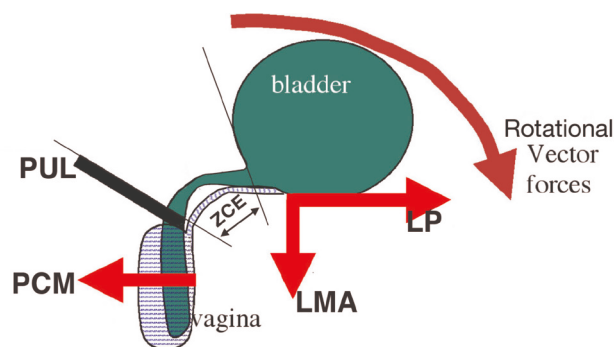


Fig 2. Normal urethral closure in the female during coughing or straining
PCM = m.pubococcygeus. LP= levator plate; LMA= conjoint longitudinal muscle of the anus; PUL=pubourethral ligament. ZCE (zone of critical elasticity), allows separate action of forward and backward vectors.

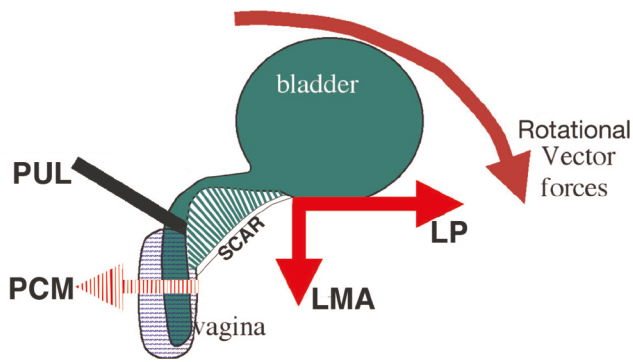


Fig 3. Xray Normal patient, sitting position, straining. Oppositely acting vector forces during straining (arrows) indicates the imperative of an elastic zone at ZCE so as to allow the vector closure forces to operate independently. Labelling as in 1A. CX=cervix; R=rectum; B=bladder; USL=uterosacral ligaments; S=sacrum.

Added to Nager's statement¹ that midurethral slings (MUS) are very different from mesh sheets as they implant much less mesh is the effect of mesh on vaginal elasticity. The VIDEO XRAY <https://youtu.be/eiF4G1mk6EA> shows that vagina requires very significant elasticity to implement its functional roles during straining, micturition, squeezing upwards; in contrast, the vaginal anchoring points, pubourethral ligament and uterosacral ligaments remain immobile. Placing a mesh sheet behind vagina, or removing a segment of vagina ("native tissue repair") will only fibrose vagina. One complication from fibrosis is sudden massive incontinence immediately after mesh sheet implant. Its cause, "Tethered Vagina Syndrome" (TVS), explains ongoing massive urine loss following Obstetric Fistula closure in 50% of patients³.

Pathogenesis

Excess scarring, whether from fistula or mesh fibrosis may "tether" (connect) the more powerful posterior muscle closure forces to the weaker anterior forces, so the urethra is forcibly pulled open on the signal to close, resulting in massive uncontrolled urine loss³, figs2&3. A skin graft to the anterior vagina restores elasticity and function³, fig4. Tapes rarely cause this problem as they attach directly to the skeleton with minimal contact with vagina.

Is there a difference between tapes and mesh sheets?

Mesh sheets work by blocking organ descent; post-op. 2D ultrasound reveals continued presence of the prolapse. The MUS tape principle, fig1, works by shortening and reinforced the elongated USLs, with a posterior sling, literally a "reverse TVT." A sling in front of cervix reduces post-surgical cystocele. A tensioned mini sling repairs all 5 suspensory ligaments, with 79% anatomical cure rate for major prolapse at 5 years, using 3rd generation lightweight tapes with no vaginal excision and low erosion/"surfacing" rates.

"Native tissue" repair

There is no greater condemnation of 'native' vaginal repair than the 2016 Lancet PROSPECT study. Failure rate at 6 months was >85%. CL/USL plication may be a better "native tissue" option. Evidence for this is from an RCT, CL/USL plication against Tropicium which was stopped by the St Petersburg University EC because of rapidly deteriorating cure rates in the post-menopausal

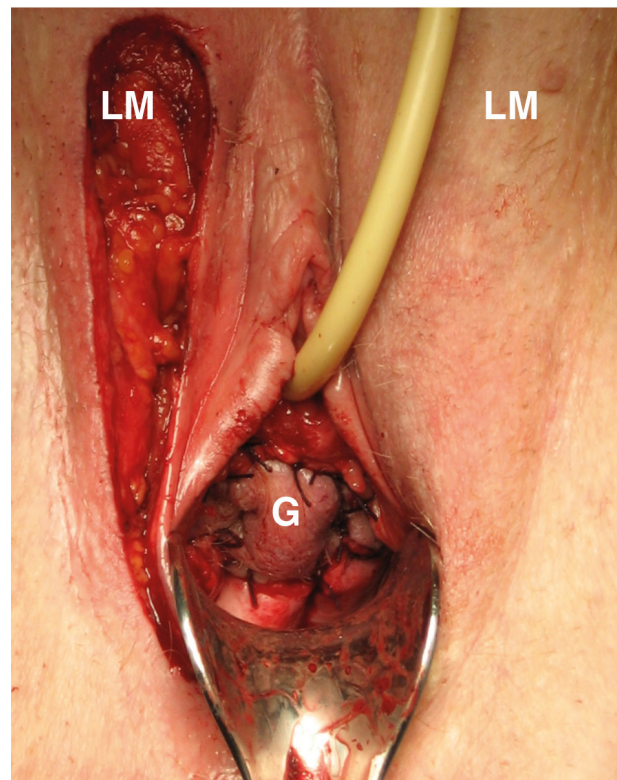


Fig 4. Augmentation of ZCE with a skin-on Martius Graft restores independent movement of the vector forces. LM=labium majus ; G=graft sutured to bladder neck area of vagina to cover the tissue deficit.

arm, 17% cure (n=48) at 18 months post-op, as against 80% cure for pre-menopausal women (n=40), (Shkapura, as yet unpublished data). The high failure rate was attributed to collagen leaching out postmenopausally from the ligaments, consistent raised collagen1 breakdown products².

CONCLUSIONS

It is unfortunate that whatever the expert opinion guiding the FDA's actions, it was ignorant of the fact that posterior slings for POP work in exactly the same way as the midurethral sling which it has endorsed. Posterior slings do not have the same severe pain or tethered vagina syndrome complications as mesh sheet kits. This FDA decision will have severe unintended consequences. After the menopause, women lose the collagen which supports their ligaments². Weak ligaments cannot be repaired by any type of "native tissue repair". They can only be repaired by the artificial neoligament technique developed on experimental animals in the years 1987-8 at Royal Perth Hospital⁴, the very method endorsed by the FDA for cure of SUI. The major advances developed over the past 30 years for treatment of POP using these ligament repair techniques has in one stroke been abolished. The treatment of POP has been set back 100 years. In their twilight years, many women will suffer the consequences of loose posterior ligaments, major prolapse, urge ,nocturia,chronic pelvic pain, obstructed micturition defecation and fecal incontinence. The FDA needs to reconsider its ban, at least for tapes, which are supported by individual, multicentre and long-term studies⁵⁻¹⁹.

REFERENCE

1. Nager CW Midurethral slings: evidence-based evidence vs the medicolegal system; *Am J Obstet Gynecol.* 2016 06; 214(6):708.e1-5 <https://doi.org/10.1016/j.ajog.2016.04.018>
2. Miyake m, Takeda N, Fukunaga M, Urinary excretion of type I collagen crosslinked N-telopeptides in Healthy Japanese adults: Age- and sex-related changes and reference limits *Bone Volume 17, Issue 4, October 1995, Pages 335-339*
3. Browning A, Williams G, Petros P, Skin flap vaginal augmentation helps prevent and cure post obstetric fistula repair urine leakage: a critical anatomical analysis *BJOG.* 2018 May;125(6):745-749. doi: 10.1111/1471-0528.14953. Epub 2017 Nov 17.
4. Petros PE & Ulmsten U, Papadimitriou J, The Autogenic Neoligament procedure: A technique for planned formation of an artificial neo-ligament. *Acta Obstetrica et Gynecologica Scandinavica, Supplement 153, Vol 69, (1990), 43-51.*
5. Liedl B, Inoue H, Sekiguchi Y, et al. Is overactive bladder in the female surgically curable by ligament repair? *Cent European J Urol.* 2017; 70: 51-57.
6. Neuman M, Lavy Y. Posterior intra-vaginal slingplasty for the treatment of vaginal apex prolapse: Medium-term results of 140 operations with a novel procedure. *Eur J Obstet Gynecol Reprod Biol.* 2008;140:230–233.
7. Goeschen K, Posterior Fornix Syndrome: Comparison of original (2004) and modified (2015) post-PIVS anatomic and symptomatic results: a personal journey. *Pelvipereineology* 2015; 34: 85-91
8. Caliskan A, Goeschen K, Zumrutbas A. E. Long term results of modified posterior intravaginal slingplasty (P-IVS) in patients with pelvic organ prolapse. *Pelvipereineology* 2015; 34: 94-100
9. Richardson P Surgical cure of nocturia using 4 different methods based on strengthening the structural supports of the vaginal apex - a short review. *Pelvipereineology* 2015; 34: 92-93
10. Petros PE New ambulatory surgical methods using an anatomical classification of urinary dysfunction improve stress, urge, and abnormal emptying. *Int J Urogynecology* (1997) vol 8, 5: 270-278.
11. Inoue H, Kohata Y, Sekiguchi Y, Kusaka T, Fukuda T, Monnma M. The TFS minislign restores major pelvic organ prolapse and symptoms in aged Japanese women by repairing damaged suspensory ligaments— 12-48 month data. *Pelvipereineology* 2015;34:79–83.
12. Haverfield M. Tissue fixation system (TFS) neoligament pelvic organ repair procedures— 12 and 24 month results. *Pelvipereineology* 2015;34:70–4.
13. Petros PE & Ulmsten U. An Integral Theory of female urinary incontinence. *Acta Obstetrica et Gynecologica Scandinavica, Supplement 153, Vol 69, (1990), 1-79*
14. Petros PE & Ulmsten U. Bladder instability in women: A premature activation of the micturition reflex. *Neurourology and Urodynamics* 12, 235-239 (1993).
15. Petros PE Detrusor instability and low compliance may represent different levels of disturbance in peripheral feedback control of the micturition reflex. *Neurourol and Urod* (1999) 18:81-91.
16. Goeschen K, Gold DM *Pelvipereineology* 2017; 36: 84-88 Surgical cure of chronic pelvic pain, associated bladder & bowel symptoms by posterior sling in 198 patients validates the Pescatori Iceberg principle of pelvic symptom co-occurrence
17. Petros P. Letter to the Editor. Similar mechanics explain cure of urinary and fecal incontinence by repair of the uterosacral ligaments with a posterior sling *Cent European J Urol.* 2017 doi: 10.5173/ceju.2017.1592 [Ahead of print]
18. Petros PE, Bush MB The same posterior muscle vectors act to open urethra and anus during micturition and defecation. *Pelvipereineology* 2017; 36: 35-36 h
19. Liedl B, Bush M Competent uterosacral ligaments are required for normal bladder evacuation-testing a hypothesis evolving from finite element studies on micturition mechanisms in the female. *Pelvipereineology* 2016; 35: 105-108

NOTES

VIDEO <https://youtu.be/eiF4G1mk6EA> Note the enormous elasticity of the vagina which is required to squeeze (lift up) the organs and also during micturition.

Letter to the editor

Dear Editors,
I write to comment on the Levin hypothesis

1. Levin M The role of detrusor rigidity in the lower urinary tract dysfunction. Hypothesis Pelviperineology 2018; 37: 70-73

As a pelvic floor surgeon with a major interest in bladder and anorectal function, I found Dr Levin's hypothesis¹ most interesting. His hypothesis starts from the known, symptoms of bladder emptying and urgency increase with age. He provides evidence of fibrosis within the detrusor smooth muscles then proceeds seamlessly to elaborate his hypothesis. The hypothesis is an admirable example of deductive logic. However, it fails on one major point, it cannot ex-

plain reported surgical cures of overactive 'OAB'² and underactive bladder 'UAB'^{3,4}. Furthermore it fails to mention the external mechanisms which open and close the urethra, figs 1&2. The reason why UAB has a slow flow (at least in females) can be attributed to the effect of this external mechanism on the urethral tube which, by narrowing or expanding the urethra, exponentially affects urine flow⁴ figs 3&4, in an inverse relationship with the 4th power of the radius, Poiseuille's Law⁵.

The bladder is a receptacle with only one role, to empty. Electrical transmission is smooth muscle to smooth muscle⁶ and the bladder empties by spasm. This is evident on viewing any video of micturition.

Control of evacuation is by muscle forces acting at the urethral outlet tube, in turn controlled by closure or micturition reflexes⁷. The diameter of the urethra is varied by external muscle forces: it is narrowed for closure, or expanded just prior to evacuation, figs 1, 2, 4. These muscle forces are external to the urethra. They rapidly alter the urethral diameter and therefore, the resistance to flow, exponentially⁵. Almost all bladder dysfunctions can be explained by the effect of the closure or micturition reflexes

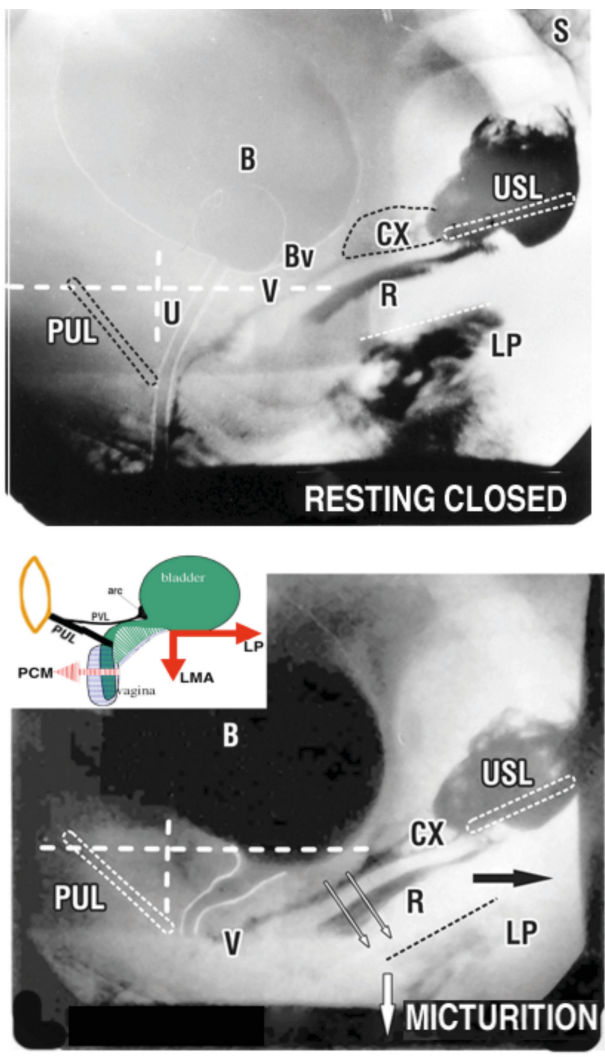


Fig 1 Anatomical changes in bladder when the micturition reflex is dominant
Upper XR - Resting closed Directional slow twitch muscle fibres maintain urethral closure distally and at bladder neck. Bv=ligamentous attachment of bladder base to anterior vaginal wall (V). R=rectum; LP=levator plate; CX=cervix; USL=uterosacral ligament; PUL=pubourethral ligament' U=urethra
Lower XR - Micturition The forward PCM vector (insert) relaxes. The backward LP/LMA vectors stretch the vagina backwards and downwards against USL to open out the posterior urethral wall. The pubovesical ligament attachment to the arc of Gilvernet (PVL, insert figure) prevents the anterior bladder wall prolapsing into the outflow tract. Note downward angulation of LP.

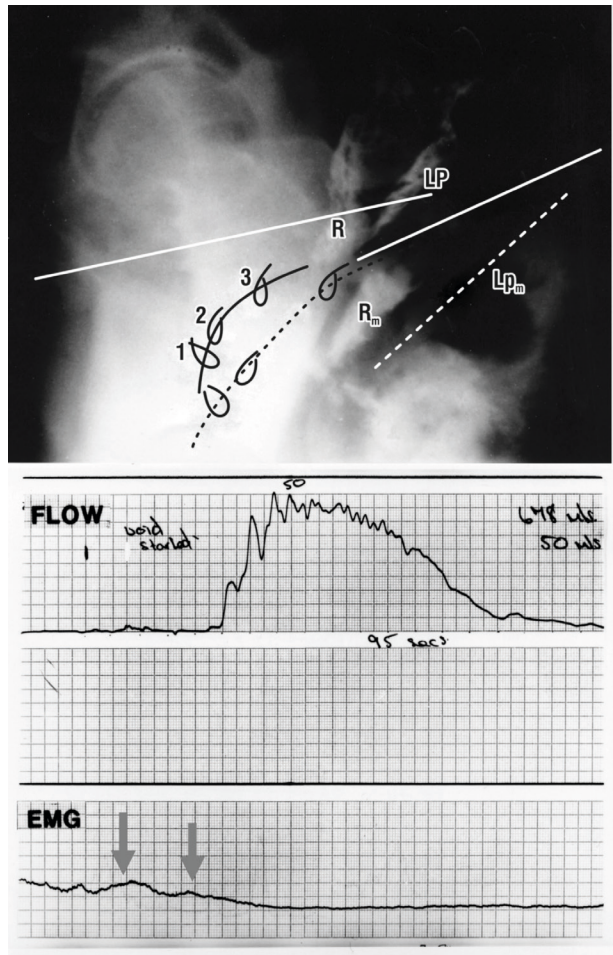


Fig. 2 Normal micturition in the female
Upper image Micturition xray (broken lines) superimposed on resting xray. Subscript "m" denotes position of organ during micturition. R=rectum; LP=levator plate. Clips have been applied to the midurethra '1', bladder neck '2' and bladder base '3'. Note downward/backward displacement of the clips indicating stretching open of the posterior urethral wall.
Lower image EMG activity (arrows) commences prior to the start of urine flow.

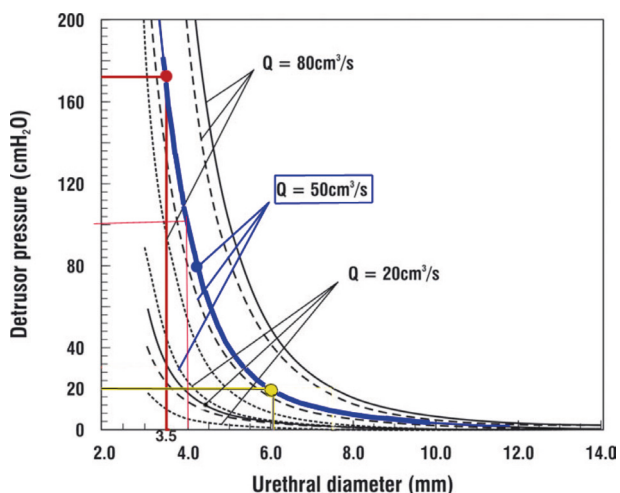


Fig 3 Exponential nature of urine flow is related to urethral diameter For a flow rate of 50ml/sec (thick blue line), opening the urethral diameter from 3.5mm to 4 mm reduces the head of pressure required by detrusor to expel the urine from 172 cm H2O to 100 cm H2O). Expanding to 6mm (yellow lines), reduces the head of pressure to 20cm H2O. The blue line is the total urethral resistance to flow. The broken lines are dynamic and frictional flow components.

on the urethral tube and its effect on urine flow⁷. The posterior opening forces (arrows, fig1), contract against the uterosacral ligaments (USL). If USLs are loose, the posterior muscle forces (arrows) weaken; the vagina cannot be stretched to support the bladder base stretch receptors. These may fire off prematurely to activate the micturition reflex to cause urge and urine loss. Nor does it take much urethral narrowing to cause emptying difficulties. The margin is very small. For example, inability of the posterior vectors to open the urethra because of lax USLs from 3.5 to 4mm (a very small amount), fig 3, almost doubles the head of pressure required by bladder to expel the urine, from 100cm H2O to 172 cm H2O. Repair of USLs has been shown to cure both OAB¹ and both OAB and UAB²⁻³. I agree with Dr Levin about age-related causation of OAB and UAB. However, the cause from the perspective of the Integral Theory⁷ is collagen loss in the uterosacral ligaments, which is repaired by the new collagen generated by the posterior sling tapes²⁻⁴.

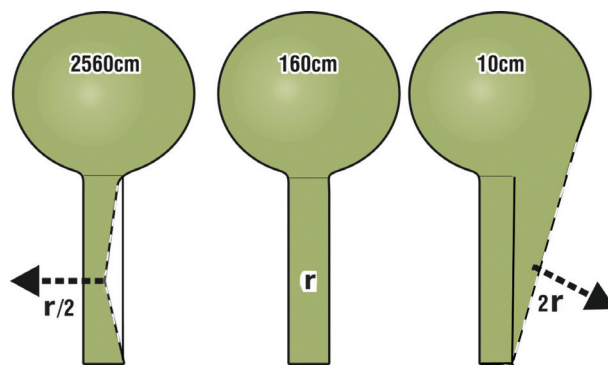


Fig 4 How external muscle forces alter urethral tube diameter to facilitate closure or evacuation

The arrows indicate how muscle forces can externally alter urethral diameter. The 160cm pressure needed to empty through resting urethral radius 'r' is a nominal figure. Pressure needed to empty following active closure to (r/2) or opening to (2r) is calculated by applying Poiseuille's Law, whereby internal resistance to flow varies inversely by the 4th power of the radius. For example, if the urethral tube can be stretched open to twice the radius (2r) during micturition, the pressure needed to evacuate the bladder falls by a factor of 16 (2x2x2x2), from 160cm to 10cm H2O. Broken lines indicate change in diameter by muscle forces (arrows).

REFERENCES

1. Levin M The role of detrusor rigidity in the lower urinary tract dysfunction. Hypothesis Pelviperineology 2018; 37: 70-73
2. Bernhard Lied^a, Hiromi Inoue^b, Yuki Sekiguchi^c, Darren Gold^d, Florian Wagenlehner^e, Max Haverfield^f, Peter Petros^d Update of the Integral Theory and System for Management of Pelvic Floor Dysfunction in Females European J of Urology EURLUP-738 <http://dx.doi.org/10.1016/j.eursup.2017.01.001>
3. Goeschen K Posterior Fornix Syndrome: Comparison of original (2004) and modified (2015) post-PIVS anatomic and symptomatic results: a personal journey Pelviperineology 2015; 34: 85-91.
4. Petros P, Richardson PA. TFS posterior sling improves overactive bladder, pelvic pain and abnormal emptying, even with minor prolapse. A prospective urodynamic study Pelviperineology. 2010, 29: 52-55.
5. Bush MB, Petros PEP, Barrett- Lennard BR, On the flow through the human urethra 1997; Biomechanics 30:9,967-969.
6. Creed K. Functional diversity of smooth muscle. Br Med Bull. 1979; 3: 243-247
7. Petros PE & Ulmsten U. An Integral Theory of female urinary incontinence. Acta Obstetricia et Gynecologica Scandinavica, 1990; 69; Supp. 153: 1-79.

**PELVIC FLOOR DISORDERS: CURRENT STATUS,
TECHNOLOGICAL ADVANCES AND PERSPECTIVES****ISPP CONGRESS PRESIDENTS****GIULIO A. SANTORO
GIUSEPPE DODI****ISPP PRESIDENT****A. AKIN SIVASLIOGLU***October 6th - 8th, 2019
Treviso, Italy*www.ispp2019.com**Dear Colleagues,**

The 12th annual Congress of the International Society of Pelviperineology will be held in Treviso/Venice, Italy, from October 6th to the 8th. It is a honour to organize this meeting, involving ISPP members, experts in the field of the pelvic floor from other International Societies, and with an important participation of the Italian scientific societies of the various specialties having common pelvic interests. The approach to the pelvic floor belongs to urologists, gynecologists, colorectal surgeons, gastroenterologists, physiatrists, obstetricians, nurses, physiotherapists, psychologists, radiologists, sexologists, andrologists: a patient-centered vision is needed!

The themes chosen "Current status, technological advances and perspectives" have the ambitious aim to provide not only a consensus on the management of pelvic floor disorders, according to the evidence-based medicine and the international guidelines, but to look forward considering which are the perspectives of the new technologies. We hope that the numerous topics of the Congress (pelvic anatomy, mesh in prolapse surgery, chronic pelvic pain, therapy of urinary and fecal incontinence, pelvic floor imaging, innovation in pelvic floor surgery, pelvic floor rehabilitation) could stimulate participants to submit abstracts and videos showing their personal experience and current or future researches. In addition, pre and post-congress courses and workshops will let young doctors to receive training and education on specific topics. The aims of the ISPP, that will be confirmed and developed in the congress, are a quick realization of Masterclasses, Fellowships and of the School for the formation of the Pelvic Surgeon, as well as of Technology Partnership with all the interested Companies in our field.

Treviso, located in close proximity to Venice, is an amazing tourist destination and has a great deal to offer for those who are willing to explore. It has a Celtic origin, however in 89 BC the settlement was turned into a roman commune and developed into an important city. Throughout the middle age Treviso was part of the Lombard League and was involved in various sieges and conflicts, hence the need for stunning city walls and defensive towers. It is the site of the production of Prosecco wine and the birthplace of the dessert Tiramisù.

We wish to meet you in Treviso for a successful ISPP 2019!

Giulio A.Santoro & Giuseppe Dodi

Saturday October 5th, 2019**SOCIAL EVENTS**

Tour of Treviso
Tour of Venice
Tour of Prosecco production

Sunday October 6th 2019. DAY 1

TIME	TITLE
08:00 - 13:00	WORKSHOP 1 - PF Anatomy, Function and Dysfunction. Diagnostics and Therapy According to the Integral System
08:00 - 13:00	WORKSHOP 2 - PF Rehabilitation
08:00 - 13:00	WORKSHOP 3 - Aesthetic Gynecology and Plastic Surgery in Pelvic Floor
08:00 - 13:00	WORKSHOP 4 - New Technologies in Pelvic Floor Surgery
14:00 - 17:00	SESSION 1 : Mesh in PF Surgery: Current Status, Technological Advances and Perspectives

OPENING CEREMONY

17:30 - 17:50	Welcome Address: ISPP President, Congress Presidents, CEO of Treviso Hospital, Mayor of Treviso, Rector Magnificus of the University of Padua
17:50 - 18:20	Honorary Lecture
18:20 - 19:00	Concert
19:00 - 21:00	Welcome Buffet at the Exhibition Area

Monday October 7th, 2019. DAY 2

TIME	TITLE
08:00 - 10:30	SESSION 2: Posterior Compartment Disorders: Current Status, Technological Advances and Perspectives
11:00 - 13:00	SESSION 3: Pelvic Pain: Current Status, Technological Advances and Perspectives
13:00 - 14:00	LUNCHEON SYMPOSIUM I: New Horizons in the Treatment of Hemorrhoids
13:00 - 14:00	LUNCHEON SYMPOSIUM II: New Horizons in the Treatment of Anal Fistulas
14:00 - 16:00	SESSION 4: Video-Session and Podium Presentations
16:00 - 18:00	SESSION 5: Genetics and Hormones: Current Status, Technological Advances and Perspectives

ISPP ASSEMBLY

18:30 - 19:00	ISPP ASSEMBLY
19:00 - 19:15	Announcement of ISPP Congress 2020

SOCIAL DINNER

20:30 - 22:30	Social Dinner at Castello di Roncade*
---------------	--

Tuesday October 8th 2019. DAY 3

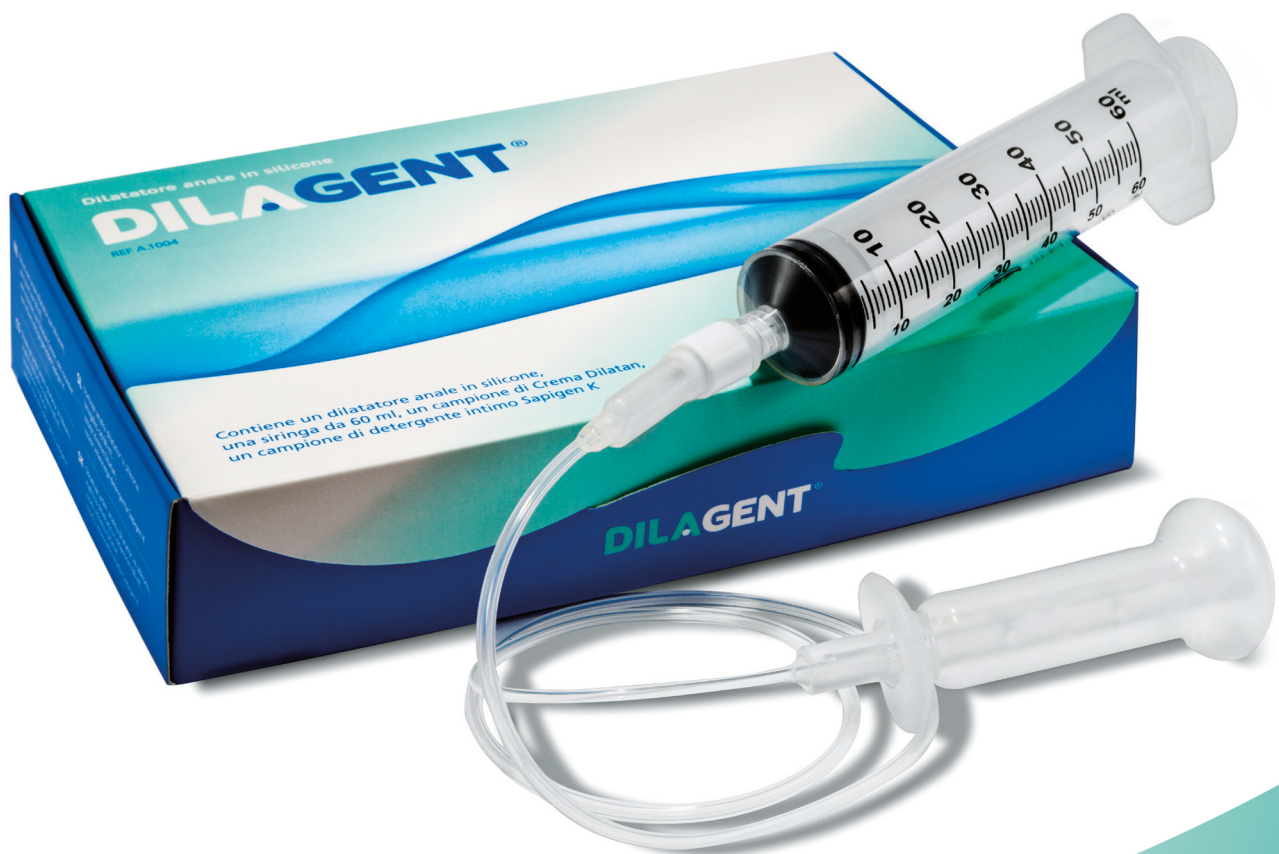TIME	TITLE
08:00 - 10:30	SESSION 6: Anatomy, Physiology and Imaging of the PF: Current Status, Technological Advances and Perspectives
11:15 - 13:15	SESSION 7: Incontinence: Current Status, Technological Advances and Perspectives

ISPP 2019 CLOSURE

13:00 - 13:15	Final Lecture
13:15 - 13:30	Best Video and Best Podium Presentations Awards
13:30	Closure of the Congress
14:00 - 18:00	WORKSHOP 5 - Sacral Nerve Stimulation in Pelvic Floor Disorders WORKSHOP 6 - PF and Anorectal Ultrasound WORKSHOP 7 - HPV-Related Lesions in Urogynecological and Proctological Practice WORKSHOP 8 - Laparoscopic Training in Pelvic Floor

DILAGENT®

Curative “exercises” for anal fissures,
haemorrhoids, hypertonic muscles
and postsurgical stenosis



DILAGENT is a soft silicone anal dilator.

It is indicated for the treatment of anorectal diseases caused by a hypertonic sphincter, namely anal fissures, haemorrhoids and painful spasms after surgical treatment of the anorectal segment. It is also effectively used in cases of postsurgical stenosis of the anal canal.