

Unusual vulvar cystic mass - suspected metastasis

CHARLOTTE NGO - RICHARD VILLET

Groupe Hospitalier Diaconesses Croix Saint Simon, Paris, France

CASE REPORT

This 73 year old caucasian woman with a previous history of breast and colon adenocarcinomas was complaining about a growing vulvar mass, with hypoaesthesia of the glans clitoridis. Examination found a tender vulvar mass located deeply in the anterior part of the left labium majora, above the urethral meatus, close to the clitoris and pubic symphysis.

There was no local inflammation. MRI showed a 3cm independent cystic mass with a thick wall between the pubic symphysis and the urethra. Surgical excision was done with a longitudinal incision between the hymen and the labium minor. The mass was freed medially from the clitoris and posteriorly from the pubic bone aponeuroses, through bulbospongi-

osus, ischiocavernosus muscles and nervus dorsalis clitoridis. Histopathology confirmed an inflammatory benign mucinous cyst, partially calcified, compatible with a Mullerian duct cyst or Gartner duct cyst. Two months after surgery the patient had recovered normal anatomy and function.

Correspondence to:

Dr. RICHARD VILLET
Groupe Hospitalier Diaconesses Croix Saint Simon
18 rue du Sergent Bauchat
75012 Paris, France
E-mail: rvillet@hopital-dcss.org

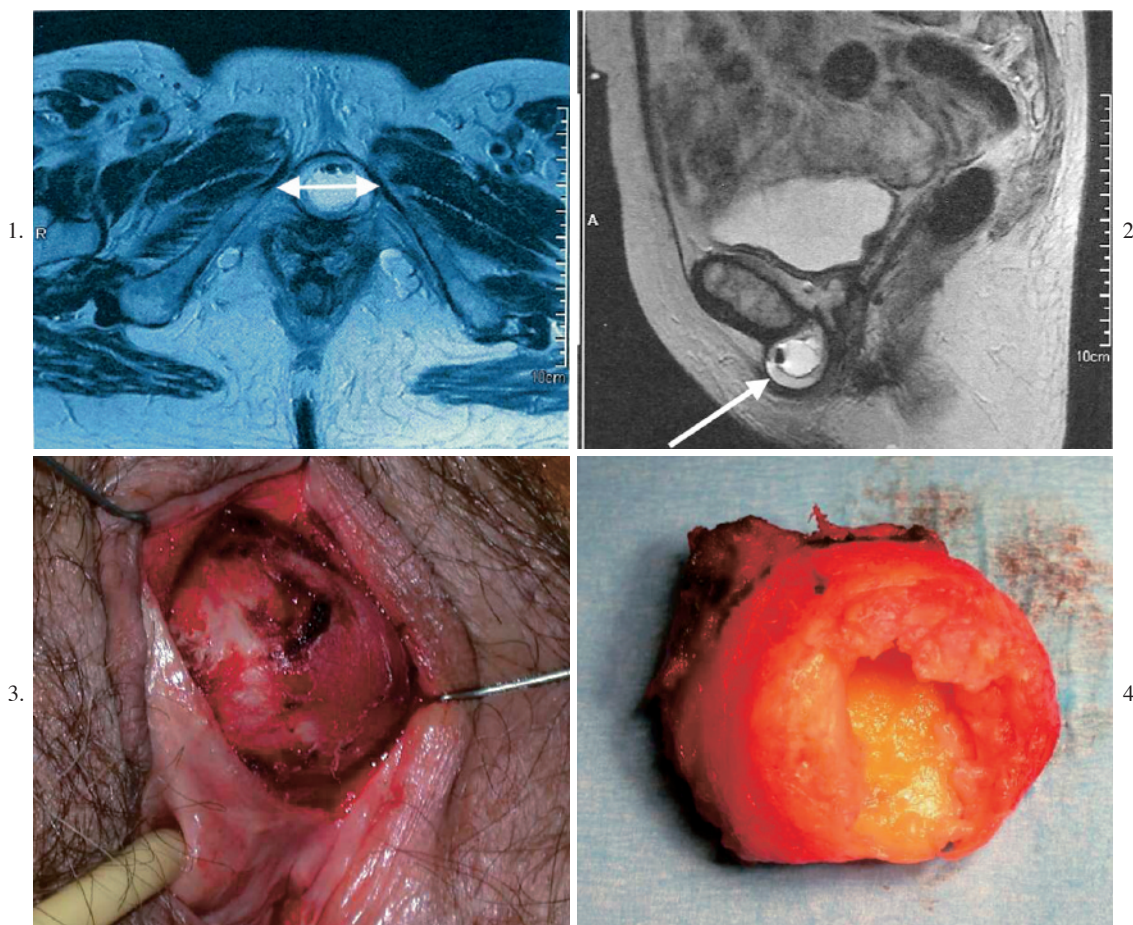


Fig. 1. – MRI transverse view; Fig. 2. – MRI Lateral view; Fig. 3. – Periurethral mass - intraoperative view; Fig. 4. – Pathological specimen of excised mass.