

Experimental Study No. 1: Directional muscle forces activate anorectal continence and defecation in the female

PETER PETROS^(*) - MICHAEL SWASH^(**)

^(*) Royal Perth Hospital, University of Western Australia

^(**) Dept of Neurology, The Royal London Hospital, London, UK

Abstract: To evaluate the hypothesis that musculoelastic forces acting around the pubourethral ligament (PUL) and uterosacral ligaments (USL) play a critical role in anorectal continence and defecation in the female. X ray video recordings, including evacuating proctograms (n = 15) were made during rest, straining and squeezing in 25 patients with urinary and fecal incontinence (FI), with radio-opaque dye in bladder, vagina, rectum and levator plate. There were 4 control patients. Surface intravaginal EMG recordings were made on separate occasions. During straining, a forward directional force (pubococcygeus) appeared to anchor the perineal body and anterior rectal wall; another forward vector (puborectalis, PRM), appeared to compress the posterior anorectal wall. Posterior vectors (levator plate and m. longitudinal muscle of the anus) stretched the rectum backwards/downwards to create the anorectal angle. During defecation, the observations were consistent with relaxation of PRM, allowing the other three directional muscle forces to actively open out the anterior and posterior walls of the anal outflow tract. All muscle forces except puborectalis appear to act against suspensory ligaments (PUL or USL) in anorectal closure and also, defecation. Compared to normal patients, the vagina and rectum were in quite vertical positions in the FI group, and were not angulated to the horizontal plane on straining. Vectors contracting against suspensory ligaments were demonstrated during anorectal closure and evacuation, consistent with the hypothesis.

Key words: Pelvic muscles; Anorectal closure; Fecal incontinence; Defecation; Connective tissue, Ligaments.

INTRODUCTION

EMG and radiological data suggest a striated muscle sphincteric mechanism¹ acting during fecal continence control. Though puborectalis and external anal sphincter muscles have been demonstrated to contract during effort,² the role of the other pelvic floor muscles has not been elucidated. The mechanism of defecation is also poorly understood. According to one description¹ feces enter the anal canal, stimulate stretch receptors and produce the urge to defecate. The internal and external anal sphincters relax, decreasing the pressure within the anus. The rectum contracts and with the assistance of raised intraabdominal pressure (Valsalva) expels the feces. No role is generally assigned for the other pelvic floor muscles. Shafik³ suggested an active muscular mechanism for anorectal opening and closure: during straining, the puborectalis, acting as the upper part of a triple loop system, contracts to close off the anal canal; during defecation, the puborectalis muscle relaxes, the levator plate contracts, and the "suspensory sling" lifts upwards to open out the anorectal canal prior to evacuation by "rectal detrusor contraction".

This observational study aimed to verify (or not), the directional muscle vectors hypothesized to act during anorectal closure, and also, defaecation. A secondary aim was to identify the hypothesized ligamentous points the vectors act against. Failure to demonstrate these vectors would seriously compromise the Theory.

PATIENTS, MATERIALS AND METHODS

A series of video X-ray studies was performed. Fecal incontinence (FI) was defined as involuntary loss of significant liquid or solid fecal material at least once per day, sufficient to present as a complaint. The diagnosis of idiopathic FI was based on clinical and endoanal ultrasound findings of a normal external anal sphincter (EAS).

X-ray studies of the organs and pelvic muscles at rest and straining

Two groups of patients were studied. The first group of 25 patients had double incontinence, urinary and fecal. Mean age was 60.5 years, range 24-76. Mean parity was 3, range

0-6. The 2nd (control) group comprised 4 patients with no history whatsoever of urinary or fecal dysfunction. Mean age was 46 years (range 29-68), parity 2 (range 1-3). As part of an IVP and cystogram investigation, they agreed to have a levator myogram. This was performed according to the protocols of Berglas and Rubin.⁴ Hard copies were taken during rest, straining, and squeezing. Ethical considerations precluded evacuating proctograms being performed on these 4 patients.

Evacuating proctograms (video)

These were performed in 15 patients with FI. Radio-opaque dye (10 ml) was also inserted into the vagina, Foley catheter balloon, and levator plate. The patients squeezed then strained prior to evacuation. During these x-ray investigations, the estimated radiation dosage did not exceed 9-10 milliSieverts.

Ethics

The levator myoproctogram investigations were carried out with informed consent, under the supervision of the Royal Perth Hospital Ethics Committee, Perth, Western Australia. The tests were ceased at n = 15, when the objectives of the trial, confirmation of the directional forces had been achieved.

EMG

On a separate occasion, simultaneous EMG recordings were taken from the distal vagina and posterior vaginal fornix in FI and control groups using a cylindrical probe during straining and squeezing. The background for this test was as follows: it is generally considered that the pelvic floor relaxes during defecation; straining at stool is a normal part of defecation, and it is said to act by increasing the intraabdominal pressure. The Musculo-Elastic Theory contradicts this view and predicts that during straining, and therefore defecation, the anterior and posterior parts of the pelvic floor contract. The x-ray studies cannot demonstrate muscle contraction. Failure to demonstrate EMG activity in the distal and proximal parts of vagina would seriously compromise the Theory.

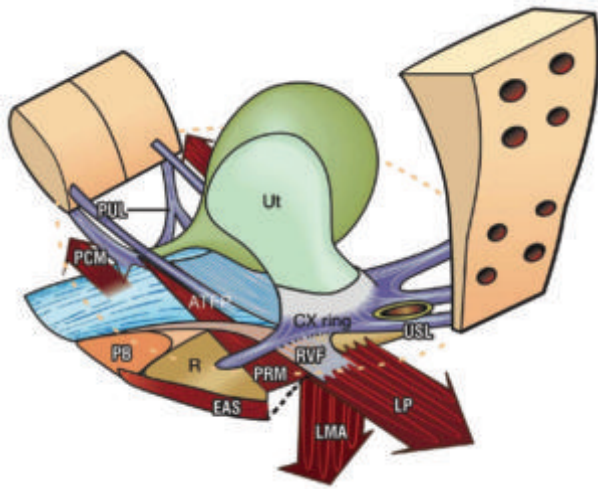


Fig. 1. – The hypothesis: directional muscle forces activate anorectal closure and defecation. 3D schematic view of pelvic structures from above and behind. Broken lines = position of anorectal angle during defecation. *Closure*: Levator plate (LP) stretches the rectum backwards against an anus laterally compressed and anchored by puborectalis (PRM). The rectovaginal fascia (RVF) is stretched backwards by LP against the perineal body (PB). The downward vector LMA (longitudinal muscle of the anus) pulls down the now extended rectum to create the anorectal angle and water-tight closure. *Defecation*: PRM relaxes. LP and LMA open out the anorectal angle. Rectum (R) contracts to evacuate. PUL = pubourethral ligament; USL = uterosacral ligament; EAS = external anal sphincter. m. pubococcygeus (PCM) tensions distal vagina, PB and the anterior anal wall during closure and defecation.

RESULTS

The video-radiological studies (Figs 2-7), confirm the 4 directional movements hypothesized to act in anorectal closure, the 3 in defecation, and the anatomical points against which they act (Fig. 1). There was no difference between the continent and incontinent groups as concerns these directional movements whatever the manoeuvre tested: straining, coughing, and “squeezing”. Qualitative differences, such as apparent laxity of various organ structures were, however, noted. The vagina and rectum appeared to be stretched more tightly during straining in the patients without urinary or fecal incontinence.

X-ray studies of the organs and pelvic muscles at rest and straining

Control group (n = 4). On comparing the resting films (Fig. 2), with the straining films (Fig. 3), four directional forces become evident (arrows). These appear to stretch the vagina and rectum between ‘X’ and ‘Y’, the exact positions of the pubourethral and uterosacral ligaments, much like a trampoline. The perineal body provides anatomical support for more than 50% of the posterior vaginal wall. The perineal body, distal parts of the vagina and midurethra appear to be pulled forwards (forward arrow). There is a distinct indentation of the anal wall, consistent with a force applied from behind, consistent with puborectalis muscle contraction (curved arrow). The rectum and upper part of the vagina are stretched backwards against “X” and downwards against “Y”, arrows (Fig. 3). In addition, the anterior part of the levator plate becomes angulated downwards. These video studies indicated a clear relationship between the downward angulation of levator plate and downward displacement of the vagina and rectum, consistent with the fascial attachments of the organs to these ligaments (Fig. 1). Like an elastic membrane, the rectum was markedly altered in shape and position during pelvic floor or pelvic organ movement. Thus

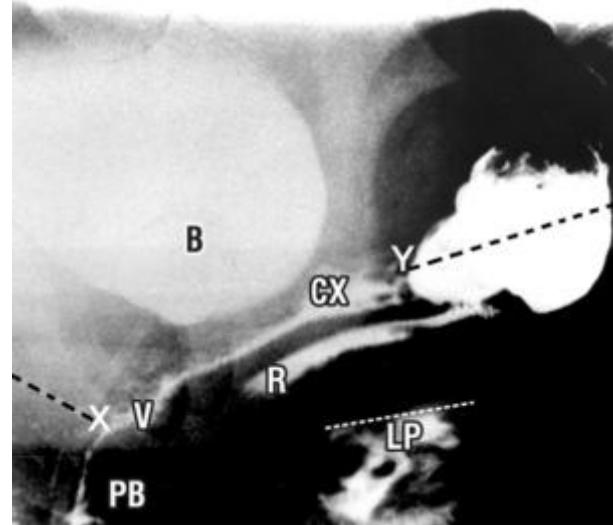


Fig. 2. – Patient continent of urine and feces. Sitting lateral X-Ray, with radio-opaque dye in bladder (B), vagina (V), rectum (R) and levator plate (LP). A white diagonal line represents the superior border of LP. PB = perineal body; R = rectum; CX = cervix; ‘X’ & ‘Y’ = insertion of the pubourethral and uterosacral ligaments (black broken lines).

it was stretched upwards and forwards during “squeezing” (“lifting up”) (as in Fig. 4), but backwards and downwards during straining. Coughing caused an identical, but much faster organ movement than that observed during straining.

During straining, fecal incontinence group (Fig. 6), the same directional muscle forces appear to be acting on the organs as in Fig. 3, anteriorly, posteriorly and inferiorly. Compared to Figs 2 and 3, the angulation of the vagina in the FI group is almost vertical at rest (Fig. 5), and on straining (Fig. 6), a stark contrast to the anorectal angulation obvious in Fig. 3. The perineal body is not nearly as prominent in Fig. 6 as in Fig. 3. Relative to Fig. 5, the posterior wall of the rectum appears to have been pulled forwards to the vertical position during straining (Fig. 6), consistent with contraction of the puborectalis muscle, accentuating the anorectal angle, but not as much as in Fig. 3. Inferiorly,

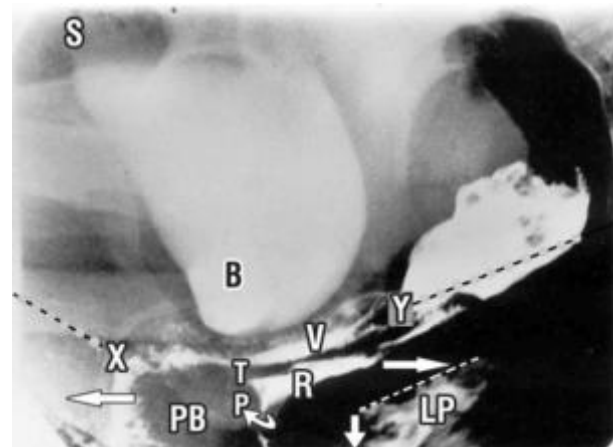


Fig. 3. – Straining, normal patient *anorectal closure* - same patient and labelling as Fig. 2. With reference to Figs. 1 & 2, arrows denote directional movement of the organs; P (curved arrow) = action of m. puborectalis; the forward and backward directional arrows pull against “X” (pubourethral ligament), and the downward arrow against “Y” (uterosacral ligament). The anterior wall of rectum appears to be anchored at “T”, the site of insertion of m. deep transversus perinei. The rectum ‘R’ is stretched backwards and rotated around an anus firmly anchored by m. puborectalis ‘P’.

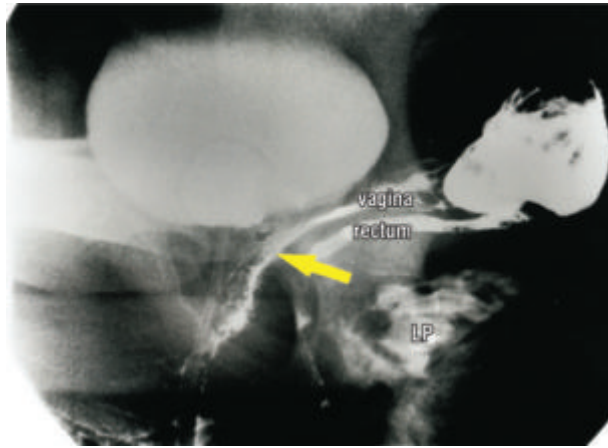


Fig. 4. - Squeezing normal patient same patient and labelling as Fig. 2. Relative to Fig. 2, there is: indentation of bladder base; marked angulation of vagina and rectum; approximation of LP to rectum; upward stretching of levator plate (LP) to the horizontal position; all these movements are consistent with upward contraction of an underlying muscle, m.puborectalis (arrow).

angulation downwards of the anterior border of levator plate (LP) is seen, (downward arrow, Fig. 6), and this is consistent with contraction of the longitudinal muscle of the anus.

During squeezing, fecal incontinence group (Fig. 7). All the organs have been pulled upwards and forwards, as in Fig. 4, apparently by contraction of the puborectalis muscle, PRM, which lies below the levator plate muscles.

During defecation, fecal incontinence group (Fig. 8). The same three directional muscle forces seen during straining, Fig. 3, seem to be acting on the walls of the anus and rectum: the distal vagina is pulled forwards; the rectum and proximal vagina have been pulled backwards; levator plate is angulated downwards; The anus has been opened out, consistent with puborectalis muscle 'PRM' relaxation. As in Fig. 6, 'T', the insertion of the deep transversus perinei, and "X", the insertion of the pubourethral ligament appear to be acting as firm anchoring points for backward stretching of bladder, vagina and rectum by LP.

Surface EMG activity was noted in the distal vagina and posterior fornix during straining and squeezing.

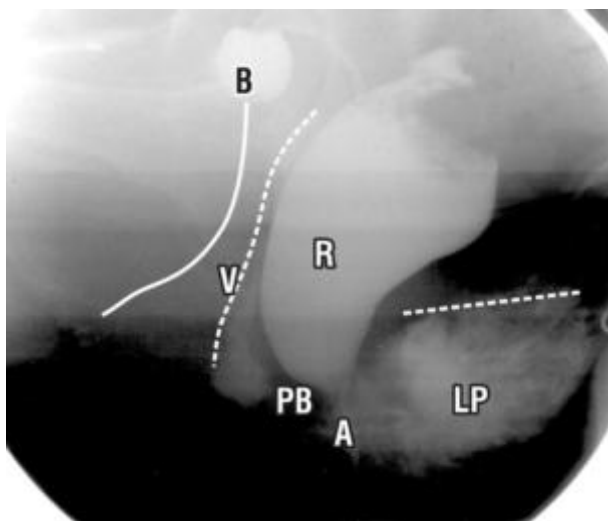


Fig. 5. - Resting position - fecal incontinence patient Sitting position. Labelling as per Fig. 2. A = anus; white broken horizontal line = superior border of LP. Vertical broken lines "V"= vagina; unbroken vertical line = urethra; B = bladder; R = rectum.

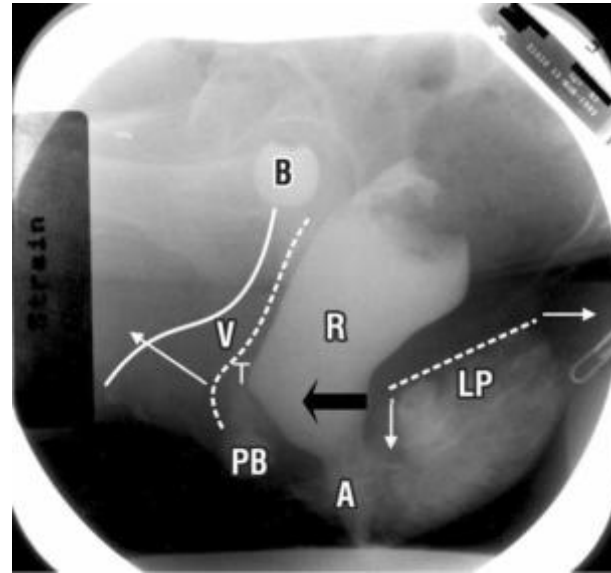


Fig. 6. - "Pre-Evacuation strain" Same patient & labelling as fig 5, sitting position. With reference to the resting state, Fig. 5, note: forward stretching of distal vagina "V"; downward angulation of anterior border of levator plate (LP); the distal part of the posterior rectal wall has become vertical, consistent with forward contraction of puborectalis (black arrow); entry of material into anus "A", consistent with the diagnosis of fecal incontinence; "pinching" of anterior rectal wall at "T", consistent with anchoring by m. deep transversus perinei.

DISCUSSION

It is evident on comparing the resting and straining Figs. 2 and 3 (normal) with Figs. 5 and 6 (FI group), that, even during straining, the vagina and rectum are quite vertical in the FI group, and are not stretched to the horizontal plane as in the normal group. We believe that angulation towards the horizontal plane is an essential element for anorectal angle formation, and therefore, 'airtight' closure. In a previous study,⁵ inability to angulate below 45 degrees on straining was attributed to lax connective tissue, as there was clear evidence of the directional muscle forces continuing to function in such patients.

The video X-ray studies are consistent with the hypothesis, four directional muscle forces acting during anorectal closure, and three during defecation (Fig. 1). During anorec-

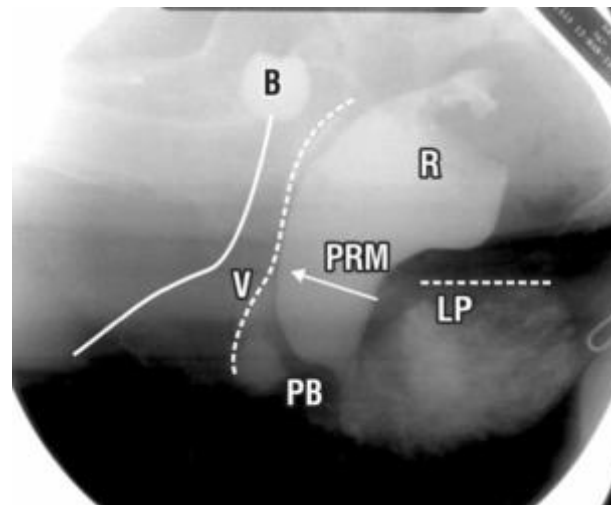


Fig. 7. - Squeeze Same patient as Fig 5, sitting position. All the organs and LP have been pulled upwards and forwards, consistent with contraction of the puborectalis muscle, PRM.

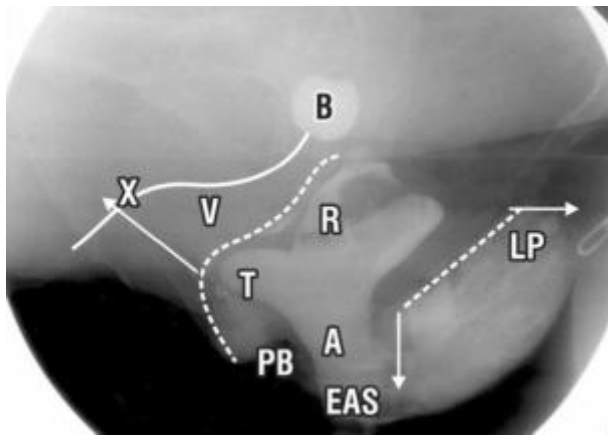


Fig. 8. – Defecation Same patient and labelling as Fig. 5, sitting position. Arrows denote directional movement of the organs consistent with stretching by muscle forces. Note: forward stretching of distal vagina “V”; backward stretching of proximal vagina, bladder (B) and rectum (R); downward angulation of levator plate (LP); marked widening of the anal canal (A); bulge at “T” consistent with anchoring by m. deep transversus perinei. EAS = position of external anal sphincter.

tal closure, and also, defecation, the pubourethral ligaments, uterosacral ligaments and perineal body, appear to be critical anchoring points for rotation and downward displacement of the stretched vagina and rectum (Fig. 1). The straining X-rays are consistent with

a) contraction of puborectalis being a prerequisite for functioning of the musculoelastic sphincter which rotates the rectum around the anus (Fig. 3).

b) The perineal body being anchored by pubococcygeus and deep transversus perinei. The defecation X-rays are consistent with relaxation of puborectalis allowing the other three muscle forces to uninhibitedly stretch and open out the anorectal canal for emptying by rectal contraction. The site of action of the vector forces is consistent with previous anatomical descriptions, pubococcygeus (forwards)⁶ levator plate (backwards)¹⁰ and longitudinal muscle of the anus (downwards).^{7,8}

Recording of EMG activity during straining and squeezing, though not specific for a particular muscle, indicates striated muscle activity consistent with activation of pubococcygeus in the distal vagina, and levator plate, longitudinal muscle of the anus, and puborectalis in the proximal vagina.

There were no differences between normal (Fig. 3) and FI patients (Fig. 6) in the direction of the vector forces during straining. However, entry of feces into the anorectum (Fig. 6) indicates obvious qualitative differences.

The X-ray studies also partly tested Shafik’s theory of normal anorectal function.³ Shafik’s prediction of puborectalis contraction during anal canal closure was validated. Shafik assigned no role for levator plate contraction during anorectal closure. Shafik stated that the rectum is lifted

upwards by the “suspensory sling” to open out the anorectal canal prior to evacuation by rectal detrusor contraction. Contrary to this view, the X-rays demonstrate a backward /downward movement of the rectum, and downward angulation of the anterior lip of levator plate, which seemed to be maintained during evacuation (Fig. 8). Shafik assigned no role for ligaments or connective tissue in his theory, either for function or dysfunction.

CONCLUSIONS

The observations confirm the participation of directional muscle forces acting against pubourethral and uterosacral ligaments during anorectal closure and also, defecation. Prospective surgical reinforcement of these ligaments will be required to test the hypothesis that ligamentous damage is a major cause of idiopathic FI. The results from such operations are described in Part 2.

REFERENCES

1. Bartolo, DCC, and Macdonald ADH. Fecal continence and defecation. In: *The Pelvic Floor, Its functions and disorders*. Eds Pemberton J, Swash M, and Henry MM. WB Saunders, London, 2002: 77-83.
2. Freckner B, Von Euler C. Influence of pudendal block on the function of anal sphincters. *Gut* 1975; 16: 482-489.
3. Shafik A. A new concept of the anatomy of the anal sphincter mechanism and the physiology of defecation. *Colo-proctology* 1982; 4: 49-54.
4. Berglas B, and Rubin IC. Study of the supportive structures of the uterus by levator myography. *Surg Gynecol Obst* 1953; 97: 677-692.
5. Petros PE. Vault prolapse 1: dynamic supports of the vagina. *Int J Urogynecol and pelvic floor* 2001; 12: 292-295.
6. Zacharin RF. The suspensory mechanism of the female urethra. *Journal of Anatomy* 1963; 97: 423-427.
7. Thompson R. The myology of the pelvic floor: a contribution to human and comparative anatomy. As quoted by Zacharin in *Pelvic Floor Anatomy and Surgery of Pulsion Enterocoele*, Springer-Verlag, Wien, 1985; 18-49.
8. Courtney H. Anatomy of the pelvic diaphragm and ano-rectal musculature as related to sphincter preservation in ano-rectal surgery. *American Journal Surgery* 1950; 79: 155-173.
9. Macchi V, Porzionato A, Stecco C, Benettazzo F, Stecco A, Parenti A, Dodi G, De Caro R. Histo-topographic study of the longitudinal anal muscle. *Pelviperrineology* 2007; 26: 30-32.

ACKNOWLEDGEMENTS

To the Dept of Medical Illustrations, and Dr Richard Mendelson, from the Dept of Radiology, Royal Perth Hospital.

Competing interests: None.

Correspondence to:

PETER PETROS

E-mail: kvinno@highway1.com.au