

# Transperineal rectocele repair with porcine dermal collagen implant. A two-year clinical experience

GIOVANNI MILITO, FEDERICA CAEDDU, IVANA SELVAGGIO,  
MICHELE GRANDE, ATTILIO M. FARINON

*University Hospital Tor Vergata, Rome, Italy*

**Abstract:** Purpose: Symptomatic rectocele results in obstructed defecation and constipation. Surgical repair may provide symptomatic relief. A variety of both synthetic and nonsynthetic graft materials have been used in the rectocele repair to enhance anatomical and functional results, and to improve long-term outcomes. Methods: In this prospective study we treated a series of 10 women suffering from symptomatic rectocele with transperineal repair using porcine dermal acellular collagen matrix BioMesh (Pelvicol™). Results: Follow-up ranged from 2 to 20 months and all patients demonstrated good anatomical results; thus far there have been no difficulties with delayed healing. There were no major intraoperative or postoperative complications (infection, abscess, hematoma, either vaginal or rectum injury, transfusion). There have been no complaints related to bowel function, and those patients who were sexually active prior to surgery have not experienced problems with sexual function or dyspareunia. Conclusions: Rectocele repair with Permacol® by the transperineal approach seems an effective and safe procedure that avoids some of the complications associated with synthetic mesh use. Randomized prospective studies with long-term follow-up and documentation of both safety and efficacy using validated questionnaires and quality of life surveys are warranted to confirm these results.

**Keywords:** Rectocele, Obstructed defecation, Biofeedback, Biomesh.

## INTRODUCTION

Rectocele is an herniation of the rectum through the rectovaginal fascia and posterior vaginal wall causing a protrusion into the vaginal lumen. It's a common disorder in women with history of multiple vaginal deliveries and it is asymptomatic in 80% of cases. Symptomatic rectocele is less common, usually affects postmenopausal females, and results in obstructed defecation and constipation.

Surgery should be considered when conservative therapy fails and a careful patient selection, based on an accurate morpho-functional assessment, is crucial to obtain a satisfactory outcome<sup>1,2</sup>.

The purpose of surgical repair in the management of rectocele repair are essentially the restoration of normal vaginal anatomy and the restoration or maintenance of normal bladder, bowel, and sexual function<sup>1,2</sup>.

Transperineal repair of the fascial defect may provide restoration of normal anatomy and symptomatic relief. A variety of both synthetic and nonsynthetic graft materials have been used in the rectocele repair to enhance anatomical and functional results and improve long-term outcomes.

Recent advances in pelvic reconstructive surgery are due in part to the availability of new graft materials that allow reinforcement and repair of large pelvic fascial defects minimizing adverse graft-related effects and infections. Porcine acellular collagen matrix (Permacol®) seems to relief symptoms minimizing postoperative complications<sup>1-5</sup>.

This prospective study was designed to assess the short and medium-term outcomes and the safety of transperineal rectocele repair with an acellular porcine dermal collagen implant (Permacol®) in a cohort of 10 women with symptomatic rectocele after medical treatment failure.

## MATERIALS AND METHODS

Between January 2008 and January 2010, 10 women presenting with symptomatic rectocele after medical treatment failure, were evaluated and surgically treated at the Division of General Surgery of the Department of Surgery, Tor Vergata University Hospital, Rome.

All the patients underwent a pre-treatment evaluation, which included anamnesis, concerning pregnancies, episiotomy, previous gynaecological, urological, or ano-rectal surgery and symptoms, clinical examination of the perineum, rectum and vagina, ano-rectal manometry, anoscopy and defecography.

Ano-rectal manometry was performed at rest, after voluntary contraction (ie, the maximal voluntary increase above the resting tone) and during straining. At defecography, resting state, voluntary and maximum contraction of the sphincter and pelvic floor muscles, and straining during defecation were recorded. Rectal emptying was also assessed. X-ray films were taken in each position and dynamic assessment of the defecation was also obtained.

All patients were operated on by the same senior surgeons (G.M.).

Written informed consent had been obtained from all the subjects after a full explanation of the procedure.

Regarding the surgical technique, a transverse perineal incision was made, and the plane between the external anal sphincter and the posterior vaginal wall was developed with diathermy to ensure meticulous hemostasis. The dissection was extended to the vaginal apex to expose the rectocele, the perirectal fascia and the levator arc. Following the site-specific repair, four to five absorbable sutures (2/0 Vicryl, Ethicon, Somerville, N.J., USA) were placed in the levator arc, beginning near the vaginal apex and continuing distally toward the perineal body. A Permacol® BioMesh was affixed to these sutures and laid in place in the rectovaginal space. Using the same type sutures, the graft was then sutured to the levator arc on the opposite side followed by closure of perineal incision.

A vaginal pack and urinary catheter were placed for the first 24 h. Prophylactic antibiotics and antimicrobial irrigation solution were used to decrease the risk of postoperative infection. In every patient metronidazole was given intravenously at the beginning of the operation and after surgery for 5 days (500 mg three times daily).

Patients were clinically assessed at the first follow up visit up to 7 days after the operation. Subsequently they were followed up every 15 days for the first 2 months and follow up controls were planned at 6, 12, 24 and 36 months.

Demographic data faecal continence and complications were recorded. Degree of continence was scored according to the Wexner continence score.

The scoring system of Watson<sup>6</sup> was adopted for evaluating the clinical symptoms of perineal digitation, straining, incomplete evacuation, and vaginal bulging. Each symptom was graded from 0 to 3, and the maximum total score was 12.

For objective evaluation of anatomic repair, the patients were examined on the proctologic examination table by an

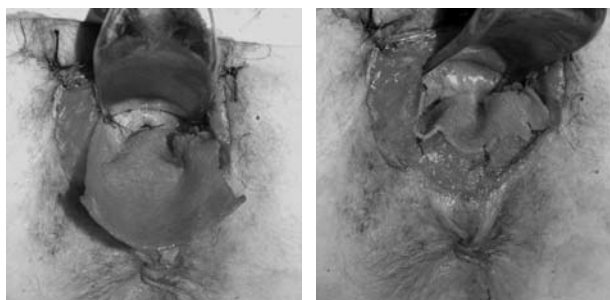


Fig. 1. a,b – Transperineal rectocele repair with biomesh. The mesh is placed in the recto-vaginal space and fixed with interrupted sutures to the levator ani plate on both sides.

independent observer with a finger inserted in the rectum to elevate the anterior rectal wall.

The quality of life was evaluated using SF-36 questionnaire. During follow up visits all patients were submitted to clinical examination of the perineum, rectum and vagina, digital exploration and anoscopy. Rx defecography was performed at 2 months follow up Rx defecography was planned at 12, 24 and 36 months.

All statistical elaborations were obtained by using Statistics for Windows (Statsoft; Tulsa, Okla, USA). The results were expressed as mean  $\pm$  standard deviation ( $\pm$ SD); Wilcoxon's signed-rank test was used for differences between preoperative and follow-up symptom scores.  $P < 0.05$  was considered as significant.

## RESULTS

Between January 2008 and January 2010, 10 women presenting with symptomatic rectocele after medical treatment failure, were evaluated and surgically treated at the Division of General Surgery of the Department of Surgery, Tor Vergata University Hospital, Rome.

The study was approved by the Institutional Committee of the Tor Vergata University of Rome.

Baseline characteristics of patients are showed in table 1. Follow-up ranged from 2 months to 20 months.

At 2 months, the mean total Watson score was significantly lower than the preoperative score ( $P < 0.0001$ ) (table 2) and every patient has demonstrated good anatomical results.

There were no major intraoperative or postoperative complications (infection, abscess, hematoma, rectal or vaginal injury, blood loss, or transfusion).

One case of urinary infection solved with antibiotics was recorded. One patient had delayed wound healing of the perineal incision with completed wound healing 21 days after the intervention.

At two months follow up, there have been no complaints related to bowel function, and those patients who were sexually active prior to surgery have not experienced problems with sexual function postoperatively. The anterior rectocele was significantly reduced in size ( $< 2$  cm) in all patients after surgery at defecography.

Improvements in the mental and physical component scores of the SF-36 were recorded but were not statistically significant ( $p > 0.05$ ).

Five patients were followed up at 12 months. No patient experienced sexual function problems; two patients referred straining grade 2 and showed a rectal wall bulging of 2 cm at defecography.

## DISCUSSION

The goal of surgery in the management of rectocele are the restoration of normal anatomy and the restitution or maintenance of normal bowel and sexual function<sup>1-3</sup>.

Three different approaches have been reported for rectocele repair: transanal approach which consists of mucosal resection and anterior rectal wall plication; transvaginal approach which includes excision of part of the posterior vaginal wall and anterior levatorplasty; finally the transperineal approach which consists of extraluminal anterior access to the rectocele and biomesh placement in the rectovaginal space<sup>4,7-11</sup>.

Both transanal and transvaginal repairs have shown several limitations: resting and squeeze pressure reduction after transanal repair; dyspareunia and obstructed defecation persistence after transvaginal repair<sup>7</sup>.

Rectocele repair with biomesh (Permacol®) by the transperineal approach seems an effective and safe procedure that avoids some of the complications associated with synthetic mesh use<sup>11</sup>.

Permacol® is an acellular sheet of porcine dermal collagen in which the collagen fibers have been cross-linked using diisocyanate to avoid graft biodegradation. Permacol® is not cytotoxic, hemolytic, pyrogenic or allergenic and it has been helpful in inguinal, incisional and parastomal hernia repairs. Permacol® seems especially helpful in the perineal repairs that are at high risk of wound contamination that would contraindicate the use of synthetic meshes given the possibility of chronic infection and fistulation<sup>11,12</sup>.

TABLE 1. – Baseline characteristics of patients.

Patient	Age	Mean Resting Pressure	Mean Squeeze Pressure	Asimmetry Index At Rest	Asimmetry Index At Squeeze	Defecographic pattern
1	58	36,5	48,2	43,5	35,1	Rectocele 3 cm; incompl emptying
2	37	37,6	67,3	35,6	36,5	Rectocele 3,5cm; incompl emptying
3	46	30,9	38,9	39	40,7	Rectocele 2.5 cm; incompl emptying
4	26	58,3	61,5	44,8	28,3	Rectocele 4 cm; incompl emptying
5	48	61,2	93,7	25,1	15,4	Rectocele 3cm; incompl emptying
6	55	55,9	98,8	28,7	22,4	Rectocele 5 cm; incompl emptying
7	25	14	31	30,7	25,2	Rectocele 3,5 cm; incompl emptying
8	70	36,7	56,8	27,8	19,8	Rectocele 5 cm; incompl emptying
9	65	39,2	49,5	48,2	42,5	Rectocele 3,5 cm; incompl emptying
10	47	36,5	48,2	43,5	35,1	Rectocele 4.5 cm; incompl emptying

TABLE 2. – Symptoms' score of the patients

Symptoms	Preoperative	Postoperative	P*
Perineal digitation	2.52 ± 0.53	0.67 ± 0.58	0.0001
Straining	2.61 ± 0.57	0.14 ± 0.41	0.0001
Incomplete evacuation	2.45 ± 0.75	0.53 ± 0.60	0.0001
Vaginal bulging	2.34 ± 0.62	0.26 ± 0.44	0.0001
Total	9.65 ± 1.83	1.61 ± 0.55	0.0001

Actually, given the immediate contact between vaginal, rectal wall and underlying host tissues through fenestrations in the mesh graft material, delayed healing and infective complications seem less frequent.

In a recent experimental study<sup>13</sup> comparing intraperitoneal implantation of polypropylene versus dermal collagen in 16 rats, histological examination at 4 weeks showed intense inflammatory response with disorganized collagen in the polypropylene group and minimal inflammatory response with thin collagen in the collagen group.

Similarly this histological view showed vascular ingrowth stimulated by collagen mesh 14 days after dermal collagen implant in an experimental model.

If we overview the literature, although there are only few clinical studies, good results have been reported by all the authors in line with our experience<sup>9-16</sup>.

Smart and coworkers<sup>10</sup> recently reported a series of 10 women treated with transperineal biomesh implant. Eighty percent of treated patients referred constipation improvement, 70% reported improvement of vaginal bulging. Two cases of perineal hematoma and one case of dyspareunia were recorded in absence of infections and relapse.

In a larger trial Leventoglu<sup>14</sup> treated 84 women with symptomatic rectocele with transperineal collagen implant. Anatomic repair was assessed in 89% of patients and there was a significant improvement of constipation and vaginal bulging. Morbidity rate was 8%. Neither mesh infection nor mesh rejection nor sexual function worsening were detected.

Considering the results of transvaginal biomesh repair, Kohli and co-workers successfully treated 43 women with rectocele using transvaginal biomesh repair and reported no defecatory and vaginal symptoms in all patients 12 months after the operation.

Dell and co-workers<sup>9</sup> recently reported a series of 35 patients successfully treated with porcine dermal collagen bioMesh in absence of major complications. Neither defecation disorder nor vaginal bulging were referred after the operation at an average follow up of 12 months.

Finally, Altman and coworkers<sup>12,17</sup> reported a series of 29 patients treated with transvaginal implant of biomesh with defecation and vaginal bulging improvement. At 12 month follow up 14 women had no rectocele.

More recently, Novi<sup>16</sup> studied sexual function after rectocele transvaginal biomesh repair in 100 women with questionnaires to evaluate quality of life and symptoms relief and found improvement of sexual function in absence of dyspareunia.

In summary, transperineal rectocele repair with biomesh seems an effective and safe procedure that avoids complications associated to synthetic mesh use avoiding rectal sutures and preserving both rectum and vagina<sup>18,19</sup>. However, large randomized prospective studies are warranted

to confirm these results and to explore mid and long term effects regarding relapse, sexual and gastrointestinal function.

## REFERENCES

1. Maher C, Baessler K, Glazener CM, Adams EJ, Hagen S. Surgical management of pelvic organ prolapse in women. *Cochrane Database Syst Rev* 2004; 4:CD004014
2. American College of Gastroenterology Constipation Task Force (2005) An evidence-based approach to the management of chronic constipation in North America. *Am J Gastroenterol* 100 Suppl 1:S1-S4.
3. Brandt LJ, Prather CM, Quigley EMM, Schiller L, Schoenfeld P, Talley NJ. Systematic review on the management of chronic constipation in North America *Am J Gastroenterol* 2005; 100 Suppl 1:S5-S21
4. Ho YH, Ang M, Nyam D, Tan M, Seow-Choen F. Transanal approach to rectocele repair may compromise anal sphincter pressures *Dis Colon Rectum* 1998; 41: 354-358
5. Miliacca C, Lombardi AM, Bilali S, Pescatori M. The "Draw-a-family" test in the evaluation of patients with colorectal diseases. *Pelvi-Perineology RICP* 2006; 25:15-18.
6. Watson SJ, Loder PB, Halligan S, Bartram CI, Kamm MA, Phillips RK. Transperineal repair of symptomatic rectocele with Marlex mesh: a clinical, physiological and radiologic assessment of treatment. *J Am Coll Surg* 1996;183:257-61.
7. Pescatori M, Milito G, Fiorino M, Cadeddu F. Complications and reinterventions after surgery for obstructed defecation. *Int J Colorectal Dis.* 2009; 24: 951-959
8. Richardson AC. The rectovaginal septum revisited: its relationship to rectocele and its importance in rectocele repair. *Clin Obstet Gynecol* 1993; 36: 976-983.
9. Dell, JR, O'Kelley, KR. PelviSoft BioMesh augmentation of rectocele repair: the initial clinical experience in 35 patients. *Int Urogynecol J Pelvic Floor Dysfunct* 2005; 16: 44-47
10. Smart NJ, Mercer-Jones MA. Functional outcome after transperineal rectocele Repair with porcine dermal collagen implant. *Dis Colon Rectum* 2007; 50: 1422-1427
11. Milito G, Cadeddu F, Grande M, Selvaggio I, Farinon Am. Advances in treatment of obstructed defecation: Biomesh transperineal repair *Dis Colon Rectum.* 2009; 52: 2051
12. Altman D, Zetterström J, Mellgren A, Gustafsson C, Anzén B, López A. A three-year prospective assessment of rectocele repair using porcine xenograft. *Obstet Gynecol.* 2006; 107: 59-65.
13. Himpson RC, Cohen CR, Sibbons P, Phillips RK An experimentally successful new sphincter-conserving treatment for anal fistula *Dis Colon Rectum.* 2009; 52: 602-8
14. Leventoglu S, Menteş Bb, Akin M, Karen M, Karamercan A, Oğuz M. Transperineal rectocele repair with polyglycolic acid mesh: a case series. *Dis Colon Rectum.* 2007 Dec 50: 2085-92
15. Kohli N, Miklos Jr. Dermal graft-augmented rectocele repair. *Int Urogynecol J Pelvic Floor Dysfunct.* 2003; 14: 146-9
16. Novi Jm, Bradley Cs, Mahmoud Nn, Morgan Ma, Arya La. Sexual function in women after rectocele repair with acellular porcine dermis graft vs site-specific rectovaginal fascia repair. *Int Urogynecol J Pelvic Floor Dysfunct.* 2007; 18: 1163-9.
17. Altman, D, Mellgren, A, Blomgren, B, Lopez, A, Zetterstrom, J, Nordenstam, J. Clinical and histological safety assessment of rectocele repair using collagen mesh. *Acta Obstet Gynecol Scand* 2004; 83: 995-1000
18. Hanson, JM, Aspin, B, Spalding, LJ, Varma, JS. Transperineal repair of rectocele using porcine collagen. *Colorectal Dis* 2004; 6: 36
19. Maher, C, Baessler, K. Surgical management of posterior vaginal wall prolapse: an evidence-based literature review. *Int Urogynecol J Pelvic Floor Dysfunct* 2006; 17: 84-88.

Correspondence to:

Prof. Giovanni Milito

Department of Surgery University Hospital Tor Vergata

Viale Oxford, 81 - 00133 Rome, Italy.

Phone +39.06.20902976

Fax +39.06.20902976

E-mail giovanni.milito@virgilio.it