

As announced in the Editorial by Bruce Farnsworth (*Pelviperrineology* 2011; 30:5) this is the fifth of a series of articles highlighting the different sections of the book “*Pelvic Floor Disorders, Imaging and a Multidisciplinary Approach to Management*” edited by G.A. Santoro, P. Wiczorek, C. Bartram, Springer Ed, 2010.

Fecal incontinence

GIULIO A. SANTORO¹, ANDRZEJ P. WIECZOREK², MAGDALENA M. WOŹNIAK²,
ALEKSANDRA STANKIEWICZ²

¹ Pelvic Floor Unit, 1^o Department of Surgery, Regional Hospital, Treviso, Italy

² Department of Pediatric Radiology, University of Lublin, Poland

The fifth section of the book “Pelvic floor disorders-Imaging and Multidisciplinary Approach to Management” entitled “Fecal Incontinence” consists of twelve chapters divided into two subsections describing diagnostic modalities and management for this disorder.

In the first chapter “Three-dimensional Endoluminal Ultrasonography” G. Di Falco and GA Santoro describe the role of endoanal ultrasonography in the patients with fecal incontinence. This technique is considered the gold standard in the assessment of anal sphincters and enables to differentiate between incontinent patients with intact anal sphincters and those with sphincter lesions (defects, scarring, thinning, thickening, and atrophy). High-resolution multiplanar reconstructions and rendering techniques available in 3D imaging (Figure 1a-b) enhance the accuracy of EAUS and its diagnostics value allowing for instance detection of occult sphincter tears. The technique also serves as a tool to establish the most appropriate therapy (sphincteroplasty, graciloplasty, injection of bulking agents, sacral nerve stimulation) and to monitor results following surgical treatment.

In the second chapter entitled “Transperineal Ultrasonography”, B. Roche, G. Zufferey and J.R.Yap present the transperineal ultrasound as an easy to perform, fast examination in the assessment of rectoceles, intussusceptions, evacuatory apparatus lesions, and perineal muscle movement. This technique allows to evaluate this disorders quickly and accurately and prescribe appropriate therapy.

Authors reported that measurement of displacement of the puborectal sling enables prediction of sphincter repair outcome as a treatment of fecal incontinence, which has an important clinical value. Moreover, the reproducibility of this test is rather good, and the technical training period quite short.

In the third chapter “Magnetic Resonance Imaging” J. Stoker describes the technique, patient preparation and imaging findings in the patients with fecal incontinence. Endoanal MRI has been demonstrated to be comparable to endoanal ultrasound in the detection of external sphincter defects and could be used as an alternative, especially in cases with external sphincter atrophy. External sphincter atrophy at endoanal MRI has been demonstrated to be a negative predictor of the outcome of anterior anal repair. Thus, in candidates for anterior anal repair, endoluminal MRI should be considered, in order to identify patients with external sphincter atrophy.

In the fourth chapter entitled “Anorectal Manometry”, F. Pucciani reviews information on anorectal manometry. Its clinical utility is limited by the relative absence of standardization of test protocols and normative data from a large number of healthy individuals, however anorectal manometry is considered a valuable functional test for the diagnosis and management of fecal incontinence. When anorectal manometry is used in incontinent patients, its data suggest which continence mechanisms may be malfunctioning. However, manometric findings in incontinent pa-

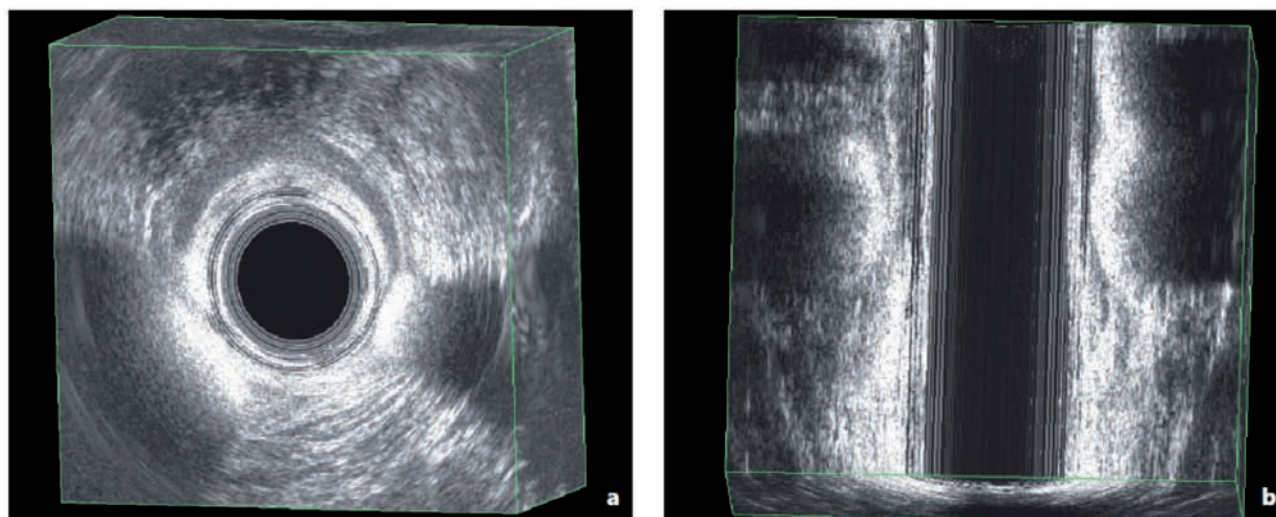


Figure 1a. — Bulking agent injection visible as two hyperechoic bands with strong reflection at 4 and 7 o'clock. b) Reconstruction in coronal plane allows evaluation of the correct position and extent of the injected material.

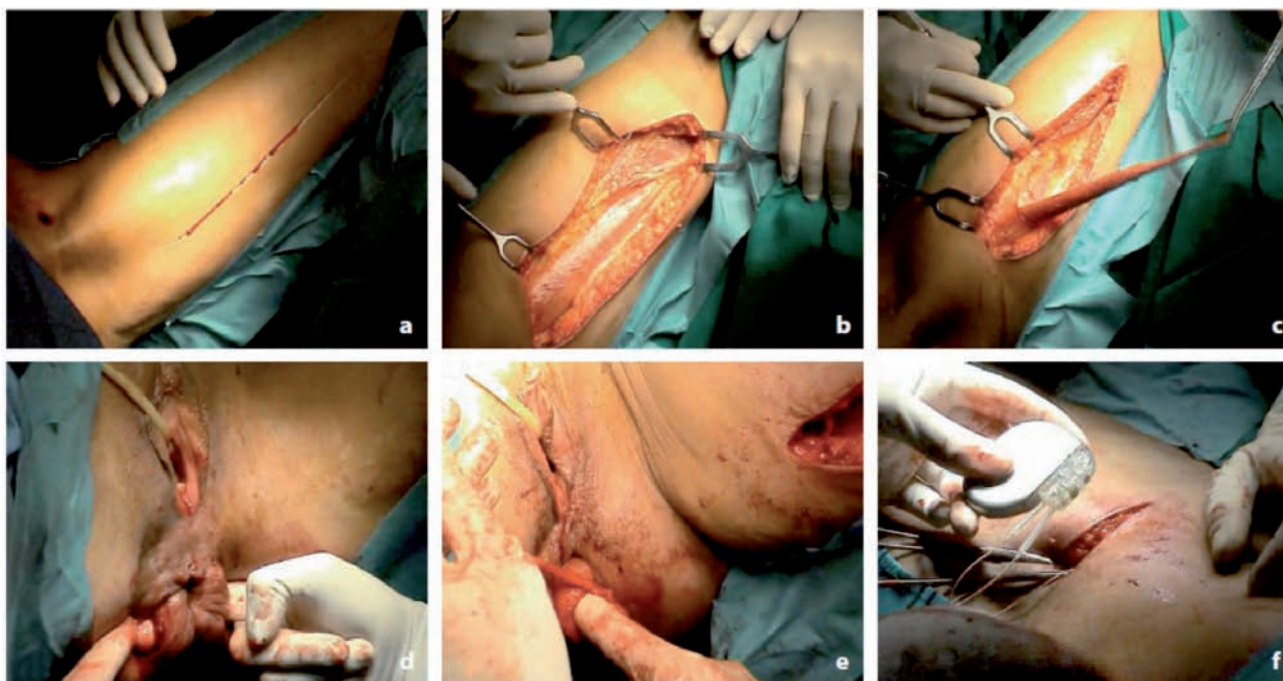


Figure 2 a-f — Performing dynamic graciloplasty.

tients are not specific and must be completed with data obtained using other diagnostic techniques, such as MRI, endoanal ultrasound and anal neurophysiologic tests, to obtain a correct pathophysiological profile of incontinence.

In the fifth chapter “Sphincter Repair and Postanal Repair” J. Pfeifer updates information on traditional surgical treatment of fecal incontinence. Sphincter repair can be done either as a direct repair or as an overlapping sphincteroplasty. For idiopathic fecal incontinence, the method of postanal repair has been described. Short-term results (<5 years) for overlapping sphincter repair are successful in about 75% of patients. In the long run over 10 years, the success rate decreases significantly and ranges from about 20% to 30%. Despite poor long-term results, sphincteroplasty is the best and cheapest surgical treatment option for isolated, preferably anterior sphincter defects. Physiological tests are useful for planning an operation, but they do not necessarily reflect the quality-of-life outcome in these patients. At present, postanal repair is not considered as a first-line treatment in idiopathic fecal incontinence.

The sixth chapter by C. Ratto entitled “Dynamic Graciloplasty” provides information on this surgical technique, which purpose is to substitute sphincters that are affected by a very wide or multiple lesion or severe functional impairments causing fecal incontinence. Dynamic graciloplasty (DG) is based on transposition of the gracilis muscle around the anal canal; moreover, electrical stimulation of the gracilis nerve pedicle is usually added to guarantee the functional “dynamicity” of this correction (Figure 2a-f). The most common clinical indications for DG is fecal incontinence secondary to congenital malformations, multiple sclerosis, or cauda equina neurinoma, and severe lesions of the external anal sphincter. Additionally, DG has been used in total ano-rectal reconstruction following an abdomino-perineal resection. The results of DG have been variable. Continence rates range from 35% to 85%, with the best results being obtained in the centers with higher surgical volume. Mortality rates range from 0% to 13%, and morbidity has occurred in more than 50% of patients. Evaluation of DG outcome in terms of clinical improvement of fecal incontinence is still debatable. The final re-

sults are conditioned by the adverse events related to development of postoperative complications.

The seventh chapter entitled “Radiofrequency Energy and Injectable Biomaterials” written by M. Trompetto and M. Roveroni describes the use of radiofrequency and injections with different types of biomaterials for the treatment of fecal incontinence. Over last 5-10 years these methods have gained attention from coloproctologists because of their safety and feasibility. The initial functional results have been encouraging, although more recently their long-term effectiveness has been questioned. The possibility of performing the treatment as a day case operation is a great advantage both for surgeons and patients. These options can be a good alternative in cases of minor fecal incontinence, when a sphincter defect is minimal or absent, or when previous surgery to treat the functional disorder has failed.

Chapter eighth by G. Romano, F. Bianco and L. Caggiano is devoted to “Artificial Bowel Sphincter”. Authors describe the procedure of the implantation of the artificial bowel sphincter (ABS), which seems to be easy and quick, however related to the high risk of system malfunctioning, infection, and explantation. Also morbidity and the need for revision surgery is high, but the outcome in terms of continence and quality of life is significantly improved, so that ABS may be considered an effective treatment option for severe fecal incontinence. Patients should be well informed and their skill to manage the device evaluated. When all the other treatment options have failed, the ABS procedure should be proposed, particularly in young and motivated patients, as it remains the only alternative to a definitive colostomy.

The ninth chapter of the section five by D. F. Altomare, M. Rinaldi and F. Cuccia entitled “Sacral Neuromodulation” describes the method of sacral nerve stimulation (SNS), a minimally invasive treatment available for fecal incontinence, involving electrostimulation of the sacral nerves by means of implantable pulse generator. Despite the fact that the exact mechanism of action is still incompletely known, SNS has gained wide acceptance among colorectal surgeons for its ability to influence several factors responsible for continence, and as a reliable pre-im-

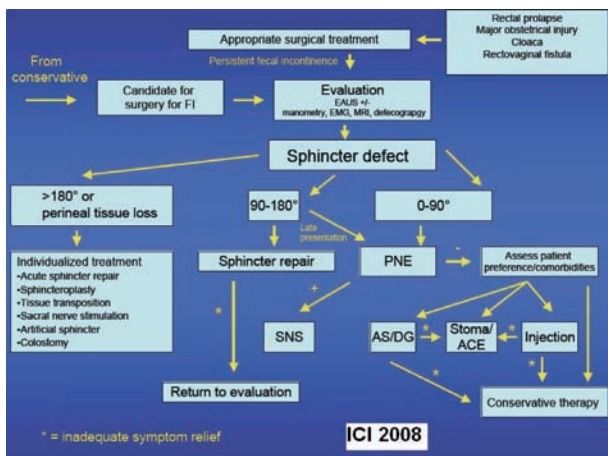


Figure 3. – Algorithm on the management of fecal incontinence by the ICI 2008.

plantation test, with very low surgical risk and a wide range of indications. About 15 years since the introduction of the method in coloproctology, studies on the long-term outcome have confirmed its reliability and effectiveness, not only in symptom control but also in improving quality of life. Evaluation of cost-effectiveness ratio compared with other treatments for fecal incontinence confirms the advantages of SNS, making this technique the first option in the management algorithm of this disease.

Chapter tenth “Future Treatment” by B. Roche, G. Zufferey and J. Robert-Yap describes the future of incontinence treatment, which will be guided by the increasing risk of the ever-aging population. Prevention of risk factors such as more conservative delivery techniques or less aggressive anal surgery will reduce the number of incontinent patients (Figure 3). Concerning therapy, new imaging will be helpful to plan surgical treatment and reduce organ injuries. The area of nerve stimulation will continue to play a large role, and the development of direct pudendal nerve

stimulation has yet to reveal its long-term effectiveness. Finally, the substitution of old and degenerative tissues by new tissue derived from stem cells is a promising way to treat general tissue degeneration.

The chapter eleventh by B. Salvioli and L. Pellegrini describes “Biofeedback”, a conservative treatment that is widely recognized to be, along with lifestyle modifications and pharmaceutical support, one of the first-line approaches in fecal incontinence. Although data in the literature are controversial with regards to its benefit, and studies lack standardized protocols, this technique is relatively easy, readily accepted by patients, has no side-effects, and is of great help for patients’ physical and psychological well-being. Predictors of outcome are not well established. Future placebo-controlled randomized studies are needed to better evaluate the efficacy of the method.

Chapter twelfth written by P. F. Almerigi, V. Ciaroni and G. Bazzocchi entitled “Medical Treatment” encompasses information about conservative treatment of fecal incontinence, which should always be the first approach to the disease. Conservative approach with changing of bowel habits, hygienic measures, dietary modifications, and medical treatment may be considered for minor degrees of fecal incontinence. Other indications for non-operative options are surgical failure and neuropathic incontinence. The best choice of medical treatment can be reached through an accurate integration of clinical features and instrumental diagnostic results. The main goal of conservative treatment should be not the complete resolution of dysfunction but the improvement of symptoms and the quality of life.

Correspondence to:

G. A. SANTORO
 Chirurgia Generale 1
 Ospedale regionale Cà Foncello
 31100 Treviso Italia
 gasantoro@ulss.tv.it