

# Evacuation proctography and magnetic resonance defaecography: a retrospective study

ALI ZAFAR<sup>1</sup>, MARK CHAPMAN<sup>2</sup>

<sup>1</sup> Department of General & Colorectal Surgery, Heart of England NHS Trust, Birmingham, United Kingdom

<sup>2</sup> Department of General & Colorectal Surgery, Heart of England NHS Trust, Birmingham, United Kingdom

**Abstract: Objective:** to compare supine magnetic resonance defaecography (MRD) and evacuation proctography (EP) for evaluation of the posterior pelvic compartment. **Materials and Methods:** Data were collected retrospectively for patients with OD who underwent both MRD and EP between 2008 and 2011. Comparison was made using McNemar test for correlated proportions. Sixteen patients underwent both diagnostic studies. The average patient age was 39 years, and 81% were female. **Results:** Recto-rectal intussusception was apparent in 50% of patients on EP vs. 43% on MRD ( $p = 0.999$ ), and 62% of patients had a rectocele on EP vs. 56% on MRD. During EP, 75% of the patients were able to evacuate more than half of the pre-instilled rectal contrast, compared to only 37% during MRD ( $p = 0.016$ ). The rate of incomplete evacuation was significantly greater during MRD than during EP. **Conclusion:** no significant difference was evidenced in detection of posterior pelvic compartment pathology between EP and MRD.

**Key words:** Dynamic MR; Defecography; Proctography; Rectocele; Intussusception.

## INTRODUCTION

Evacuation proctography (EP) has been used to evaluate patients with pelvic floor dysfunction for more than 50 years. EP is simple to perform and widely available, and it detects structural and functional abnormalities in defaecatory disorders.<sup>1</sup> Magnetic resonance defaecography (MRD), with its intrinsic advantages, has become an attractive option. It does not require the use of ionising radiations, and it provides high-quality multiplanar imaging and simultaneous visualisation of all 3 pelvic compartments.<sup>2</sup> The aim of this study is to compare supine magnetic resonance defaecography and evacuation proctography for the evaluation of the posterior pelvic compartment.

## MATERIALS AND METHODS

Data were collected retrospectively by reviewing clinical letters, anorectal physiology reports, and radiology reports for patients with OD who underwent both MRD and EP between 2008 and 2011. Comparisons were made using McNemar test for correlated proportions. Data were analysed using SPSS version 15.0.

MRD examinations were performed on a 1.5 Tesla closed magnet Siemens Symphony scanner. The patient lies supine on a waterproof mat in the MRI scanner, with knees slightly flexed; legs apart and a pillow underneath. A flexible transmit/receive radiofrequency Siemens 6 channel multiphase coil is wrapped around the pelvis. Patient evacuates pre-instilled rectal contrast (ultrasound gel) on the MR table.

During EP the patients were seated on a commode, feet placed on the footrest of an upright positioned examination table in front of a fluoroscopic unit. Patient evacuates pre-instilled rectal contrast in a sitting position.

## RESULTS

There were 118 MRDs and 102 EPs performed at our institution during the study period. Sixteen patients underwent both diagnostic studies. The average patient age was 39 years, and 81% were female. The median interval between studies was 4.5 months (inter quartile range, 2.25 to 11.25).

Common presenting symptoms were sensation of incomplete evacuation (93%), digitation (43%), faecal incontinence (31%), urgency (18%), and prolapse (18%).

During EP, 75% of the patients were able to evacuate more than half of the pre-instilled rectal contrast, compared to only 37% during MRD ( $p = 0.016$ ).

Recto-rectal intussusception (Figure 1b) was apparent in 50% (8/16) on EP, vs. 43% (7/16) on MRD ( $p = 0.999$ ); 56% (9/16) had a rectocele (Figure 1a) on EP, vs. 62% (10/16) on MRD. About 20% (2/9) of rectoceles showed contrast trapping on EP, compared to 10% (1/10) on MRD.

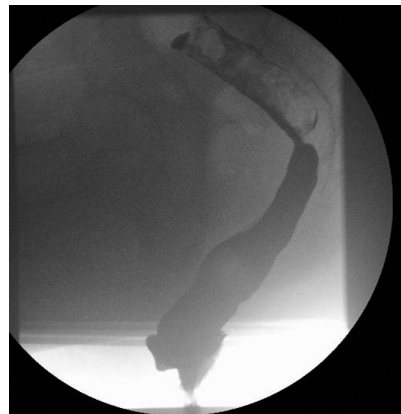

Figure 1A. – Evacuation proctography revealed a small rectocele and mucosal folds.

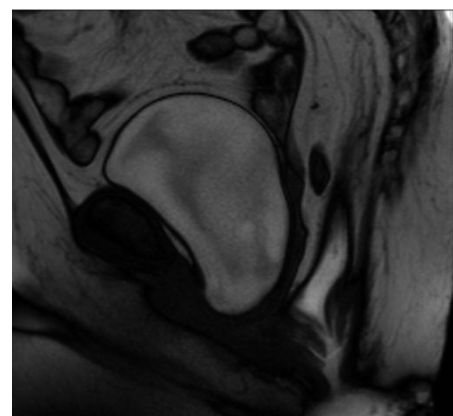


Figure 1B. – Magnetic resonance defaecography for the same patient clearly demonstrates intussusception.

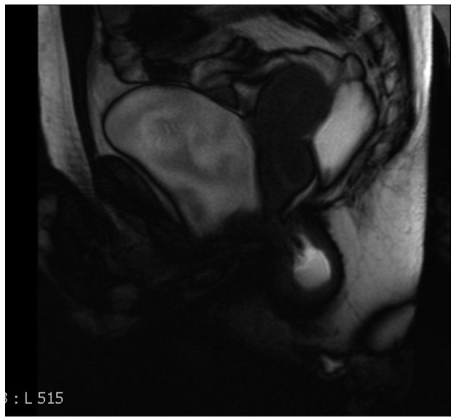


Figure 2A. – Magnetic resonance defaecography shows no evacuation, suggesting anismus.

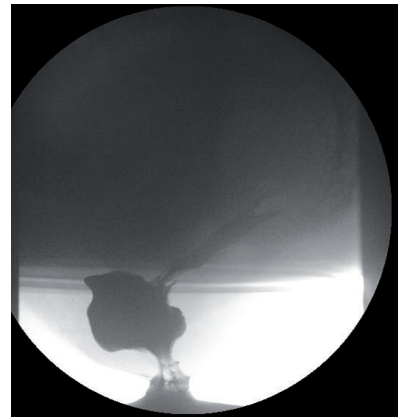


Figure 2B. – Evacuation proctography performed a few months later revealed an intussusception and a rectocele.

Anismus (Figure 2a) was reported in 2 patients on MRD and in none on EP. Both these patients were found to have increased resting pressures and impaired rectal sensitivity. Table 1 compares findings exclusive to MRD and EP.

Furthermore, in 19% of patients, MRD detected pathology in other pelvic compartments that was not apparent on EP and clinical examination.

TABLE 1. – Comparison of pathology detected by magnetic resonance defaecography and evacuation proctography exclusively.

	Magnetic Resonance Defaecography	Evacuation Proctography
Intussusception	2	3
Rectocele (Trapping)	3 (1)	4 (2)
Anismus	2	0

## DISCUSSION

Obstructive defaecation (OD) is a cause of constipation. The pathology underlying OD may be multifactorial and often involves more than 1 pelvic compartment.<sup>3</sup> Assessment of patients presenting with OD includes history, clinical examination, colonic transit studies, anorectal physiology testing, and defaecography.

Traditionally, EP has been used to evaluate morphologic (e.g., rectocele and recto-rectal intussusception) and functional (e.g. anismus) causes of OD. However, in the last 20 years, MRD has been increasingly studied for evaluation of obstructive defaecation. MRD has many advantages: it does not require use of ionising radiation, and it provides high-quality multiplanar imaging enabling simultaneous visualisation of all 3 pelvic compartments.

Earlier comparative studies (1990–1997) reported that EP was clearly superior in detecting pathology contributing to OD<sup>4,5</sup> and showed poor agreement with magnetic resonance imaging (MRI) techniques,<sup>6</sup> suggesting that the erect position used in EP is physiological, and therefore preferable to the supine position used in MRI. These studies did not use rectal contrast in MR imaging; therefore, patients were not imaged during evacuation. Furthermore, a study comparing sitting-up and supine MRD detected similar proportions of cystoceles and rectoceles.<sup>7</sup> Studies comparing magnetic resonance and evacuation colpocystoproctography found that the 2 methods have similar rates of detection of pelvic organ prolapse.<sup>8-10</sup> However, colpocystoproctography is invasive and involves instillation of contrast in the bladder, vagina, and rectum. In our routine clinical practice, we use rectal

contrast with or without oral contrast in EP and only a rectal contrast in MRD.

A common criticism of supine MRD is that patients frequently fail to adequately evacuate in the supine position, making it difficult to diagnose intussusception and to differentiate between trapping and non-trapping rectoceles. In the present study, although significantly lower proportions of patients evacuated >50% of rectal contrast during MRD compared to EP (37% vs. 75%,  $p = 0.016$ ), the prevalence of intussusception and trapping rectoceles were similar between MRD and EP (43% vs. 50%,  $p = 0.999$  and 10% vs. 20%,  $p = 0.999$ , respectively). Furthermore, in 19% of patients, MRD detected abnormalities of other pelvic compartments that were missed on clinical examination and EP. In one study, MRD detected pelvic floor abnormalities that had not been detected by clinical examination alone in up to 34% of patients.<sup>11</sup> However, it remains a challenge to determine the clinical relevance of such additional findings.

Although the rate of evacuation of rectal contrast observed in this study was significantly less in MRD, we did not find any significant difference in the posterior compartment pathology detected by EP and supine MRD. This finding may be due to our small sample size and the retrospective nature of the study. Further prospective studies with adequate power are warranted to compare these 2 diagnostic modalities and to evaluate their effect on patient management.

## REFERENCES

1. Mellgren, A, Bremner S, Johansson C, Dolk A, Udén R, Ahlbäck SO, et al. Defecography. Results of investigations in 2,816 patients. *Dis. Colon Rectum.* 1994; 37: 1133–41.
2. Bolog N, Weishaupt D. Dynamic MR imaging of outlet obstruction. *Rom J Gastroenterol.* 2005; 14: 293-302.
3. Maglente D, Kelvin F, Fitzgerald K, Hale D, Benson J. Association of compartment defects in pelvic floor dysfunction. *Am. J. Roentgenol.* 1999; 172: 439-44.
4. Matsuoka H, Wexner SD, Desai MB, Nakamura T, Noguera JJ, Weiss EG, et al. A comparison between dynamic pelvic magnetic resonance imaging and videoproctography in patients with constipation. *Dis Colon Rectum.* 2001; 44:571-76.
5. Delemarre JBVM, Kruyt RH, Doornbos J, Buyze-Westerweel M, Trimbos JB, Hermans J, et al. Anterior rectocele: Assessment with radiographic defecography, dynamic magnetic resonance imaging, and physical examination. *Dis Colon Rectum.* 1994; 37:249-59.
6. Healy JC, Halligan S, Reznick RH, Watson S, Bartram CI, Phillips R, et al. Dynamic MR imaging compared with evacuation proctography when evaluating anorectal configuration and pelvic floor movement. *AJR Am J Roentgenol.* 1997; 169:775-79.

7. Bertschinger KM, Hetzer FH, Roos JE, Treiber K, Marincek B, Hilfiker PR. Dynamic MR imaging of the pelvic floor performed with patient sitting in an open-magnet unit versus with patient supine in a closed-magnet unit. *Radiology*. 2002; 223:501-8.
8. Lienemann A, Anthuber C, Baron A, Kohz P, Reiser M. Dynamic MR colpocystorectography assessing pelvic-floor descent. *Eur Radiol*. 1997; 7:1309-17.
9. Kelvin FM, Maglinte DD, Hale DS, Benson JT. Female pelvic organ prolapse: a comparison of triphasic dynamic MR imaging and triphasic fluoroscopic cystocolpoproctography. *AJR Am J Roentgenol*. 2000; 174:81-88
10. Pannu HK, Scatarige JC, Eng J. Comparison of supine magnetic resonance imaging with and without rectal contrast to fluoroscopic cystocolpoproctography for the diagnosis of pelvic organ prolapse. *J Comput Assist Tomogr*. 2009; 33:125-130.
11. Elshazly WG, ElNekady AE, Hassan H. Role of dynamic magnetic resonance imaging in management of obstructed defecation case series. *International Journal of Surgery*. 2010; 8:274-82

---

*Correspondence to:*

ALI ZAFAR  
Dept. General & Colorectal Surgery,  
Good Hope hospital, Heart of England NHS Trust.  
Address: Rectory Road, Sutton Coldfield, B757RR.  
Birmingham, United Kingdom  
e-mail: ali.zafar@nhs.net