

As announced in the Editorial by Bruce Farnsworth (*Pelviperrineology* 2011; 30:5) this is the eight of a series of articles highlighting the different sections of the book "Pelvic Floor Disorders, Imaging and a Multidisciplinary Approach to Management" edited by G.A. Santoro, P. Wiczorek, C. Bartram, Springer Ed., 2010.

Fistula

GIULIO A. SANTORO¹, ANDRZEJ P. WIECZOREK², MAGDALENA M. WOŹNIAK²,
ALEKSANDRA STANKIEWICZ²

¹ Pelvic Floor Unit, 1^o Department of Surgery, Regional Hospital, Treviso, Italy

² Department of Pediatric Radiology, University of Lublin, Poland

The eighth section of the book "Pelvic floor disorders - Imaging and Multidisciplinary Approach to Management" is focused on "Fistula".

In the "Introduction", Rechberger presents the causative factors, diagnosis, the classification systems of fistula and their treatment. The prevalence of fistula differs worldwide - in undeveloped countries fistula is mostly the results of poor obstetric care, while in developed countries the leading cause of a urogenital fistula (UGF) is a history of pelvic surgery (including cesarean section) or radiotherapy due to pelvic malignancy. Various classification systems were proposed and nearly all of them were based on descriptions of two factors, namely the size and anatomic location of the defect. However, the most precise classification system for vesicovaginal and rectovaginal fistulae was introduced into clinical practice by Goh in 2004. In this system fistula location, the size of the fistula, and also local factors that could compromise clinical outcome are taken into consideration.

In the first chapter "Urogenital fistulae", D. Pushkar, G. Kasyan and N. Sumerova describe causative factors of the Vesicovaginal fistula (VVF) and urethrovaginal fistulas, their diagnosis and management. Vascular damage of bladder tissue caused by radiotherapy leads to atrophy or necrosis of the bladder epithelium, which causes ulceration, or the formation of fissures. The majority of fistulae become apparent 1.5–2 years after termination of radiotherapy, however, some may appear many years after treatment. The majority of urethrovaginal fistulae in adults are a result of iatrogenic injuries. Various techniques of surgical repair of UGF, including flap techniques are precisely described. The principles of VVF surgical repair might be summarized in three points: (1) excision of all scar tissues; (2) splitting of the vaginal and bladder layers; and (3) closure of the fistula without overlapping of the suture lines. Direct primary anatomical repair may be advised for the patient with urethrovaginal fistula with minimal anatomical disruption.

The second chapter is entitled "Rectovaginal fistulae". A.M. Abulafi and A.H. Sultan present the definition of rectovaginal fistula (RVF), which is an abnormal communication between the rectum and vagina, its diagnosis and management. RVF is a very rare condition, accounting less than 5% of ano-rectal fistulae. The most common cause of RVF is obstetric trauma, which represents between 50% and 90% of RVF presenting clinically, and occurs in 0.1% of all vaginal deliveries. Other causes are: Crohn's disease, trauma to the rectum, perineum, or vagina and tumors infiltrating and eroding the nearby organs leading to the fistula formation. RVF could be classified as: anovaginal and rectovaginal, that is divided into two types, a low (located between the lower third of the rectum and the lower half of the vagina) and a high fistula (between the middle or upper

third of the rectum and the posterior vaginal fornix. Another RVF classification is based on their cause and it is as follows:

- type I - RVF with or without anal sphincter disruption
- type II - RVF due to inflammatory bowel disease
- type III - RVF due to radiation injury
- type IV - RVF due to postoperative injury.

Clinical assessment starts by taking a careful history, noting the severity of symptoms, previous operations on the ano-rectum and vagina, mode of vaginal delivery, the degree of continence to both urine and stools, and taking account of any associated co-morbidities that could influence management. Clinical examination includes careful inspection of the perineum and perianal area. The anus should be examined to determine the status of anal sphincter function by checking the resting and squeeze pressures. The authors strongly advocate the routine use of endoanal ultrasound (EAUS) in order to delineate the fistula and to identify any associated anal sphincter defects that would influence management. The authors describe precisely the methods of treatments of RVF. Conservative treatment is initially recommended if there are significant associated co-morbidities. Moreover, the authors describe in details the surgical operations, which are grouped into three main categories, depending on the approach: local (rectal route, vaginal route and perineal route), abdominal approach and tissue interposition. The choice of treatment depends largely on the experience of the surgeon and, the etiology and location of the fistula, and status of the anal sphincter and ano-rectum.

In the third chapter of this section entitled "Anorectal fistulae", G.A. Santoro et al. describe the management of anorectal abscesses and fistulae. Their pathogenesis is attributed to an infection of the anal glands, usually located in the subepithelial position, the intersphincteric space, or the external sphincter, with ducts that enter at the base of the anal crypts of Morgagni at the dentate line level. Five presentations of anorectal abscess have been described: perianal, submucosal, intersphincteric, ischioanal, and supralelevator abscess and the main tracts of the fistula in relation to the sphincters, which are divided into: intersphincteric, trans-sphincteric, suprasphincteric, and extrasphincteric tract. Preoperative identification of all loculate purulent areas and definition of the anatomy of the primary fistulous tract, secondary extensions, and internal opening plays an important role in adequately planning the operative approach in order to ensure complete drainage of abscesses, to prevent early recurrence after surgical treatment, and to minimize iatrogenic damage of sphincters and the risk of minor or major degrees of incontinence.

Useful information can be obtained by clinical assessment including digital examination. Fistulography has a

very limited role in the assessment of cryptogenic anorectal sepsis and it is little used in clinical practice, however it can be helpful in a chronic fistula with an external opening distant from the anus offering only indirect and not very reliable information on the involvement of anal sphincters. EAUS has been demonstrated to be a very helpful diagnostic tool in accurately assessing all fistula or abscess characteristics. It can be easily repeated while following patients with perianal sepsis to choose the optimal timing and modality of surgical treatment, to evaluate the integrity of or damage to sphincters after operation, and to identify recurrence of fistula. It also gives information about the state of the anal sphincters, which is valuable in performing successful fistula surgery. The authors report that EAUS after injecting 3% hydrogen peroxide (HPUS) through the external opening of the fistula appears to be particularly useful in diagnosing the extrasphincteric fistulae. This technique allows identification of tracts whose presence has not been definitively established, or distinction of an active fistulous tract from postsurgical or post-trauma scar tissue. Moreover, the application of MRI in the assessment of recurrent sepsis not visualized on EAUS is described. The authors suggest that the most appropriate management of anorectal sepsis is to eradicate the tract and drain the sepsis. However, success is influenced by the etiology of the fistula, the course of the tract, and the initial sphincter status.

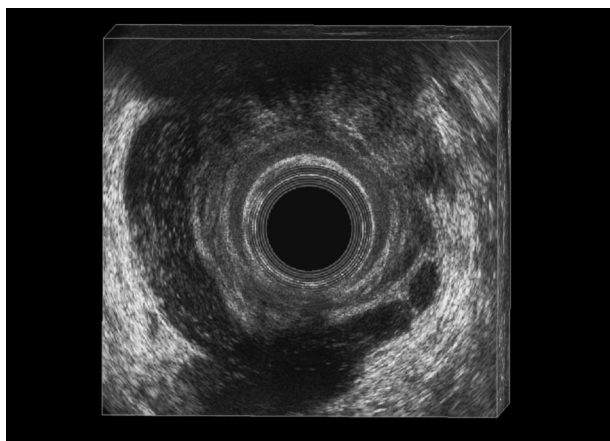


Figure 1. – Endoanal ultrasound. Horseshoe supralelevator abscess.

Multiple surgical techniques, which are currently in use, including fistulotomy and fistulectomy, various types of flaps, instillation of fibrin sealant or stem cells, and plug positioning are described in details.

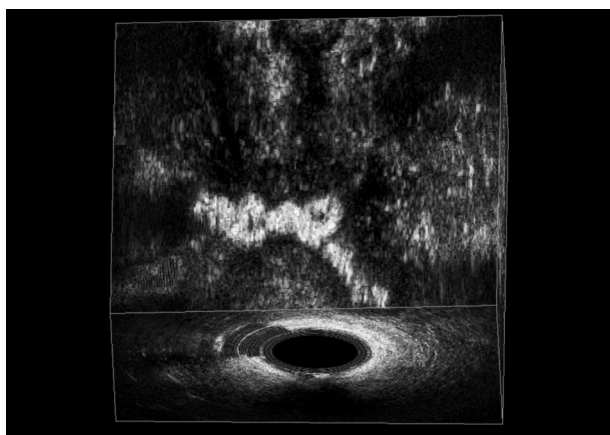


Figure 2. – Endoanal ultrasound. Transsphincteric fistula after peroxide injection.

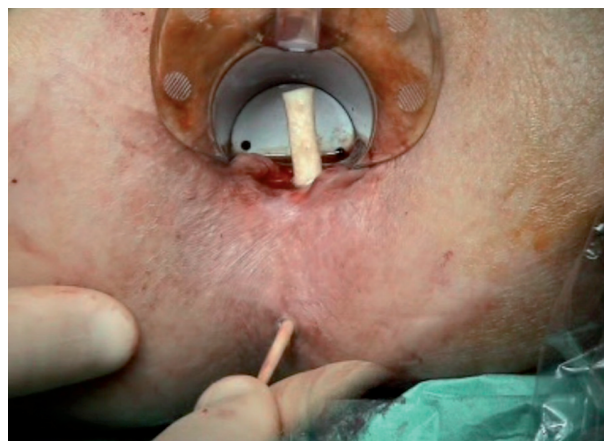

Figure 3. – Fistula plug.

In his commentary, M. Cervigni highlights the importance of the correct timing of a repair and that the decision is simplified by determining of the overall nutritional health of the patient, and the health of the local tissue. A knowledgeable, rational, and current diagnostic approach combined with meticulous surgical technique, could minimize failure and provide relief for the disabling symptoms of these complex patients.

In their commentary, T. Nguyen and F. Frizelle remind that preliminary examination and investigation of the patient with a UGF is important and suggests four essential aspects, which need to be considered when approaching treatment of a UGF: timing of the operation; use of oestrogens/antibiotics; type of operative approach; use of free or pedicled flaps. The authors highlight that in order to optimize the outcome of the RVF repair, there is a need for a multidisciplinary approach by a colorectal and gynecological team. EAUS or MRI and anal manometry are helpful in the workup of the patients with fistula, to quantify the strength of the anal musculature and to document sphincter defects that may require repair. Moreover, these authors present a newly introduced procedure to treat perianal fistulae- the anal ligation of the intersphincteric fistula tract (LIFT), which has impressive and promising results coming out of a handful of institutions. The LIFT procedure involves dissection in the anal intersphincteric plane via the perineal approach to skeletonize the fistulous tract. The tract at this level is then suture ligated. The intervening tract between the ties is eventually excised and the wound closed.

Correspondence to:

G. A. SANTORO
Chirurgia Generale 1
Ospedale regionale Cà Foncello
31100 Treviso Italia
gasantoro@ulss.tv.it