

Tissue Fixation System (TFS) neoligament pelvic organ repair procedures - 12 and 24 month results

MAX HAVERFIELD

Northern Hospital Melbourne, Australia

Abstract. Objectives: To assess the safety and efficacy of the TFS in patients with prolapse and incontinence, with or without uterine preservation and including the learning curve. **Methods:** The Tissue Fixation System (TFS) is an adjustable minisling which uses small lengths of tape to reinforce loose and damaged ligaments and fascial tissue. This is a twenty four month prospective study in a large outer metropolitan Melbourne hospital. Forty women, mean age 60 (50 - 80) years had site-specific TFS repair for grade II to IV urogenital prolapse. Assessment: pre-operative P.O.P.Q, Urodynamics, QOL Questionnaire. Patients with bowel dysfunction had Wexner Score assessment and defecating proctogram. Patients who were sexually active had PISQ-12 assessment. **Results:** The mean surgical time for placement of each device was 12.3 minutes. Improvement rates at 24 months expressed as %, with 12 months in brackets. Prolapse 80% (90%), USI 90% (85%), dragging lower abdominal pain 90% (90%), anal incontinence 70% (70%), nocturia 50% (50%), overactive bladder symptom 50% (50%). There was an average >80% cure rate of urogynaecological prolapse and stress urinary incontinence. There were no tape erosions, anchor slippage or anchor migrations. **Conclusions:** Contrary to the FDA warning on serious complications with transvaginal mesh¹⁵ we found TFS neoligament surgery to be safe and minimally invasive, restoring anatomy and function. The unique design which includes a precise one way tensioning system and use of very small amounts of tape is site specific and effective for all pelvic floor reconstruction. Further evaluation is ongoing.

Keywords: Pelvic organ prolapse; Stress urinary incontinence; Adjustable minisling; Tissue Fixation System.

Abbreviations: QOL quality of life questionnaires; AFTP arcus tendineus fascia pelvis; CL cardinal ligament; USL uterosacral ligament; SUI stress urinary incontinence; POP pelvic organ prolapse; DTP deep transverse perineal muscle; TFS tissue fixation system.

INTRODUCTION

Anatomical disruptions leading to pathophysiological symptoms of pelvic floor disorders are frequently seen in women. Pelvic Organ Prolapse (POP) encompasses many sub groups, such as anterior compartment prolapse of bladder and urethra, central compartment (uterocervical / apical), central apical descent post hysterectomy, posterior compartment (apical, central and hiatal) and others. POP occurs in up to 50% of parous women.¹ Up to 30% of all females suffer from pelvic floor disruption and dysfunction to a degree that has a negative impact upon their quality of life. The lifetime risk of undergoing prolapse surgery is 1 in 11, moreover up to 30% of those who do undergo native tissue repair surgery will eventually have repeat prolapse surgery. Statistically hysterectomised women presenting with increased POP with the ageing of the population.²⁻⁴ POP symptoms are often described in terms of voiding dysfunction eg urinary urge and urge incontinence, frequency of micturition (Pollakiuria), nocturia enuresis and hesitancy (abnormal bladder emptying). Symptoms also include ano rectal dysfunction such as faecal and flatal incontinence, obstructive bowel disease, rectal loading, pelvic pain, "dragging" sensation and sexual dysfunction. Pelvic dysfunction occurs in 10%-30% of women depending on demographics observed and definitions used. Notoriously the prevalence in women is under reported and undervalued. Sexual dysfunction in women is a very common QOL issue.^{5,6} It has been observed in various studies that the anterior and distal parts of the vagina are the most innervated, therefore play an important role in sexual function.^{6,7}

Pelvic organ support is maintained by a combination of pelvic musculature, neurovascular bundles and connective tissue. The uterosacral and cardinal ligaments comprise significantly of smooth muscle, vascular elements and loosely organized collagen fibres and are responsible for uterine and apical support. This has been described as Level 1 support by Delancey.² Nine main connective tissue structures/ligaments are said to be critical to organ support and function according to Ulmsten, Petros:⁷

Anterior Zone

Pubo-urethral ligament, external urethral ligament, suburethral vaginal hammock (described by RF Zacharin in 1968⁸).

Middle Zone

Arcus tendineus fascia pelvis, pubocervical fascia, cardinal ligament.

Posterior Zone

Uterosacral ligament, perineal body, rectovaginal fascia.

The upper vertical axis contains suspensory fibres which serve to pull the superior aspect of the vagina, the cervix and the lower uterine segment posteriorly toward the sacrum so they are positioned over the levator plate. Disruption of these structures can cause uterovaginal prolapse.⁹

The rectovaginal septum is a separate endopelvic fascial layer between the vagina and rectum. The rectovaginal septum divides the anterior and central compartment of the pelvis containing the bladder, urethra and vagina from the posterior compartment containing the rectum. Inferiorly the rectovaginal septum is attached to the perineal body. Superiorly it blends with the undersurface of the Pouch of Douglas perineum which during foetal life extends to the perineal body. Superiorly it blends with the undersurface of the Pouch of Douglas and uterosacral ligaments.¹⁰

As most of the pelvic muscles directly or indirectly contract against these structures, any laxity and/or damage therein will result in weaker muscle contractile force, and therefore, decreased normal pelvic floor and visceral function.¹

Since pelvic laxity and prolapse and symptoms of excretory and sexual dysfunction are very rarely life threatening, Ostergard¹¹ in an editorial stated that it is not ethical to impose a life threatening operation for a patient with QOL issues. He went on further to suggest that there should be zero tolerance for any such operation which may have sig-

nificant morbidity. A recent editorial by CW Butrick¹² also highlighted patient selection, particularly those patients with pre-existing myofascial pain. Polypropylene synthetic mesh has been used in urogynaecology since the 1960s to treat stress incontinence. However it was not until Ulmsten and Petros developed the TVT sling with its advantage of same day surgery, less post operative pain and morbidity that the mid urethral sling became the most effective stress incontinence operation performed worldwide. The success of the TVT led to the development of a number of similar slings for SUI and mesh kits for prolapse by many commercial companies.¹³ Support of prolapse would be “better served” by using site-specific ligament support within the pelvis. These opinions were reinforced recently by a warning against mesh usage for prolapse surgery by the FDA.¹⁴

Ideally, the goal of pelvic reconstructive surgery is to address each vaginal compartment separately and provide adequate repair to restore the normal anatomy and functionality of the pelvic floor as a whole. The transvaginal use of the uterosacral-cardinal ligament complex is gaining popularity in the surgical treatment of uterovaginal and post hysterectomy/vault/apical prolapse.¹⁵ The procedure should be easily standardized with reproducible outcomes, have significant improvements on QOL issues, low complication rates and a relatively short surgical learning curve with short hospital admission. This would fit Ostergards criteria.¹¹ Hence the search for a universally applied, minimally invasive system using site specific neo ligaments to support the pelvic visceral with minimal mesh has been investigated.¹

In 2005 an innovative minimally invasive universal system - Tissue Fixation System (TFS) was developed, whereby ligamentus and fascial support of all anatomical defects can be addressed and corrected. The tape can be adjusted as required to restore normal pelvic anatomy and function⁷ with uterine preservation (an important advantage) as there is no clear evidence that hysterectomy will improve surgical outcomes.¹⁶ Severe post hysterectomy vaginal vault prolapse can be surgically corrected using the TFS.

The principal aim of this study was to assess the safety and efficacy of the Tissue Fixation System (TFS) as treatment for the repair of pelvic organ prolapse as well as urinary and bowel dysfunction. In addition consideration was given to the preservation of the uterus as only 3 patients had concomitant hysterectomy due to associated pathology.

MATERIALS AND METHODS

This 24 month prospective study was conducted at the Department of Obstetrics and Gynaecology of the Northern Hospital in Melbourne. The operations were performed between December 2009 and July 2010 by the senior surgeon or under his direct supervision. Patient demographic (Table 1) consisted of 40 women who had site specific TFS repair for grade II to IV urogenital prolapse.

All women underwent clinical assessment including pre-operative POPQ, Urodynamics and a QOL questionnaire. Patients with bowel dysfunction had Wexner Score assessment and defecating proctogram. Patients who were sexually active had PISQ-12 assessment.

As our aim was to assess the safety and efficacy of these procedures as a minimally invasive technique of pelvic floor restoration, no patient was excluded from surgery on BMI, medical co-morbidities or previous pelvic floor surgeries. The only exclusion criterion was an adverse medical or anaesthetic assessment.

For these procedures, the Tissue Fixation System applicator (TFS Surgical, Australia) was used to insert an anchor

TABLE 1. – Patient demographic.

Parameter	Values
Age (years, range)	60 (37-86)
Parity (median, range)	3 (2-7)
Weight (kg, range)	77.9 (57-142)
Previous hysterectomy (No., %)	21 (52.5)
Sexually active (No., %)	22 (55)
Chronic illness* (No., %)	28 (70)

* Diabetes, asthma, hypertension, macro/morbid obesity, COAD, GORD, depression & anxiety.

attached to a non-stretch monofilament macroporous polypropylene tape approx. 7mm wide (Figure 1). Each soft tissue anchor has 4 prongs and is designed to withstand the rigours of pelvic floor function. At the base of the anchor is a one way trapdoor which enables precise tape adjustment. The anchors are totally ensheathed by connective tissue by the 2nd week. The system accurately restores the tension of connective pelvic tissues and the weakened ligaments, the latter providing strong insertion points to restore the strength of the muscle forces and therefore, function.¹ This means that the tape can be adjusted to suit individual anatomy.

The 5 major TFS reconstruction procedures: (Figure 2).

One common method; identify the ligament, hydrodissect where required, create a tunnel adjacent or through the ligament, insert applicator, release anchor, repeat on contralateral side. Adjust and trim tape, close prosthesis tunnel with suture, cover tape with fascia then separately vaginal mucosa. NB No vaginal or fascial excision performed on patient cohort.

TFS Mid Urethral sling procedure: support of pubo urethral ligament:

Check urethral length, create full thickness incision from 1cm below urethral meatus to midurethra (approx 2cms length), insert No. 8 Hegar dilator into urethra to prevent over tensioning, adjust TFS tape to touch urethra without compression. A hammock suture (0 vicryl) as a figure of 8 configuration is placed into external urethral ligament to stabilize distal urethra prior to closure of vaginal mucosa.

TFS Cardinal Ligament procedure: to address level I - apical anterior compartment prolapse:

Create transverse incision (4cm) at versical/cervical junction. Hydrodissect to separate vaginal mucosa from bladder, identify CL; dissect bladder from vaginal mucosa, plicate cystocoele if necessary (2-0 PDS); apply TFS anchor at insertion of CL to ATFP sited approximately 2cms superior and 1cm lateral to the ischial spine. Close tunnel and incision in layers.



Figure 1. – TFS anchor A 4 pronged polypropylene anchor approximately 11x4mm with a one-way trapdoor at its base sits on a stainless steel applicator. A 7m mm

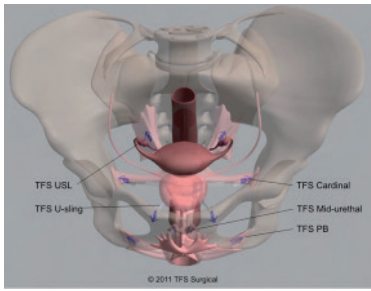


Figure 2. – The TFS re-creates the ligamentous attachments to the pelvic side-wall. USL(uterosacral); cardinal; USling (ATFP); PB (perineal body); mid-urethral (pubourethral).

TFS U Sling procedure - for support of mid/lateral pelvic defects:

Use same incision as for cardinal ligament; dissect toward ATFP at its most medial aspect – 1cm superior to superior notch of obturator foramen. Deploy TFS into position, adjust without tension and close tunnel and incision.

TFS Uterosacral ligament procedure:

Create transverse incision (5-6cm) 1cm above vestibule. With aid of hydro dissection of rectovaginal septum grasp and evert inside of posterior vaginal mucosa with 2 tissue forceps progressively whilst dissecting to posterior apex until USLs are identified. With a finger in rectum palpate lateral border of sacrum at approximately S3 facilitating identification of USL insertion. This also enables the surgeon to protect rectum whilst tunneling and inserting prosthesis.

TFS Deep Transverse Perineii Procedure (perineal body repair):

Using same incision described in USL TFS, the ano rectal junction is separated from perineal body. Under tension, identify DTP with its attachment to lower 1/3 of posterior-medial border of descending pubic ramus. With finger in rectum create a tunnel through DTP to just posterior to ramus in the direction of inferior notch of obturator foramen. Apply TFS prosthesis, tension appropriately, trim tape, close tunnels. Plicate and repair the perineal body if appropriate.

Ethics approval was obtained by the Ethics Committee, The Northern Hospital / Northern Health. Safety of the study was monitored throughout.

Written informed consent was obtained from all patients.

RESULTS

40 women followed up at a minimum of 24 months (Table 2).

70% of cohort suffered from significant medical co-morbidities. 35% had one or more past pelvic organ prolapse procedures.

Perioperative and operative data was predicated on the use of 105 TFS sling applications with the mean of 2.6 slings per patients.

Operative time per sling: 12.5 minutes.

Blood loss average: 50 mls.

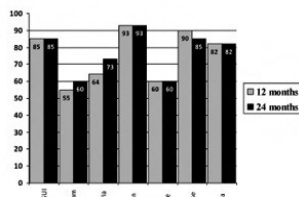


Figure 3. – 12 and 24 month symptom outcomes.

Hospital stay average: 60 hours, and this was dependent on the extent of surgery ranging from 12 hours to 72 hours.

Postoperative interval before return to normal duties ranged from 72 hours to 2 weeks.

Operative data

Symptomatology of the patient cohort was often multiples of voiding dysfunction, symptoms of prolapse and bowel dysfunction as summarized in table 3.

Operative details: Sub-Urethral TFS 9, U-Sling TFS 15, Cardinal Ligament TFS 25, Utero-sacral TFS 34, Deep Transverse Perinei TFS 22, Vaginal Hysterectomy for Non prolapse reason 3, Cervical amputation (Manchester repair) 2.

Patient outcomes

Improvement rates at 24 months expressed figure 3. There was an average >85% cure rate of urogynaecological prolapse and stress urinary incontinence. Of the patients sexually active (50%), one patient had transient dyspareunia. There were no tape erosions, anchor slippage or anchor migrations noted in our cohort.

Recurrent symptomatic prolapse in 3 out of 4 patients was due to cervical hypertrophy >4cms requiring cervical amputation at 18 - 24 months. This has lead to our conclusion that concomitant cervical amputation should be considered if cervical length >4cms.

85% of patients who complained of stress urinary incontinence as a symptom were cured at follow up. Only half of this group had urodynamic demonstrable stress incontinence, the others complained of SUI but this was not demonstrable on urodynamic studies. The first group had a definitive pubourethral TFS tape, the other group only had anterior compartment repair (Cardinal ligaments/U sling) and yet this group post-operatively had a cure in stress incontinence symptoms not demonstrable with urodynamics.

Complications

One rectal mucosal buttonhole injury sustained at initial dissection was treated successfully with primary repair. One rectal serosal penetration with prosthesis was recognized and removed immediately and successfully (Table 4). Both patients had previous multiple perineal and posterior compartment procedures. No implant was inserted under these

TABLE 2. – Clinical details.

Parameter	Values
Anterior compartment prolapse (POPQ ≥2* No., %)	24 (60)
Posterior compartment prolapse (POPQ ≥2* No., %)	24 (60)
Anterior & Posterior compartment prolapse (POPQ ≥2* No., %)	15 (37.5)
Apical prolapse (POPQ ≥2* No., %)	16 (40)
Anterior & Posterior & apical prolapse (POPQ ≥2* No., %)	6 (15)
Previous POP reconstructive surgery (No., %)	14 (35)

Accordance with the ICS POP-Q system.

TABLE 3. – Operative details.

Parameter	Values
Sub-Urethral TFS (No., %)	9 (22.5)
U-Sling (No., %)	15 (37.5)
Cardinal Ligament TFS (No., %)	25 (62.5)
Utero-sacral TFS (No., %)	34 (85)
Deep Transverse Perinei TFS (No., %)	22 (55)
Vaginal Hysterectomy for Non prolapse reason (No., %)	3 (7.5)
Cervical amputation (Manchester repair) (No., %)	2 (5)

TABLE 4. – Symptom analysis.

Parameter	Values
Stress Urinary Incontinence (No., %)	20 (50)
Urgency (No., %)	22 (55)
Urgency incontinence (No., %)	17 (42.5)
Nocturia (No., %)	11 (27.5)
Frequency (No., %)	13 (32.5)
Presence of Dragging Pain (No., %)	15 (37.5)
Constipation (No., %)	6 (15)
Anal Incontinence (No., %)	15 (37.5)
Dysparunia (No., %)	11 (25)

circumstances. Retention of urine (failed trial of void) x 2 patients after the pubourethral neoligament procedure; both cases were transient and resolved. There was one case of midurethral release after 21 days with 100% resolution of voiding dysfunction at 4 months. There was one case of trigger point pain of the inferior margin of pubic ramus which resolved within 21 days. No haemorrhage, haematoma or tape rejections or infections have been noted.

DISCUSSION:

Many techniques have been devised to address the high failure rates of POP repair using native or biological tissue. Repairs such as sacrospinous fixation have been shown to be anatomically incorrect and have postoperatively caused symptoms such as dyspareunia and other complications including haemorrhage, haematoma, small bowel obstruction and mesh erosion.¹⁸ Implantation of mesh sheets for POP seemed promising initially, but complications, sometimes major, have resulted in FDA warnings about the use of large mesh kits within the pelvic floor. These warnings have revived the question “Are large mesh sheets necessary for POP repair?”¹⁵

The surgical reconstruction of the anatomy is almost exclusively focused on the restoration of lax pelvic floor ligaments. Exact preoperative identification of the anatomical lesions is necessary to allow for exact anatomical reconstruction with respect to the muscular forces of the pelvic floor.¹⁷

We have found the TFS procedures to be simpler and more anatomically correct than other procedures. From a structural perspective, the small volume of polypropylene

TABLE 5. – Operative and post operative details.

Parameter	Values
Operative Bladder injury (No., %)	0 (0)
Operative rectal injury (No., %)	2 (5)
Operative bleeding >300ml (No., %)	0 (0)
Operative field infection (No., %)	0 (0)
P/O Haematoma (No., %)	1 (2.5)
P/O Granulation tissue (No., %)	0 (0)
Further mesh segmental resection (No., %)	1 (2.5)
P/O Urinary retention (No., %)	5 (12.5)
P/O overactive bladder symptom at previously 22 OAB patients (No., %)	9 (40.9)
Denovo OAB symptom (No., %)	2 (11.1)
P/O Persistent of Nocturia in 11 patients previously had nocturia (No., %)	3 (27.3)
P/O dragging pain in 15 patients who had dragging pain pre-operatively (No., %)	1 (6.7)
P/O Anal incontinence in 15 patients who had anal incontinence pre-operatively (No., %)	6 (40)
P/O Stress urinary incontinence in 20 patients who had pre-operative SUI (No., %)	3 (15)
P/O Persistence of Prolapse (No., %)	6 (15)

TABLE 6. – Cure rate of symptoms of pelvic organ prolapse treated with TFS sling technology.

Parameter	No. of patients treated	Symptom Cure Rate (No., %)
Stress urinary incontinence	20	17 (85)
Overactive bladder symptom	22	13 (59.1)
Nocturia	11	8 (72.7)
Dragging pain	15	14 (93.3)
Anal incontinence	15	9 (60)
Prolapse	39	33 (84.6)
Dysparunia	11	9 (81.8)

tapes provide excellent support and function for grade IV and the more challenging recurrent POP and visceral incontinence.

In our study 36/40 patients needed multiple anatomical site reconstruction and the with majority requiring apical support. There is evidence that apical repair impacts on anterior vaginal wall prolapse as shown in previous studies comparing sacrospinous ligament fixation and abdominal sacral colpopexy.^{18,19}

The procedure of sacrospinous fixation with unilateral retro version of the fixation of the vaginal apex tends to result in the anterior compartment being subjected to unnatural and non physiological forces which may result in cystocele and enterocele formation with figures ranging from .1-9%.^{20,21}

Our conclusion from our patient cohort is that patients presenting with POPQ (apical) of grade II or more, whether symptomatic or not, had concomitant anterior apical ligament weakness which we supported with an elective TFS cardinal neoligament procedure. Our early assessment is that this reduced de novo anterior wall prolapse to <2% (1 patient). Patients with symptoms of overt SUI in the absence of demonstrable SUI with urodynamics were also cured.

CONCLUSION

We have found the TFS neoligament procedures for restoration of pelvic anatomy and function to be of short duration, minimally invasive, safe and effective with or without uterine preservation. Reproducibility and standardization of the procedure has an acceptable learning curve and safety profile a with a short patient recovery period. Regard should be given to the fact that the results included the patients operated on during the learning curve and there were no exclusions of patients with previous gynaecological, general surgeries or medical co-morbidities and high BMI. We have observed the cohort trend in a further >500 TFS procedures, however longer follow up data and a larger cohort of patients will be important to further ascertain outcomes.

TABLE 7. – Operative and post operative complications.

Parameter	Values
Operative Bladder injury (No., %)	0 (0)
Operative rectal injury (No., %)	2 (5)
Operative bleeding >300ml (No., %)	0 (0)
P/O Haematoma (No., %)	1 (2.5)
P/O Granulation tissue (No., %)	0 (0)
Further mesh segmental resection (No., %)	1 (2.5)
P/O Urinary retention (No., %)	5 (12.5)
Denovo OAB symptom (No., %)	2 (5)
Tape Erosions at 24 months (No., %)	0 (0)
Anchor slippage at 24 months (No., %)	0 (0)
Anchor migration at 24 months (No., %)	0 (0)

ACKNOWLEDGMENTS

The Northern Hospital theatre and nursing staff, continence nurse Andrea McCay.

CONFLICTS

None.

REFERENCES

1. Petros PE The female pelvic floor function, dysfunction and management according to the integral theory Ed 3 Heidelberg & Springer Chapter 4, Surgery pp. 118-218.
2. DeLancey LOL The hidden epidemic of pelvic floor dysfunction: achievable goals for the improved prevention and treatment Am J Obstet Gynaecol 2005; 192: 1448-95.
3. Nygaard I, Barber MD, Burgio KL et al., Prevalence of symptomatic floor disorders in US women. Obstet Gynecol. 2014 Jan; 123 (1): 141-148.
4. Dietz HP The etiology of prolapse. Int Urogynaecol J Pelvic Floor Dysfunction 2008; 19: 1323-9.
5. Pauls RN, Silva WA, Rooney CM et al. Sexual function after vaginal surgery for pelvic organ prolapse and urinary incontinence. Am. J. Obstet. Gynecol. 2007; 197(6), 622-627.
6. Lemack GE, Zimmern PE: Sexual function after vaginal surgery for stress incontinence: results of a mailed questionnaire. Urology. 2000; 56: 223-7.
7. Petros, PE. Surgery. In Petros PE (ed). The female pelvic floor: Function, Dysfunction and Management, According to the Integral Theory, 2nd Edition, Chapter 4. Heidelberg: Springer, 2006: 83-167.
8. Zacharin RF The anatomic supports of the female urethra. Obstet Gynaecol. 1985; 32: 754.
9. DeLancey JOL Anatomic aspects of vaginal eversion after hysterectomy. AMJ Obstet Gynecol 166: 1717, 1992.
10. Uhlenhuth E, Wolfe W, Smith E et al: The rectogenital septum. Surg Gynaecol Obstet 86: 148, 1948.
11. Ostergard DR Editorial The Epochs and Ethics of Incontinence Surgery. Is this direction forward or backward? Int Urogynaecol J. Pelvic Floor Dysfunction 2002; 13: 1-3.
12. Charles W. Butrick Do guns kill people or? The Mesh Dilemma. Int Urogynaecol J 2010; 21: 133-134.
13. Dwyer P Prolapse Surgery and the Mesh Debate 3rd Clinical Epworth Institute of Obstetrics & Gynaecology Symposium September 2012.
14. Dwyer PL Fatton B Bilateral extraperitoneal uterosacral suspension: a new method for apical prolapse repair Int. Urogyn J 2007; 18(1): 109-110.
15. FDA: Public Health Notification - Serious complications associated with transvaginal placement of surgical mesh in repair of pelvic organ prolapse and stress urinary incontinence.
16. Neuman M, Lavy Y. Conservation of the prolapsed uterus is a valid option: Medium term results of a prospective comparative study with the posterior intravaginal slingplasty operation. Int Urogynaecol J Pelvic Floor Dysfunction 2007; 18: 889-893.
17. Wagenlehner FME, Bschiepfer T, Liedl B, Gunneman A, Petros P, Weidner W. Surgical Reconstruction of the Pelvic Floor Descent: Anatomic and Functional Aspects Urol Int 2010; 84: 1-9.
18. Paraiso MF, Ballard LA, Walters MD, Lee JC, Mitchinson AR. Pelvic support defects and visceral and sexual function in women treated with sacrospinous ligament suspension and pelvic reconstruction. AmJ Obstet Gynecol 1996; 175:14234-30.
19. Benson JT, Lucente V, McLennan E. Vaginal versus abdominal reconstructive surgery for the treatment of pelvic floor defects: a prospective randomized study with long term outcome evaluation. AmJ Obstet Gynecol 1996; 175: 1418-21.
20. Nieminen K, Huhtala H, Heinoen PK. Anatomic and functional assessment and risk factors of recurrent prolapse after vaginal sacrospinous fixation. Acta Obste Gynecol Scand 2003; 82: 471-8.
21. Holley RL, Varner RE, Gleason BP, Apffel LA, Scott S. Recurrent pelvic support defects after sacrospinous fixation for vaginal vault prolapse J Am Coll Surg 1995; 180: 444-8.

Correspondence to:

Max Haverfield
Northern Hospital Melbourne Australia
E-mail: Max.Haverfield@nh.org.au