

# PELVIPERINEOLOGY

## A Multidisciplinary Pelvic Floor Journal

### CONTENTS

#### Editorial

- 105 Pelvip erineology: a new life  
GIUSEPPE DODI

#### Review

- 107 Fowler's Syndrome: what it is and what it's not  
MICHAEL SWASH, PETER PETROS
- 115 Provoked vulvodynia: diagnosis of perplexing pain condition  
JACOB BORNSTEIN, PETER PETROS, SANDY BORNSTEIN

#### Original Article

- 123 Minimal invasive and effective therapy of faecal incontinence with a preanal tape  
SIDI MUCTAR, ANDREI I MÜLLER-FUNOGEA, MARTIN KOWALLIK, NICOLAS FISCHER

#### Original Article

- 132 Magnetic resonance imaging of pudendal nerve: technique and results  
VITTORIO PILONI, MATTIA BERGAMASCO, ANDREA CHIAPPERIN, MATTEO MAZZUCCO, TOMMASO FELICI, JESSICA ANDREATINI, NOEMI NUCERA, ELENA FREDDI
- 137 Prevalence of malignant uterine pathology in utero-vaginal prolapse after vaginal hysterectomy  
EDGARDO CASTILLO-PINO, VALENTINA ACEVEDO, NATALIA BENAVIDES, VALERIA ALONSO, WASHINGTON LAURÍA

#### Teaching Module

- 142 Teaching module for three midurethral sling complications  
Knowledge of urethral closure/opening mechanisms and pathogenesis of SUI informs management of "difficult" cases  
Bernhard Liedl, Klaus Goeschen

#### Index

- 147 Author index  
148 Subject index

2020

Volume: 39

Issue: 4

December




Societatea Română de Uroginecologie



# ARAMIS

transanal rectoscopic Assisted Minimally Invasive Surgery

*Multifunctional surgical device dedicated to the transanal minimally invasive surgery of rectal pathologies.*



## EDITORIAL BOARD

Managing Editor GIUSEPPE DODI, Colorectal Surgeon, Italy

### Editors

JACOB BORNSTEIN, Obstetrics and Gynaecologist, Israel - ANDRI NIEUWOUDT, Gynaecologist, Netherlands - PETER PETROS, Gynaecologist, Australia - AKIN SIVASLIOGLU, Urogynaecologist, Turkey - ERAY CALISKAN Urogynaecologist, Turkey  
Senior editor ELVIRA BARBULEA BRATILA, Romania - Editor emeritus BRUCE FARNSWORTH, Australia

### Editorial Board

BURGHARD ABENDSTEIN, Gynaecologist, Austria  
DIANA BADIU, Gynaecologist, Romania  
ANTONELLA BIROLI, Psychiatrist, Italy  
CORNEL PETRE BRATILA, Gynaecologist, Romania  
SHUKING DING, Colorectal Surgeon, P.R. China  
TRAIAN ENACHE, Urogynaecologist, Romania  
ENRICO FINAZZI - AGRÒ, Urologist, Italy  
KLAUS GOESCHEN, Urogynaecologist, Germany  
DARREN M. GOLD, Colorectal Surgeon, Australia  
WOLFRAM JAEGER, Gynaecologist, Germany  
DIRK G. KIEBACK, Gynaecologist, Germany  
FILIPPO LA TORRE, Colorectal Surgeon, Italy  
MICHAEL D. LEVIN, Pediatric radiologist, Israel  
BERNHARD LIEDL, Urologist, Germany  
NAAMA MARCUS BRAUN, Urogynaecologist, Israel  
ANDRI MULLER FUNOGEA, Gynaecologist, Germany  
MENAHEM NEUMAN, Urogynaecologist, Israel  
PAULO PALMA, Urologist, Brazil  
MARC POSSOVER, Gynaecologist, Switzerland

RICHARD REID, Gynaecologist, Australia  
GIULIO SANTORO, Colorectal Surgeon, Italy  
YUKI SEKIGUCHI, Urologist, Japan  
MAURIZIO SERATI, Urogynaecologist, Italy  
DMITRY SHKAPURA Urogynaecologist, Russia  
SALVATORE SIRACUSANO, Urologist, Italy  
MARCO SOLIGO, Gynaecologist, Italy  
JEAN PIERRE SPINOSA, Gynaecologist, Switzerland  
MICHAEL SWASH, Neurologist, UK  
VINCENT TSE, Urologist, Australia  
PETER VON THEOBALD, Gynaecologist, Reunion Island, France  
FLORIAN WAGENLEHNER, Urologist, Germany  
ADI Y. WEINTRAUB, Urogynecologist, Israel  
PAWEL WIECZOREK, Radiologist, Poland  
QINGKAI WU, Urogynaecologist, P.R. China  
ANASTASIYA ZAYTSEVA Urogynaecologist, Russia  
CARL ZIMMERMAN, Gynaecologist, USA

Aesthetic gynecology - RED ALINSOD (USA)  
Andrology - ANDREA GAROLLA (Italy)  
Challenging cases - VITO LEANZA (Italy)  
Chronic pelvic pain - MAREK JANTOS (Australia)  
Imaging - VITTORIO PILONI (Italy)  
Intestinal Rehabilitation and NeuroGastroenterology -  
GABRIELE BAZZOCCHI (Italy)

### Sections

Medical Informatics - MAURIZIO SPELLA (Italy)  
Pelvic floor Rehabilitation - DONATELLA GIRAUDO (Italy),  
GIANFRANCO LAMBERTI (Italy)  
Psychology - ANDREA AMBROSETTI (Italy)  
Sacral Neurostimulation - MARIA ANGELA CERRUTO (Italy)  
Sexology - OSCAR HORKY (Australia)  
Systematic Reviews - STERGIOS K. DOUMOCHTSIS (UK)

Editorial Office: BENITO FERRARO, LUISA MARCATO

e-mail: benito.ferraro@sanita.padova.it - luisa.marcato@sanita.padova.it

Quarterly journal of scientific information registered at the Tribunale di Padova, Italy n. 741 dated 23-10-1982 and 26-05-2004

Editorial Director: Giuseppe Dodi. The journal is property of the International Society for Pelviperineology



#### Publisher Contact

Address: Molla Gürani Mah. Kaçamak Sk.  
No: 21/1 34093 İstanbul, Turkey  
Phone: +90 (212) 621 99 25  
Fax: +90 (212) 621 99 27  
E-mail: info@galenos.com.tr/  
yayin@galenos.com.tr  
Web: www.galenos.com.tr  
Publisher Certificate Number: 14521

Printer: "Centro Copie" Via Cavallotti 383

Chioggia (Ve)

E-mail: centrocopie.rb@libero.it

Printing Date: September 2020

ISSN: 1973-4905 E-ISSN: 1973-4913

International scientific journal published quarterly.

**Official Journal of the:** International Society for Pelviperineology  
(www.pelviperineology.com)

Asociación Latinoamericana de Piso Pelvico

Perhimpunan Disfungsi Dasar Panggul Wanita Indonesia

The Israeli Society of Urogynecology and Pelvic Floor

Romanian Uro-Gyn Society

Pelvic Reconstructive Surgery and Incontinence Association (Turkey)

# pelviprost®

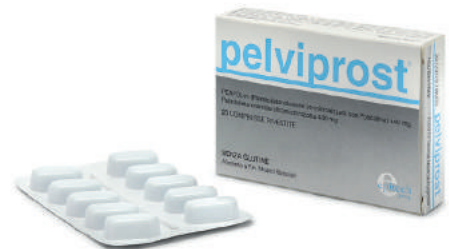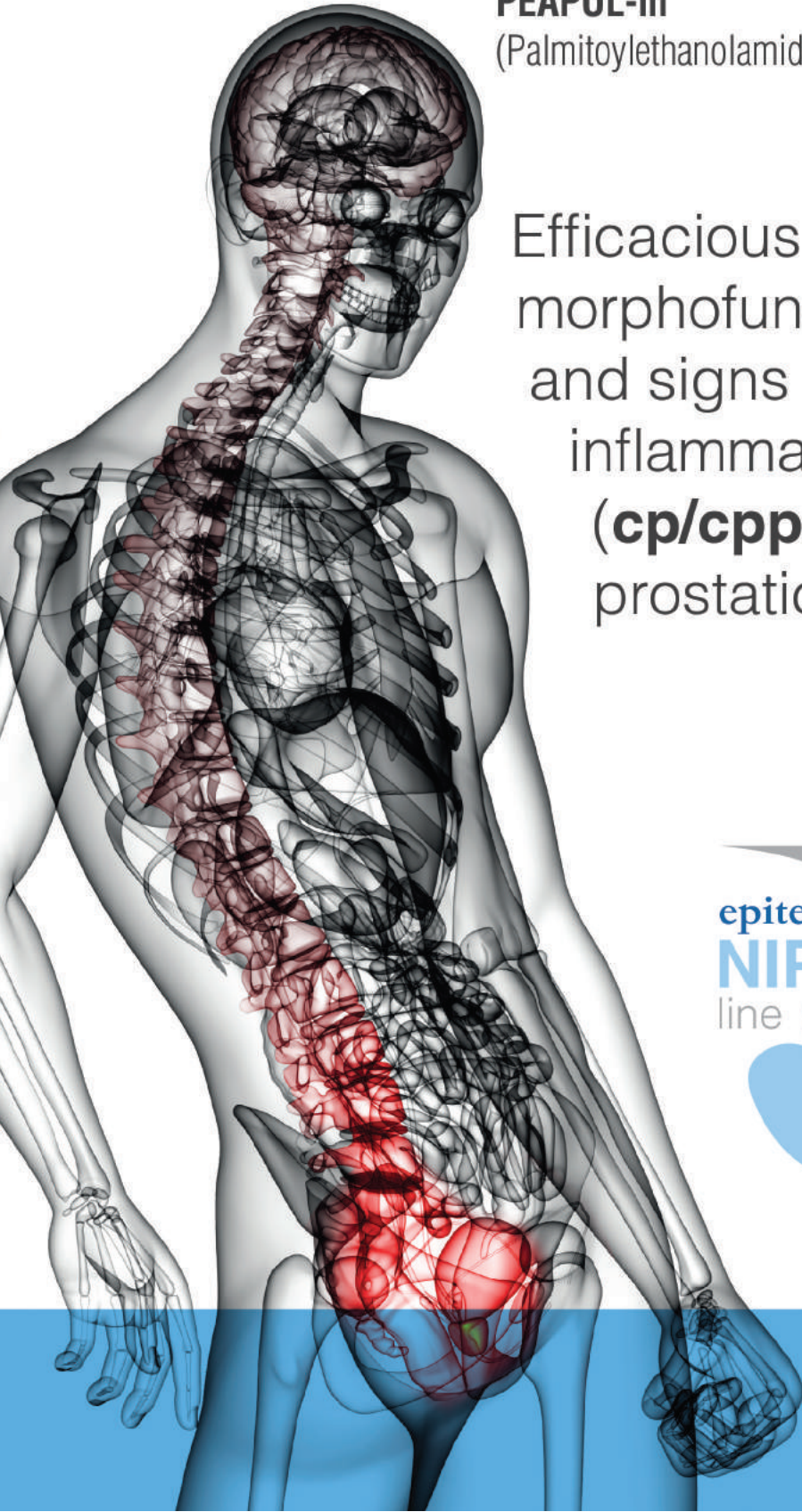
## PEA-um

Ultramicronized Palmitoylethanolamide 400 mg

## PEAPOL-m

(Palmitoylethanolamide co-micronized with Polydatin) 440 mg

Efficacious control of morphofunctional symptoms and signs in case of chronic inflammatory prostatitis (**cp/cpps**) and benign prostatic hyperplasia.



Packaging 20 tablets



[www.epitech.it](http://www.epitech.it)



## Pelviperineology: a new life

Dear Readers of Pelviperineology,

With the first issue of the 2021, Chief Editor of Pelviperineology will be Professor Jacob Bornstein, Chairman of the Department of Obstetrics & Gynecology, Galilee Medical Center - Nahariya, Israel.

Leaving the direction of the journal brings me a mixture of emotions: *sadness* for the abandonment of a creature that I gave birth to about ten years after my graduation, and followed for 39 years, a complete abandonment is not, really, because I commit myself to continue to assist the Chief Editor, *relief* because the work becomes more and more burdensome and the tasks to lead to an inclusion in the most authoritative indexes of the journal is increasingly complex, and finally *confident hope* for the awareness that the person who takes the leadership has the desire, the ability and the authority for a decisive improvement and a radical change in the journal's long history.

As reported in an editorial of 2007, Pelviperineology<sup>1</sup>, albeit at the margins of the great international scientific publishing, has experienced all the phases of evolution or revolution that involved both the scientific press and the medical art of the study of functions and pelvic floor dysfunctions in all three compartments. Personally I started with the colorectal surgery and proctology, but in the 90s I perceived, thanks to contacts with the urologist at the University of Padua Walter Artibani, the need to have an integrated view of the entire pelvic floor.<sup>2,3</sup> In the first decade of the 2000s, the contact with Bruce Farnsworth and Peter Petros opened me to the study and surgical practice of urogynecology, thus getting the feeling of becoming a pioneer surgeon in *complete pelvic floor surgery* after having contributed, in my thirty previous years, to the spread of proctology in Italy thanks to the foresight of the publisher Piccin who produced in

many thousands of copies and in various editions my vast treatise on Coloproctology, and of an Italian company of medical devices that still exports throughout the world disposable instruments that, for the sole interest in research, I designed and helped to produce.

In recent decades, *surgery of the anterior urological compartment* has seen the triumph of the Integral Theory with the treatment of urinary incontinence with the slings proposed by Petros and Ulmsten, while the use of prosthetic materials has made a fundamental contribution to the correction of *genital prolapses*. In the *colo-rectal-anal* practice, the use of staplers has represented, as well as the laparoscopic approach, a revolutionary element in an almost centenary surgery, but in the strictly pelvi-proctological conditions it has raised many quite critical issues, linked above all to the commercial pressure for an expensive surgery, not infrequently abusive, and of questionable impact in a field where the knowledge of physiopathology is still inadequate to understand the clinic. As always in science however everything, as most of the above described proposed solutions, is questioned and the current debate is promising for a definitive progress, mainly for the benefit of patients.

In the *editorial field* with cultural, political, commercial and obviously scientific information, we have witnessed and are witnessing an evolution that seems to upset and often overwhelm bases that may initially appear stable. The epochal changes of the past that we are now aware of, correspond to personal memories made of a mixture of regret, fear and hope, similar to the feelings we experience now with the innovative proposals of the scientific media or of the new therapies.

In the last decade, the journal has had a double circulation, both in print and online on its website [www.pelviperineology](http://www.pelviperineology).

**Address for Correspondence:** Prof. Dr. Giuseppe Dodi, Centro Pelvi, Padova  
**E-mail:** giuseppe.dodi@unipd.it **ORCID ID:** orcid.org/0000-0002-8683-5468

org and [www.pelviperineologia.it](http://www.pelviperineologia.it) for an Italian edition. Today it counts almost exclusively on diffusion on the web. Its large indexation is a must that constitutes the main objective of the new management.

My gratitude is very great to Professor Peter Petros who in recent years has supported the journal with his encouragement, his international relations and his scientific contributions, to Doctor Maurizio Spella who created the editorial platform [www.isubmit.it](http://www.isubmit.it), essential for the global management of the journal, to the Publisher Galenos who accepted a commitment that my strength alone could no longer support and is of help in the international diffusion of Pelviperineology, and lastly, but in this moment of passing the baton certainly more important of all, towards Professor Jacob Bornstein who agreed to be Chief Editor in this challenging adventure.

It is possible that a different name may be given to the journal, emphasizing in its title, for example, the importance and interest in pelvic perineal *pain*, one of the most important topics in pelvic floor medicine. The aging of populations and the quality of life of many elderly people who too often spend many hours of their days in dirty diapers due to *fecal incontinence* and find it difficult to make their voices heard because they are relegated to retirement homes, must represent a *great call* to the study and proposal for solutions that still sink into the mysterious systems of our body. Fecal incontinence for many reasons, some obvious, has not yet received from the scientific community the attention it deserves due to its clinical and social importance. And this should be a commitment and a responsibility for the *pelviperineological science* which in principle must see the person in his entirety, from the brain, to the heart, to the sphincters, and not only the latter. In this sense the collaboration

is needed by the entire *Editorial Board* (in particular I call my colleagues colorectal surgeons and proctologists to action) and by the more active members of the ISPP, to express interest and passion for a project that continues to attract “painful” questions from patients, proposals for resources and curiosity of the most intelligent people. We must not forget that the pelvic floor represents the field of action not only for urologists, gynecologists and colorectal surgeons/proctologists, but also for many other specialists in imaging, psychology, geriatrics, rehabilitation, pharmacology, physiatry, etc. The involvement of everyone is indispensable, as in the clinical practice also for the success of the journal and for the goodness and usefulness of the fruits it can produce.

This issue of Pelviperineology reflects the multidisciplinary nature of the journal. There are innovative articles and didactic contributions in the fields of urology, gynecology, proctological surgery, diagnostic imaging, with the comment of different specialists, and this absolutely represents the mission of the journal.

GIUSEPPE DODI

Managing Editor

[giuseppe.dodi@unipd.it](mailto:giuseppe.dodi@unipd.it)

## REFERENCES

1. Editorial. The history of the journal. Pelviperineology 2007; 26: 2-3.
2. Artibani W, Benvenuti F, Di Benedetto P, Dodi G, Milani R. Staging of female urinary incontinence and pelvic floor disorders. Proposal of IPGH system. Urologica, Neurourol Urodyn Continence 1996; 6:1-5.
3. Farnsworth B, Dodi G. Short-IPGH system for assessment of pelvic floor disease. Pelviperineology 2007; 26:73-7.



# FOWLER'S SYNDROME: WHAT IT IS AND WHAT IT'S NOT

✉ MICHAEL SWASH<sup>1,2,3</sup>, ✉ PETER PETROS<sup>4,5</sup>

<sup>1</sup>Emeritus Professor of Neurology, Barts and the London School of Medicine, QMUL, London, United Kingdom

<sup>2</sup>Hon Consultant Neurologist, Royal London Hospital (Barts Health NHS Trust) and St Mark's Hospital, London, United Kingdom

<sup>3</sup>Professor of Neurology, Instituto de Fisiologia, Instituto de Medicina Molecular João Lobo Antunes, Faculdade de Medicina, Universidade de Lisboa, Lisbon, Portugal

<sup>4</sup>Adjunct Professor School of Mechanical and Chemical Engineering, University of Western Australia, Perth, Australia

<sup>5</sup>Formerly UNSW Professorial Department of Surgery, St Vincent's Hospital Sydney, Sydney, Australia

## ABSTRACT

We review the clinical problem of idiopathic non-obstructive urinary retention and voiding difficulty in young women, thought by Fowler and associates to be due to urinary sphincter spasm. We conclude that this voiding disorder in Fowler's syndrome (FS) is not due to sphincter spasm associated with a so-called characteristic electromyography pattern in the urinary rhabdosphincter, since the latter has been shown to occur in normal young women. We point out that non-obstructive urinary retention and voiding difficulty is also a feature of the posterior fornix syndrome (PFS) and we suggest that these two syndromes are one and the same. In idiopathic non-obstructive urinary retention, as described in PFS and in FS, the voiding disorder is usually associated with laxity of the uterosacral ligament (USL) with resultant loss of balance in the pelvic floor muscular vectors, causing impaired opening of the urethra for voiding. The various associated features of these two syndromes, especially enlarged bladder, urgency and frequency, chronic pelvic pain, and secondary psychological symptoms are all relieved when voiding difficulty is resolved by successful management strategies, including physiotherapy, tape-based reinforcement of the USL, and neuromodulatory management. We suggest that, given its simplicity and long-term effectiveness, surgical reinforcement of the USL, by plication in younger women or tape reinforcement after the menopause, is the optimal first line treatment for posterior fornix syndrome (PFS). Nonetheless, we caution that our conclusions described here do not exclude other, central neurological causations for this voiding disorder in some patients.

**Keywords:** Fowler's syndrome; posterior fornix syndrome; underactive bladder; urinary retention; chronic pelvic pain; OAB; nocturia

## INTRODUCTION

### The clinical problem

In 1988 Fowler et al.<sup>1</sup> suggested that idiopathic non-obstructive urinary retention in young women was a distinct syndrome often associated with certain characteristic features (Table 1). At that time urinary retention in young women was known as an uncommon disorder, described in the early 19<sup>th</sup> century, and

often attributed to psychological causation; i.e., a "functional" syndrome, an unsatisfactory concept that lacked clear definition. Fowler suggested that this voiding disorder was due to failure of relaxation of the urinary sphincter. Of the listed features,<sup>1,2</sup> in addition to retention, only three are positive. The onset has been associated with opiate therapy, with gynaecological or abdominal surgery, and other minor medical procedures and with childbirth. There is frequent psychological co-morbidity. The most striking of the three positive features, that affected women

**Address for Correspondence:** Peter Petros, Adjunct Professor School of Mechanical and Chemical Engineering, University of Western Australia, Perth, Australia **E-mail:** pp@kvinno.com **ORCID ID:** orcid.org/0000-0002-9611-3258

**Received:** 12 August 2020 **Accepted:** 27 October 2020

©Copyright 2020 by the International Society for Pelviperineology / Pelviperineology published by Galenos Publishing House.

often note that withdrawal of their catheter is accompanied by a feeling of something gripping it, has been ascribed to spasm of the urethral rhabdosphincter (RS).<sup>3</sup> This is attributed to the finding of complex repetitive discharges (CRDs) and decelerating burst (DBs) activity in needle electromyographic (EMG) recordings from the external urinary RS.<sup>1,3,4</sup> However, in the initial report only one control subject was studied and in that subject these EMG features were also found.<sup>4</sup> Later, it was recognised that this EMG feature was present in less than 50% of women with non-obstructive urinary retention.<sup>5</sup>

In striated skeletal muscles, EMG activity of this type is almost always abnormal, and found in both neurogenic or myopathic disorders,<sup>6</sup> especially when a muscle fibre is injured during the insertion of the EMG needle. CRDs do not require motor endplate firing or voluntary neural activity but are due to ephaptic excitation occurring between adjacent striated muscle fibres.<sup>7</sup> It has been suggested that CRDs and DBs in the urinary sphincter may be due in some way to hormonally driven cross-talk between smooth muscle and striated muscle fibres in the urinary sphincter complex.<sup>5</sup> Fowler and colleagues assumed that this sphincteric EMG feature was pathological and caused urinary retention by preventing sphincter relaxation.<sup>3</sup> However, the extent of sphincter muscle involvement during the EMG discharge and the force generated by the discharge have never been studied. In addition, several subsequent investigators have found this sphincteric EMG feature in normal women.<sup>5</sup> Tawadros et al.<sup>5</sup> reported it in the luteal phase of the menstrual cycle in 5/15 women and in both follicular and luteal phases in 8/15, but not in the follicular phase alone. It is therefore not an abnormal finding and, therefore, cannot account for difficulty voiding. Indeed, radiologic, urodynamic and mathematical modelling studies have shown that urinary continence is achieved by musculo-elastic forces outside the urethra, rather than by contraction of the urethral sphincter muscle alone.<sup>8</sup> Fowler et al.<sup>1</sup> also suggested that difficulty voiding was associated with polycystic ovary syndrome, found in 14 of 22 affected women. However, subsequently neither polycystic ovary syndrome, nor endometriosis, were confirmed as associated features.<sup>3,9</sup> The atonic enlarged bladder is considered secondary to functional outflow tract obstruction. Although not at first specifically recognised, a variety of neuropsychiatric symptoms are common associated features and there is frequently chronic pelvic pain.<sup>9,10</sup>

In summary, the symptoms and investigative findings in young women presenting with idiopathic non-obstructive urinary retention extend inconstantly across multiple bodily systems, and the suggested principal feature, the EMG finding, occurs in normal women and varies according to the menstrual cycle.<sup>5</sup> A different explanation for non-obstructive urinary retention in

young women must be sought, although it is possible that there is no unitary causation.

### **A different explanation for non-obstructive urinary retention in women**

Lax or weakened uterosacral ligaments (USL) can lead to urinary retention and difficulty in voiding, a disorder termed the posterior fornix syndrome (PFS), first described in 1993.<sup>8,11</sup> PFS, like Fowler's syndrome (FS), presents with idiopathic non-obstructive urinary retention, associated with frequency, urgency, nocturia, pelvic pain and neuropsychiatric symptoms. It can be cured or improved by USL plication in younger women with good collagen<sup>11</sup> or, more effectively, especially in older women, with a specifically located tape insertion procedure which creates new collagen to reinforce the weakened USL's.<sup>12,13</sup> This experience has implications for management of women with this spectrum of voiding disorders, including FS and PFS.<sup>8,14</sup>

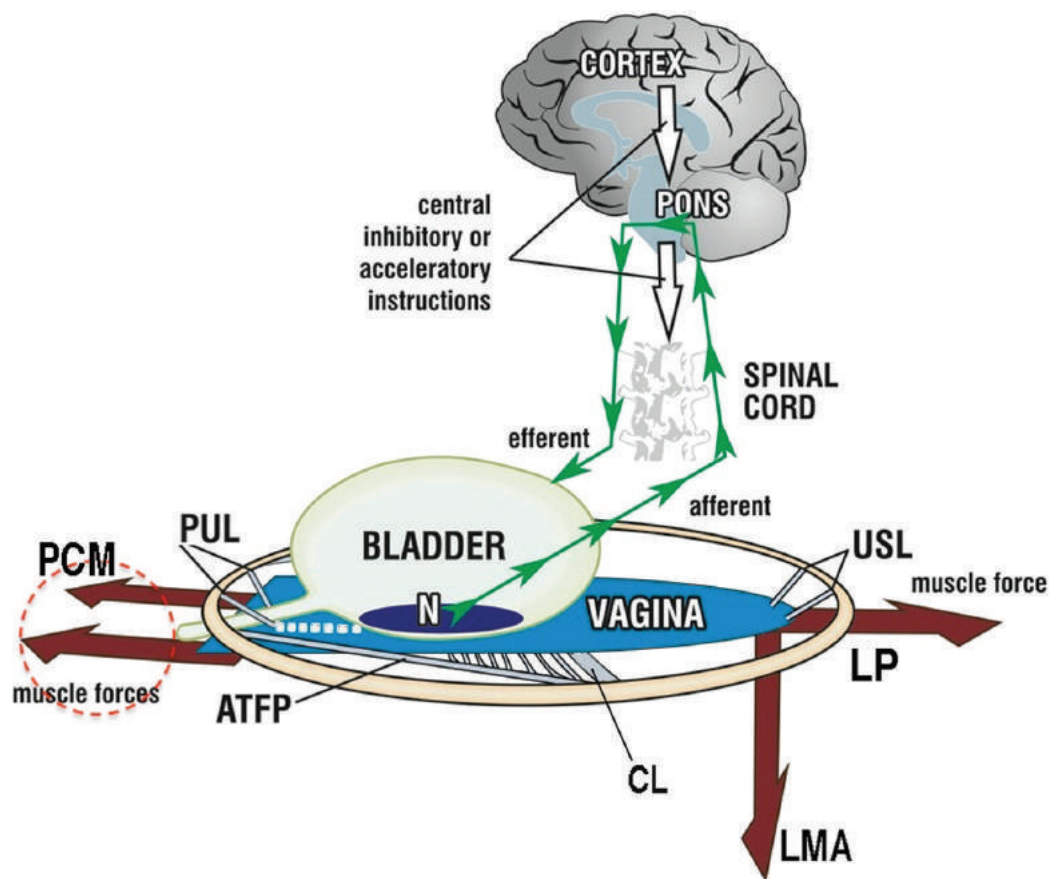
### **Feedback control of bladder storage and voiding**

A feedback control model of urinary storage and voiding is recognised<sup>15</sup> (Figure 1). Urine storage (continence), the resting mode, is modulated by the closure reflex, that is also under conscious influence (Figure 1); white arrows). In the pelvic floor, bladder storage is controlled by the tone of three opposed vectors (Figure 1; large arrows).<sup>16-18</sup> The storage mode is interrupted by voiding, a brainstem reflex response under conscious control that is initiated by perceived bladder filling. This is described as follows:

**Urethral closure:** The pubococcygeus muscle (PCM) contracts forwards against pubourethral ligaments (PULs). levator plate (LP) contracts backwards against PUL and USL. LMA (conjoint longitudinal muscle of the anus) contracts downwards to rotate the bladder and close the proximal urethra by "kinking" at the bladder neck<sup>18</sup> (Figure 1). These actions increase urethral flow resistance, determined by Poiseuille's Law as proportional to the fourth power of the urethral radius.<sup>19-21</sup> At the same time, the urethral RS also contracts, further narrowing the urethral lumen. The closure response also causes all three vectors (arrows in Figure 1) acting oppositely, to tension the vagina, supporting the urothelial stretch receptors ("N" in Figure 1) from below. The resulting tension counteracts the hydrostatic pressure of urine in the bladder, suppressing increased afferent impulses to cortex which would otherwise cause activation of the voiding response.

**Voiding reflex:** Bladder afferents "N" to Barrington's nucleus in the pons (Figure 1) which activates the micturition reflex, subject to cortical modulation (white arrows, Figure 1). The subject feels a sensory urge, and the forward vector due to PCM muscle activity relaxes (broken circle, Figure 1).<sup>16-18</sup> This causes the proximal





**Figure 1.** Feedback control of closure and micturition Schematic 3D sagittal view of bladder and other anatomical structures involved in micturition: 3 opposite vector forces (large arrows) pubococcygeus muscle (PCM) contracts forwards against pubourethral ligaments (PUL); levator plate (LP) contracts backwards against PUL and uterosacral ligaments (USL); conjoint longitudinal muscle of the anus (LMA) contracts downwards against USL; small upwards green arrows = afferent impulses; downward green arrows = efferent impulses; large white arrows = central suppression of both. (broken circle) = relaxation of PCM prior to micturition. If PUL or USL are loose, the muscles contracting against them (arrows) weaken. Urethra cannot be closed (incontinence), opened (emptying problems) or organs stretched to support “N”, (urge incontinence)

CX: Cervix; CL: Cardinal ligament; ATFP: Arcus tendineus fascia pelvis

urethral pressure to fall, and is followed by detrusor contraction, and voiding of urine. PCM relaxation (red broken circle, Figure 1) allows the posterior muscles (large arrows) to funnel out the posterior wall of the urethra (broken white lines, Figure 1) just before the bladder detrusor muscle contracts.<sup>18</sup> This proximal urethral funnelling exponentially reduces internal urethral resistance to flow (Figure 2), so reducing the work required to void by bladder contraction.<sup>18</sup> It also allows urine to enter the proximal urethra, augmenting the urge to void by a sensory reflex loop. The opposing muscle forces must be balanced, or instability is introduced into the system (see Figures 1 and 3).

#### **Video-urodynamics and uterosacral ligamentous laxity:**

Obstruction in the region of the striated sphincter (i.e., distal half of urethra) is a feature of idiopathic non-obstructive urinary retention; for example, in FS and PFS.<sup>3,8,11</sup> In FS this has been ascribed to striated urethral sphincter overactivity but USL laxity<sup>8</sup>, as described above, is a more plausible explanation.

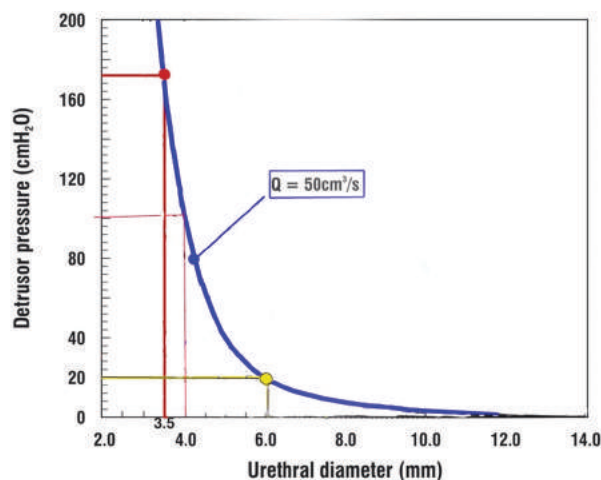
When the USLs are lax (Figure 3), the posterior muscle vectors (arrows) are weak and the resultant altered balance of forces (lower illustration in Figure 3) shifts to the anterior muscle vectors. Increased input from sensory receptors at the bladder neck “N” will then induce activation of the micturition reflex, but compensatory (or socially defensive) activation of the closure reflex maintains continence (white arrows, Figure 1). The already unbalanced forward vector, due to uncompensated activity of the PCM, over-tensions the distal vagina, closing the distal urethra more tightly (Figure 3). This causes a raised maximum urethral pressure, “catheter grabbing”, and consequently an increased post-void urine volume (see Table 1), since a higher hydrostatic pressure is then needed to activate sufficient sensory afferent input to trigger the voiding response. Because the PCM relaxes immediately before micturition starts, excess distal closure tone (Figure 3) now resolves. The posterior vectors (Figure 1; large arrows) remain weak because the USLs, against which they

contract, (Figure 1) are lax. The posterior urethral wall cannot open sufficiently to reduce resistance to voiding (Poiseuille's Law; see Figure 2) before bladder contraction (exactly as shown by video urodynamics<sup>1,3</sup>). The detrusor then contracts against an only partially opened urethra, causing difficulty voiding or "obstructed micturition". The exponential relationship between urethral narrowing and urine flow described by Poiseuille's theorem<sup>18-20</sup> is core in understanding the abnormal urinary storage pattern in FS and PFS and also, probably, with regard to the more recent concept of "underactive bladder" disorder (UAB).<sup>21-23</sup> Similar video-urodynamic features define FS and PFS, further supporting the proposed unity of the two syndromes.

### Urodynamics in idiopathic non-obstructive urinary retention

Urinary volumes in FS may exceed 1,000 ml.<sup>2,3</sup> Upregulated activation of the closure reflex causes increased tone in the forward vector (large arrow, Figure 3) so that afferent impulses cannot trigger the voiding reflex. The same process activates the urethral RS causing a raised maximum urethral pressure. Although only four of our patients with PFS had maximal urethral closure pressures (MUP) >90cm water, the mean MUP in these was reduced from 93 cm to 75 cm water following USL reconstruction.<sup>8</sup> Detrusor contraction was reduced in three women with PFS.<sup>8</sup> These findings are similar to those in FS.<sup>3</sup> In

PFS, following USL reconstruction, the mean resting bladder volumes were reduced from 598 ml to 301 ml and mean emptying time from 50 seconds to 20 seconds<sup>8</sup> (Table 1).

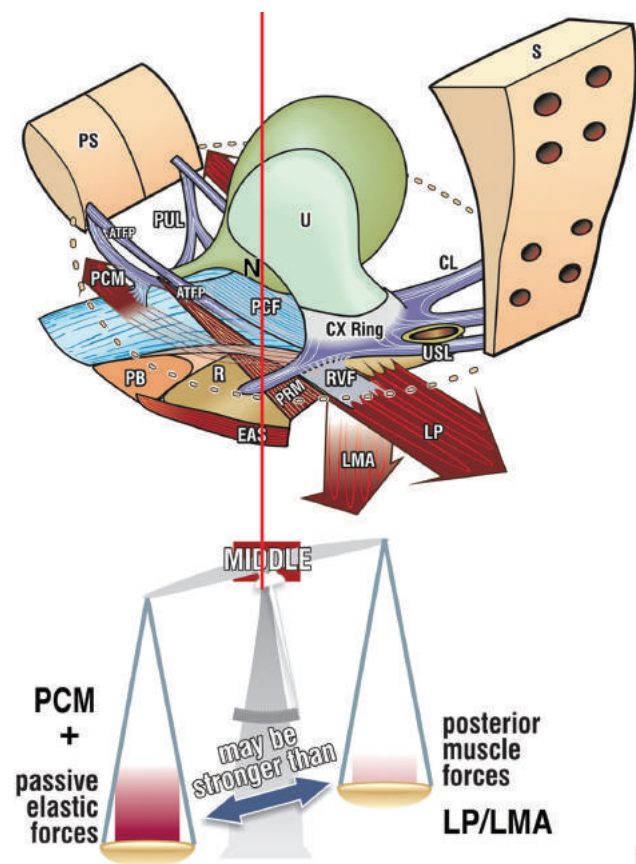


**Figure 2.** Exponential nature of urine flow is related to urethral diameter. For a flow rate of 50 ml/sec (thick blue line), closing the urethral diameter from 4 mm to just 3.5 mm increases the head of pressure required by the detrusor to expel urine from the bladder exponentially, from 100 cm H<sub>2</sub>O to 172 cm. Conversely, expanding urethral diameter to 6 mm (yellow lines), reduces the head of pressure required to evacuate to only 20 cm H<sub>2</sub>O. The blue line represents the total urethral resistance to flow, including dynamic and frictional flow components  
Q: Flow

**Table 1. Pre-operative and post-operative results (after TFS reinforcement of USLs) in 24 women with posterior fornix syndrome**

	Pre-op	Post-op	p value
PVR	272 ml (100-630)	34 ml (0-150)	<0.0001
Abnormal bladder emptying (24 patients)	100%	9 100% cured 9 80% cured 2 50% improved 3 failed	<0.0001
Natural bladder volume	Mean 593 ml	Mean 301 ml	0.0001
Voiding time	Mean 50 sec	Mean 20 sec	0.006
Peak urine flow rate	42 ml/sec	37 ml/sec	NS
Chronic pelvic pain VAS scale assessment	18/24	14 improved 80%	<0.0001
Max urethral closure pressure (4 patients)	>93 cm water	75 cm water	NS
Urge	17/24 3-4 wet episodes/day (range: 1-8/day)	13/17 cured 3 episodes/day (range: 1-8) in 4 patients	<0.0015
Frequency	Mean 12/day (range: 5-21) 14 voided >14 times/day	Mean 8.5/day (range: 5-13) 8 voided >8/day	0.015
Nocturia	2 or more/night in all 24 patients. Mean 4.6 (range: 2-9)	13 cured 10 failures mean 2.7/night (range: 2-6) Host to F/U	<0.0001
Excess detrusor activity	4 patients	1 patient	-

TFS: Tissue fixation system; USL: Uterosacral ligaments; PVR: Post-void residual; VAS: Visual analog scale; NS: Not significant; sec: Second, Pre-op: Preoperative; Post-op: Postoperative, Max: Maximum, F/U: Follow-up



**Figure 3.** The opposing muscle vectors are normally always in balance in the pelvic floor (red vertical line). The posterior vectors require a firm uterosacral ligamentous (USL) insertion point. If USLs are lax, the posterior vectors weaken and the system loses balance, moving forward (to the left of the red vertical line). PCM compensates by contracting forwards.

N: Bladder base stretch receptors; PCM: Pubococcygeus muscle; LP: Levator plate; LMA: Longitudinal muscle of the anus; PUL: Pubourethral ligament (After Petros PE, The Female Pelvic Floor); PS: Pubic symphysis; S: Sacrum, U: Uterus

### Comorbidities in idiopathic non-obstructive urinary retention (FS)

Hoeritzauer et al.<sup>9</sup> studied comorbidities in a chart review of 62 patients with voiding difficulty or retention all of whom had clinical and sphincteric EMG features considered at that time to be diagnostic of FS.<sup>1-3</sup> Of these, 31 (50%) had unexplained chronic pain syndromes. Of the latter, 12 (19%) were taking opiates for unexplained, predominantly abdomino-pelvic, pain syndromes. Fifteen (24%) had other unexplained neurological symptoms, such as non-epileptic attacks and non-organic leg weakness. Abdomino-pelvic surgery seemed to have triggered FS onset in 21 (35%). Ongoing psychological symptoms were recognised in 31%. Only 19 (30%) had no psychological co-morbidity, or pelvic pain. In patients presenting with functional neurological disorders, most of whom are female, lower urinary tract symptoms,

including overactive bladder (OAB) syndrome and low flow rate, are frequent.<sup>9</sup> These complex comorbidities once again raise the unresolved issue as to whether difficulty voiding in young women is an entity due to pelvic floor instability, or whether psychological stress is primarily causative. It seems more likely to us, however, that these non-organic features are secondary to the stress of the dysfunctional bladder symptoms.<sup>9,10,24</sup>

### Chronic pelvic pain

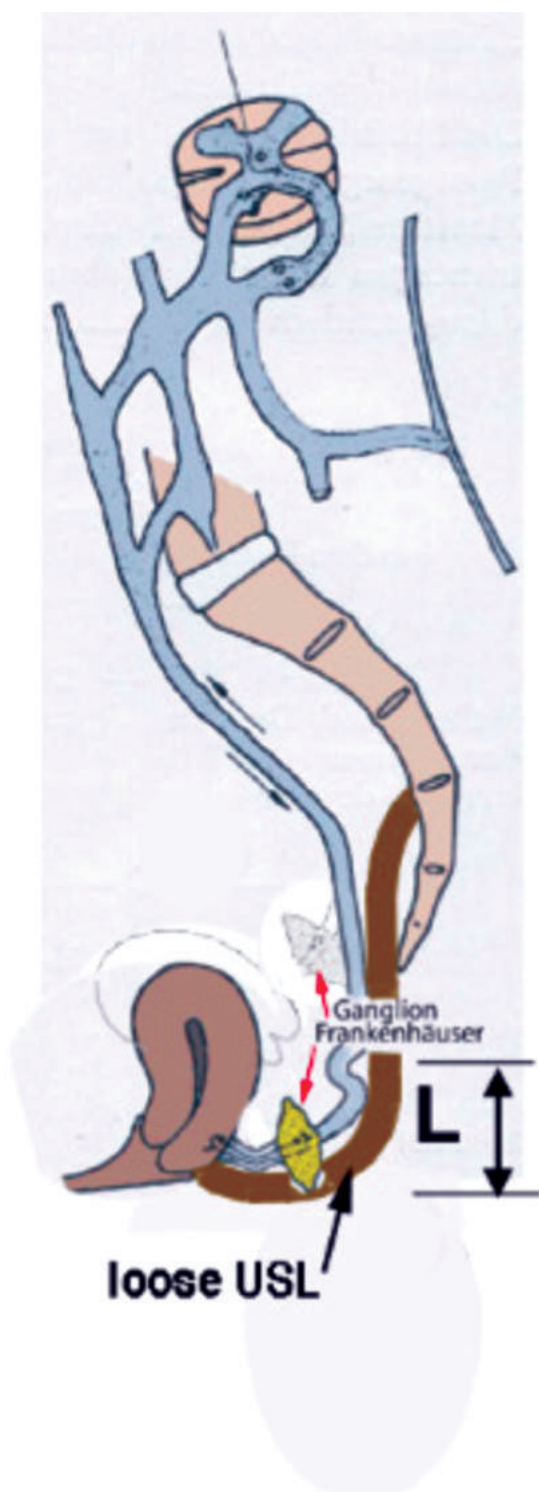Pelvic pain was not part of the original description by Fowler et al.<sup>1</sup> However, Hoeritzauer et al.<sup>9</sup> found that 50% of FS patients at Queen Square had chronic pelvic pain. Idiopathic pelvic pain, sometimes termed “perineal neuralgia”, has long been a difficult clinical problem. Heinrich Martius,<sup>25</sup> writing in the German literature in 1938, suggested that chronic pelvic pain was due to laxity in the USLs causing loss of support to the ganglion of Frankenhauser (T11-L2), located near the cervix,<sup>26</sup> and of the sacral plexus (S2-4) (Figure 4). The anatomy of the ganglion of Frankenhauser<sup>26</sup> and the sacral plexus, important components of the innervation of the uterus and other pelvic organs, was described by Langley and Anderson<sup>27</sup> in 1896. Pelvic pain is common in PFS. In 1996, Petros reported a 70% cure rate of chronic pelvic pain 12 months after USL plication with native tissue USL repair.<sup>28</sup> Since then immediate relief has been reported with a posterior sling procedure that reinforces the USLs.<sup>12,29-31</sup>

### Unifying Posterior Fornix Syndrome and Fowler's syndrome

Abnormal bladder emptying, chronic pelvic pain and high post-void residual urine, symptoms described in FS, whether or not defined by the now redundant EMG finding, are also features consistent with PFS.<sup>11</sup> The characteristic symptoms of PFS are urge, nocturia, abnormal bladder emptying with high post-void residual urine, and a frequent association with chronic pelvic pain. We have previously argued that PFS is indistinguishable from urinary retention in young women, as described in FS.<sup>8</sup> Indeed, the two syndromes are likely one and the same; both are relieved following restoration of pelvic muscle balance by surgical reconstruction of the USLs utilising a posterior sling procedure (Figure 2). In our patients diagnosed with PFS the fundamental diagnostic criteria for FS and PFS were normalized, even curing self-catheterizing retention.<sup>14,18</sup>

### Implications

FS and PFS are two of a group of disorders of urine storage and voiding of uncertain pathogenesis; others include OAB syndrome, UAB syndrome, detrusor underactivity (DU), urgency/incontinence, and urgency/frequency. We consider that FS as



**Figure 4.** Pathogenesis of chronic pelvic pain of unknown origin After Martius<sup>25</sup> The Ganglion of Frankenhäuser and the Sacral Plexus are supported by the uterine insertion of the uterosacral ligaments (USL). When the USLs are lax (L), these sympathetic and parasympathetic nervous structures are vulnerable to stimulation by gravity, prolapse or intercourse causing pain. Applying the bottom blade of a bivalve speculum to stretch the lax USLs usually provides sufficient mechanical support to the USLs to relieve urgency or chronic pelvic pain

currently defined,<sup>3,9</sup> is identical to the previously reported PFS, of organic causation, and usually due to USL laxity. Not surprisingly PFS, like FS, is frequently associated with psychological distress. All the features of PFS are sustainably cured or much improved after simple USL reconstruction,<sup>8</sup> preferably with the relatively non-invasive posterior sling procedure.<sup>8,12</sup> A multicentre trial of various procedures involving 616 patients<sup>24</sup> reported that USL reconstruction greatly improved pelvic pain in 79% of 197 patients. Other PFS symptoms were also improved.<sup>31,32</sup> For example, urge incontinence was improved in 86%, frequency in 84%, nocturia in 69%, and the infrequent associated faecal incontinence in 65%. This marked improvement in comorbidities of chronic pelvic pain after restoration of the uterosacral ligamentous anatomy by USL reconstruction implies that these symptoms are likely to be due to the underlying anatomical disorder.<sup>9</sup> Whether it is helpful to classify FS and PFS in the category of recent descriptions of the bladder/detrusor underactivity (UAB/DU) complex,<sup>22,23</sup> in which OAB is regarded as an essential component of UAB, but presenting with urinary retention, is open to research and discussion.

In PFS/FS, USL laxity is mechanical, as demonstrated by improvement in urinary retention and emptying after surgery, even in women with little or no prolapse.<sup>8,14,15</sup> The mechanical origin of USL laxity can be demonstrated by inserting a cylindrical or rubber ring pessary into the posterior fornix; symptoms of chronic pain, urge, nocturia and emptying will then immediately improve. In young nulliparous women with FS/PFS ligamentous laxity may be congenital although, so far, this has not been studied. If it occurs following pregnancy, the cause is most likely overstretching of component collagen of USL due to relaxin-induced depolymerisation.<sup>33</sup> or, if after delivery, overstretching by the fetal head. After the menopause, it may result from leaching of collagen from pelvic floor ligaments.

### Other methods of management

Non-surgical management by pelvic floor physiotherapy using a squatting protocol<sup>34</sup> has achieved >50% improvement in OAB, nocturia, bladder emptying symptoms and reducing post-void residual bladder volume. However, uncontrolled observations such as these are difficult to interpret. Psychotherapy, similarly, is difficult to assess, but is generally considered unhelpful. Certainly, relief of associated depression and anxiety is an important aspect of overall management of non-obstructive voiding problems.<sup>9,24</sup>

Sacral neuromodulatory therapy has a long history in management of voiding dysfunction.<sup>35</sup> It has been reported effective in urge incontinence (68%), urgency/frequency (56%)

and non-obstructive retention (71%), whether or not defined by the previously accepted EMG feature of FS.<sup>3,36,37</sup> This treatment has also been used in OAB, interstitial cystitis, chronic pelvic pain, fecal incontinence, constipation and neurogenic bladder disorders. Since sacral neuromodulatory therapy appears helpful for such a wide variety of disordered bladder disorders, it has been suggested that it somehow resets brainstem autoregulation of bladder emptying and storage. It is not a specific therapy, but it is clinically indicated when the functional disorder is refractory to other therapies. Its use in non-obstructive urinary retention and other voiding disorders is not informative with regard to pathogenesis, although it does imply a disorder of neural network coordination, whether primary or secondary.

## CONCLUSION

FS/PFS are part of a spectrum of related urinary voiding and retention syndromes. The relationship between USL laxity and cure or improvement of urinary retention by ligament-based surgery, native tissue ligament repair or posterior sling procedures is well established. Physiotherapy and other conservative strategies also have a place. Fowler's reports, 20-30 years ago, were important in stimulating awareness and research into non-obstructive urinary retention in young women. However, it is likely there are both local pelvic floor and central neurological causations.

## Ethics

**Peer-review:** Externally peer-reviewed.

## DISCLOSURES

**Conflict of Interest:** There are no conflicts of interest.

**Financial Disclosure:** The authors of the publication did not receive financial support from any grant/research sponsor or commercial organisation.

## REFERENCES

1. Fowler CJ, Christmas TJ, Chapple CR, Parkhouse HF, Kirby AS, Jacobs HS. Abnormal electromyographic activity of the urethral sphincter, voiding dysfunction, and polycystic ovaries: a new syndrome? *BMJ*. 1988;297:1436-1438.
2. Swinn MJ, Wiseman OJ, Lowe E, Fowler CJ. The cause and natural history of isolated urinary retention in young women. *J Urol* 2002;167:151-156
3. Panicker JN, Pakzad M, Fowler C. Fowler's syndrome: a primary disorder of urethral sphincter relaxation. *The Obstetrician and Gynaecologist* 2018;20:95-100.DOI:10.1111/tog.12448
4. Fowler CJ, Kirby RS, Harrison MJG. Decelerating bursts and complex repetitive discharges in the striated muscle of the urethral sphincter, associated with urinary retention in women. *J Neurol Neurosurg Psychiatry* 1985;48:1004-1009
5. Tawadros C, Burnett G, Derbyshire LF, Tawadros T, Clarke NW, Betts CD. External urinary sphincter electromyography in asymptomatic women and the influence of the menstrual cycle. *BJU Int*. 2015;116:423-431
6. Fellows LK, Foster BJ, Chalk CH. Clinical significance of complex repetitive discharges: a case-control study. *Muscle Nerve* 2003;28:504-507
7. Trontelj J, Stålberg E. Bizarre repetitive discharges recorded with single fibre EMG. *J Neurol Neurosurg Psychiatry* 1983;46:310-316
8. Petros PE, Abendstein B, Swash M. Retention of urine in women is alleviated by uterosacral ligament repair: implications for Fowler's syndrome. *Cent European J Urol*. 2018; 4:436-443
9. Hoeritzauer I, Stone J, Fowler C, Elneil-Coker S, Canon A, Panicker J. Fowler's syndrome of urinary retention: a retrospective study of co-morbidity. *NeuroUrol Urodyn*. 2016; 35: 601-603.
10. Stone J, Hoeritzauer I, Joyce E, Pakzad M, Selai C, Panicker J. Chronic urinary retention; Fowler's syndrome (v1 Aug 2018). pp1-10. www.neurosymbols.org (accessed June 2020)
11. Petros PE, Ulmsten U. The posterior fornix syndrome: a multiple symptom complex of pelvic pain and abnormal urinary symptoms deriving from laxity in the posterior fornix. *Scand J Urol Nephrol*. 1993;27(Suppl 153):89-93.
12. Petros P, Richardson PA. TFS posterior sling improves overactive bladder, pelvic pain and abnormal emptying, even with minor prolapse. A prospective urodynamic study. *Pelviperineology*. 2010;29:52-55.
13. Petros P, Lynch W, Bush M. Surgical repair of uterosacral/cardinal ligaments in the older female using the tissue fixation system improves symptoms of obstructed micturition and residual urine. *Pelviperineology* 2015;34:112-116
14. Petros P, Richardson PA. TFS posterior sling improves overactive bladder, pelvic pain and abnormal emptying, even with minor prolapse. A prospective urodynamic study. *Pelviperineology*. 2010;29:52-55.
15. Petros PE. Detrusor instability and low compliance may represent different levels of disturbance in peripheral feedback control of the micturition reflex. *NeuroUrol and Urod* 1999;18:81-91.
16. Petros PE and Ulmsten U. Role of the pelvic floor in bladder neck opening and closure: I muscle forces. *Int J Urogynecol and Pelvic Floor* 1997;8:74-80.
17. Petros PE and Ulmsten U. Role of the pelvic floor in bladder neck opening and closure: II vagina. *Int J Urogynecol and Pelvic Floor* 1997;8:69-73
18. Swash M, Petros P. The pelvic floor: neurocontrol and functional concepts. In GA Santoro et al (eds). *Pelvic Floor Disorders*. Zurich, Springer Nature AG. 2020 Chapter 4; in press. [https://org/10.1007/978-3-030-40862-6\\_4](https://org/10.1007/978-3-030-40862-6_4)

19. Bush MB, Petros PEP, Barrett- Lennard BR. On the flow through the human urethra. *Biomechanics* 1997;30:967-969.
20. Petros PE and Bush MB. A mathematical model of micturition gives new insights into pressure measurement and function. *Int J Urogynecol* 1998;9:103-107
21. Wagenlehner F, Liedl B, Petros P. A finite element model validates an external mechanism for opening the urethral tube prior to micturition in the female. *World J Urol* 2015;33:1151-1157
22. Osman NI, Esperto F, Chapple CR. Detrusor Underactivity and the Underactive Bladder: A Systematic Review of Preclinical and Clinical Studies. *Eur Urol.* 2018;74:633–43.
23. Uren AD, Cotterill N, Harding C, Hillary C, Chapple C, Klaver M, et al. Qualitative exploration of the patient experience of underactive bladder. *Eur Urol.* 2017;72:402–7.
24. Goeschen K. Role of uterosacral ligaments in the causation and cure of chronic pelvic pain syndrome. *Pelviperineology* 2015;34:2-20
25. Martius H. Über einen häufigen gynäkologischen Symptomkomplex. *Archiv Gynäkol Obstet* 1938;166:332-335.
26. Frankenhausen F. Die Nerven der Gebaermutter und ihre Endigung in de glatter Muskelfasern. Ein Beitrag zur Anatomie und Gynaekologie. Ed Mauke F, Jena. 1967;1-82
27. Langley JN, Anderson HJK. The innervation of the pelvic and adjoining viscera. Part 7: anatomical observations. *J Physiol (Lond)* 1896;20:372-406
28. Petros PE Severe chronic pelvic pain in women may be caused by ligamentous laxity in the posterior fornix of the vagina. *Aust NZ J Obstet Gynaecol* 1996;36:3:351-354.
29. Wagenlehner F, Muller-Funogea I, Perletti GP, Abendstein B, Goeschen K et al Vaginal apical prolapse repair using two different sling techniques improves chronic pelvic pain, urgency and nocturia – a multicentre study of 1420 patients *Pelviperineology* 2016;35:99-104
30. Goeschen K. Posterior Fornix Syndrome: Comparison of original (2004) and modified (2015) post-PIVS anatomic and symptomatic results: a personal journey. *Pelviperineology* 2015;34:85-91.
31. Goeschen K. Role of uterosacral ligaments in the causation and cure of chronic pelvic pain syndrome. *Pelviperineology* 2015;34:2-20
32. Liedl B, Goeschen K, Yassouridis A, Inoue H, Abendstein B et al. Cure of Underactive and Overactive Bladder Symptoms in Women by 1,671 Apical Sling Operations Gives Fresh Insights into Pathogenesis and Need for Definition Change. *Urol Int* 2019;103:228-234
33. Downing SI, Sherwood OD. The physiological role of relaxin in the pregnant rat. IV the influence of relaxin on cervical collagen and glycosaminoglycans. *Endocrinology* 1986;118:471-479
34. Skilling PM, Petros PE Synergistic non-surgical management of pelvic floor dysfunction: second report. *Int J Urogynecol* 2004;15:106-110
35. Steele SS. Commentary. Sacral nerve stimulation: 50 years in the making. *Can Urol Assoc J.* 2012;6:231-232
36. De Ridder D, Ost D, Bruyninckx F. The presence of Fowler's syndrome predicts successful long-term outcome of sacral nerve stimulation in women with urinary retention. *Europ Urol* 2007;51:229-234
37. Van Kerrebroeck PEV, van Voskullen AC, Heesakkers JPFA, Lycklama A, Nyjholt AAB, Siegel S et al. Results of neuromodulation therapy for urinary voiding dysfunction: outcomes of a prospective, worldwide clinical study. *J Urol* 2007;178:2029-2034



# Provoked vulvodynia: diagnosis of perplexing pain condition

JACOB BORNSTEIN<sup>1</sup>, PETER PETROS<sup>2</sup>, SANDY BORNSTEIN<sup>3</sup>

<sup>1</sup>Department of Obstetrics and Gynecology, Galilee Medical Center and Azrieli Faculty of Medicine, Bar-Ilan University, Nahariya, Israel

<sup>2</sup>School of Mechanical and Chemical Engineering, University of Western Australia, Perth, Western Australia

<sup>3</sup>Sackler Faculty of Medicine, Tel-Aviv University, Tel-Aviv, Israel

## ABSTRACT

Provoked vulvodynia typically presents with pain during intercourse. The etiology of this condition has not been elucidated, and the diagnostic procedures are unfamiliar to many health care providers. In a series of papers in *Pelviperineology*, we aimed to present the up-to-date paradigms of this condition. The present paper is the first to present a contemporary approach to the diagnosis of vulvodynia based on medical history, physical examination, and the use of specific instruments and tests, based on a recent consensus terminology of vulvodynia. Management options will be discussed in another issue.

**Keywords:** Provoked vulvodynia; vestibulitis; vestibulodynia; pelvic floor dysfunction; chronic pelvic pain

## INTRODUCTION

Provoked vulvodynia (PV) is a challenging condition for pelvic floor experts.<sup>1</sup> Vulvodynia is currently defined as a vulvar pain of at least three months, without a clear identifiable cause, which may have potential associated factors.<sup>2,3</sup> It was previously termed vestibulitis, vestibulodynia, or burning vulva syndrome. The etiology, pathophysiology, and treatment of this condition have not been elucidated. PV may be one of the various chronic pelvic pain conditions or results from local neuroproliferation.<sup>4</sup> The most common presentation of vulvodynia is PV, with severe entry dyspareunia, sometimes preventing the possibility to have intercourse. Over the years, women have been told that the pain during an attempted intercourse is all “in their head”, which leads to despair and depression.

Given the enigma of vulvodynia, myths about its causes and treatments have emerged. However, in 2015, an evidence-based consensus terminology was introduced by scientific organizations

dealing with vulvar disease - “consensus terminology”,<sup>2,3</sup> providing a clear definition and understanding of vulvar pain. The consensus terminology included a list of eight associated factors, each of which may be the cause of the condition. This paved the way for a change in the paradigm of PV treatment, which should be tailored according to the associated factor detected at diagnosis. The approach to diagnosis has also been amended by the introduction of the consensus terminology.

In previous issues of *Pelviperineology*, we presented the consensus terminology<sup>3</sup>, and the associated vestibular neuroproliferation.<sup>4</sup> The present paper is the first to expound on the contemporary approach to the diagnosis of vulvodynia. Management options will be discussed in another issue.

### How frequent is provoked vulvodynia?

PV is a condition that women frequently conceal because they are ashamed to admit to it; thus, vulvar pain is considered to

**Address for Correspondence:** Jacob Bornstein, Department of Obstetrics and Gynaecology, Galilee Medical Center and Azrieli Faculty of Medicine, Bar-Ilan University, Nahariya, Israel

**E-mail:** mdjacob@gmail.com **ORCID ID:** orcid.org/0000-0003-1932-5270

**Received:** 24 September 2020 **Accepted:** 23 October 2020

be rare. However, the current prevalence of PV is 14% to 34% in young women and 6.5% to 45% in old women.<sup>5,6</sup> In the United States, 30% of women reported pain during vaginal penetration. In the National Health and Social Life Survey, 21%, 13%, 13%, and 8% of women aged 18-19, 30-39, and 40-49, and 50-59 years, respectively, complained of “physical pain during intercourse during the past 12 months”. Another study found that 17% of postmenopausal women suffer from PV. Women of Hispanic origin are more likely to develop vulvar pain symptoms as compared with Caucasian women.<sup>7-12</sup>

**How to evaluate patients with vulvar pain?**

Women with vulvar pain usually go through years of endless visits to health care providers without achieving any significant improvement. This may lead to depression and suspicion in the capability of anybody to cure them. This condition preoccupies their thoughts and negatively affects their whole life. Therefore, the approach should be very empathic. Interestingly, when the diagnosis of PV is made, many patients feel relieved as they finally have a title to their condition. We suggest using a structured questionnaire (Table 1) to obtain the relevant history.

**Essentials of medical history:**

1. Pain descriptors, such as time since onset, temporal pattern, duration, location, quality, cause, intensity, and primary or secondary pain (Table 2).<sup>13</sup>
2. Concomitant pelvic musculoskeletal conditions, such as history of surgery or injury affecting the lumbo-pelvic-hip region and sacrum.
3. Bowel and bladder function history; disturbances may be a clue to pelvic floor dysfunction. The integral theory questionnaire should be used for this evaluation.<sup>14</sup>
4. Sexuality: desire, orgasm, and frequency of sex are a good measure of the severity of the condition.
5. Coexistence of “comorbidities” - other medical or mental health conditions and treatments.
6. Previous treatments of vulvar pain and the outcome.
7. Childhood trauma including abuse and neglect, and any adult negative sexual experience.
8. In a research setting, use of the “Initiative on Methods, Measurement, and Pain Assessment in Clinical Trials (IMMPACT)” series of questionnaires (Table 3).<sup>15</sup>

**Examining the vestibule**

**Cotton-swab test**

The cotton-swab test, also known as the Q-tip test, is an easy-to-use test for diagnosing PV. At this time, a biopsy is not

required to make a diagnosis of vulvodynia. Hence, we rely on clinical diagnosis. The cotton-swab test involves pressing on foci throughout the vestibule with a cotton-tipped applicator.<sup>16</sup> Some recommend that the cotton tip be moist to avoid a painful dry sensation. We pressed vestibular foci in a non-consecutive order in the following seven vestibular foci, according to the clock’s position: 1, 2 (Figure 1), 4, 6, 8 (Figure 2), 10, 11, and 12 o’clock (Figure 3). Foci 1 and 11 are located on both sides of the urethra. In addition to the vestibule, the surrounding tissues in the labia majora, perineum, and clitoris should also be touched with the cotton swab to exclude a generalized condition. The resultant pain is scored with a visual analog scale score by observing

**Table 1. Structured interview of a patient with suspected provoked vulvodynia. “Have you ever had...” (based on reference 1)**

Physical, sexual, and emotional abuse or anxiety?
Low back or hip pain?
Urinary urgency, frequency, hesitancy, or incomplete bladder emptying?
Chronic constipation or rectal fissures?
Oral contraceptive pill use before or during onset of symptoms?
Ovarian suppression by GnRH agonists or Depo-Provera?
Decreased libido or decreased vaginal lubrication prior to the onset of dyspareunia?
Peri-menopausal or menopausal symptoms such as hot flashes and night sweats?
Contact allergies or skin sensitive to chemicals?
Recurrent (culture positive) yeast infections?
Persistent vaginal discharge?
Severe burning or an allergic reaction to a topical medication on the vulva or vagina?
Burning after intercourse?
Pain since first attempt at intercourse without any pain-free sex?
Pain with first tampon use?
Increased sensitivity of the umbilicus?
Postcoital spotting or bleeding?
Vulvar itching, day or night?
Vulvar ulcerations, tears, fissures?
Painful periods?
Chronic pelvic pain?
Pain beginning after childbirth?
Changes in coloration or architecture of the labia or vulva?
Decreased clitoral sensation?
Pain mainly at clitoris?
Has there been any pain-free intercourse?
Oral aphthae or a diagnosis of lichen planus?
GnRH: Gonadotropin-releasing hormone



the patient’s reactions or asking the patient to rate the pain intensity on a numerical rating scale of 0 to 10. However, this test is subjective. It depends not only on the patient’s tenderness but also on the amount of pressure exerted by the examiner.<sup>17</sup> Notably, the openings of Skene’s glands, which are located lateral to the urethra and of the Bartholin’s glands, may be found sensitive even in women without PV.

**Location of the sensitivity, posterior versus anterior vestibular portion:** Early investigators of the condition believed that, in most cases, only the posterior portion of the vestibule is affected.<sup>16</sup> This is not true. With time, most women with sensitivity localized only to the posterior vestibule later develop anterior allodynia. Because of this myth, during many surgical procedures for PV, only the posterior part is excised. The sensitivity later extends to the anterior part, rendering the procedure a failure. This inadequate technique is the cause of the bad reputation of the surgical treatment of PV - vestibulectomy, in the past.

An additional myth is that if the sensitivity is extensive throughout the entire vestibule, it resulted from neuroproliferation and if it is confined to the posterior vestibule, the etiology is musculoskeletal.<sup>18</sup> In our experience, the localization is not associated with etiology.

**Vulva algometer**

A vulvar algometer measures the amount of pressure causing pain applied to the vestibule in the cotton-topped test, allowing standardization of it (Figure 4).<sup>19</sup> The pressed foci may be the same as recommended with the Q tip test.

**Characteristics of the pain**

The possible presentations of pain are few. Allodynia is the perception of pain resulting from a stimulus that is normally not painful, such as a cotton-swab. Hyperalgesia is the perception of extreme pain to a stimulus that is usually causing slight pain, and hyperpathia is pain provoked by very light touch.<sup>20</sup>

**Determining severity**

The patient usually requests to get an opinion on the severity of her PV. However, the severity is determined by the subjective level of pain at vaginal intercourse by using the Marinoff’s criteria:<sup>20</sup>

Level 1: Dyspareunia causes discomfort but does not prevent sexual intercourse.

Level 2: Dyspareunia sometimes prevents sexual intercourse.

**Table 3. Recommended core and secondary outcome measures of provoked vulvodynia for clinical trials, part of the IMMPACT (based on reference 14)**

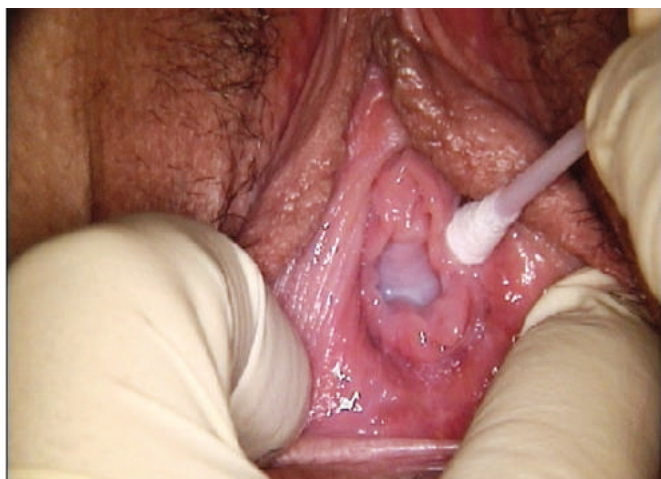Pain characteristic	Core outcome measure	Secondary outcome measure
Pain intensity	11-point NRS during sexual activities	-
Pain quality and effect	Short-form McGill Pain Questionnaire	-
Pain temporality	-	Specific activities that might provoke the pain of PV

IMMPACT: Initiative on Methods, Measurement, and Pain Assessment in Clinical Trials, NRS: Numeric rating scale, PV: Provoked vulvodynia

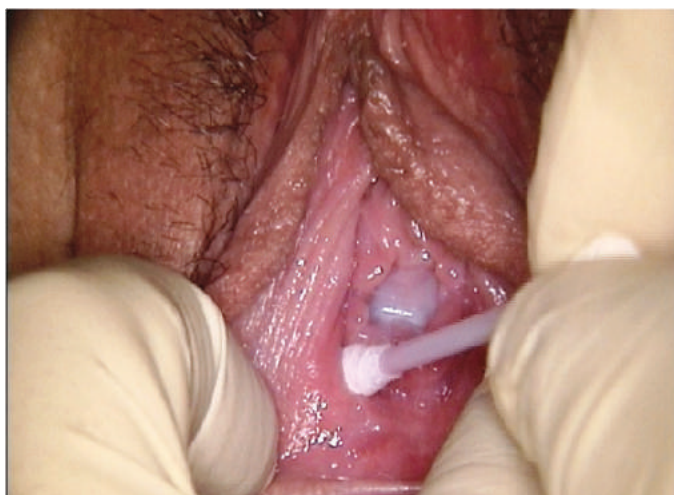**Table 2. Definitions of the descriptors of vulvodynia (based on reference 13)**

Descriptor	Definition	
Location	Localized	Involvement of a portion of the vulva, such as the vestibule (vestibulodynia), clitoris (clitorodynia), etc.
	Generalized	Involvement of the whole vulva.
Provocation	Provoked	The discomfort is provoked by physical contact. Such contact may be sexual, non-sexual or both, i.e., vaginal penetration, clothing pressure, tampon insertion, cotton-tipped applicator pressure, fingertip pressure, etc.
	Spontaneous	The symptoms occur without any provoking physical contact.
Onset	Primary	Onset of the symptoms occurs with first provoking physical contact (i.e., tampon placement, intercourse, vaginal penetration) or the symptoms are present since first recollection.
	Secondary	Onset of the symptoms did not occur with first provoking physical contact or the symptoms have not always been present.
Temporal pattern	Persistent	The condition persists over a period of at least 3 months (symptoms can be constant or intermittent). Synonymous to chronic condition.
	Constant	The symptoms are always present.
	Intermittent	The symptoms are not always present.
	Immediate	The symptoms occur during the provoking physical contact.
	Delayed	The symptoms occur after the provoking physical contact.

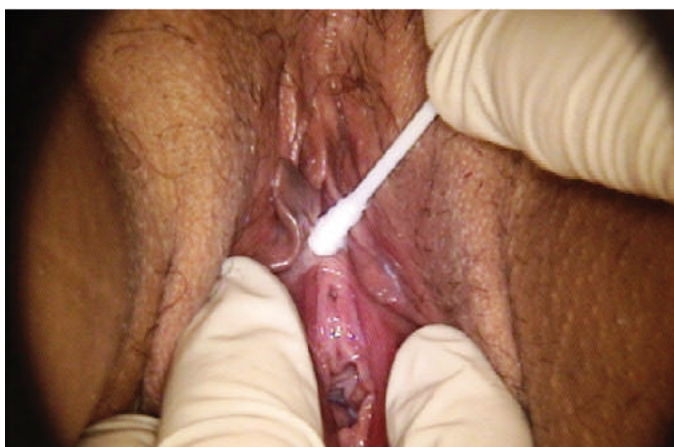Level 3: Dyspareunia completely prevents sexual intercourse. However, when intercourse is not practiced, the tampon test



**Figure 1.** Q-tip swab test, pressing on the 2 o'clock focus in the vestibule



**Figure 2.** Q-tip swab test, pressing on the 8 o'clock focus in the vestibule



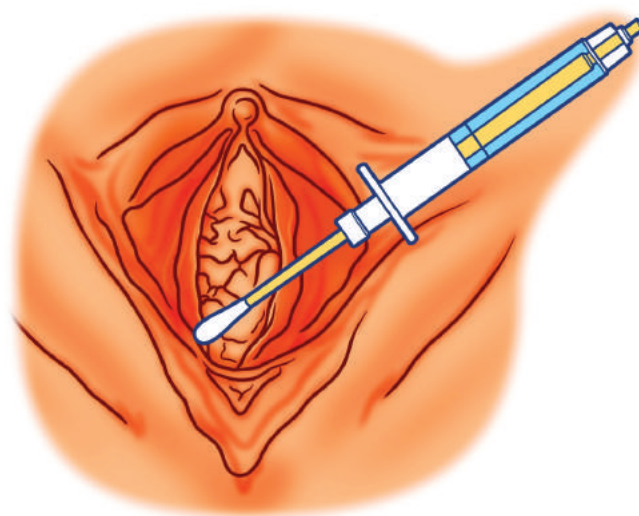
**Figure 3.** Q-tip swab test, pressing on the 12 o'clock focus in the vestibule

may be performed by inserting a tampon to determine the severity of PV.<sup>21</sup>

Although this is a subjective determination, it affects the choice of treatment. In level 1 cases, treatment should not involve surgery. However, the level of pain increases with time, and the PV evaluated as level 1 may become level 2 or 3 in severity. A spontaneous regression of level 3 is rare.<sup>22</sup> Response to treatment is also measured by reduction of dyspareunia level.

**Association with vulvovaginal infection**

Many women with PV have been diagnosed with vulvovaginal candidiasis (VVC). In the past, this co-occurrence originated from the theory that VVC causes PV.<sup>23</sup> Interestingly, in mice, repeated vulvar applications of a yeast allergen (Zymosan) cause a few neuroproliferation and local sensitivity,<sup>24</sup> serving as an animal model for PV. However, prolonged treatment with oral fluconazole has not been shown to cure PV.<sup>25</sup> The frequent association between VVC and PV is a myth. We suspect that the common diagnosis of VVC in women with PV results when health care providers examine a woman with entry dyspareunia and detect a slight vaginal discharge, since they are unfamiliar with the diagnosis of PV. The woman then believes that she suffers from a breakout of VVC every time she experiences pain during intercourse. This leads to repeated cycles of topical therapy with imidazole preparations against VVC, with no real improvement in pain level. Sometimes a woman with PV obviously suffers from VVC. However, VVC is incidental, and PV persists after treatment with imidazole; the woman continues to suffer from dyspareunia. This chain of events (i.e., dyspareunia, “diagnosis” of VVC, treatment with topical azoles, persistent dyspareunia) has even



**Figure 4.** Illustration of a vulvar algesiometer. The cotton-swab applicator is connected to a spring manometer, measuring the pressure applied. The 8 o'clock area is pressed

led to a hypothesis that repeated administration of VVC therapy rather than VVC causes PV via an allergic reaction.<sup>26</sup> Currently, this theory also seems a myth, resulting from VVC overdiagnosis and repeated imidazole treatment rather than PV diagnosis in women with vulvar discomfort and pain in an attempt to provide a possible explanation for the pain by a health care provider who is not acquainted with PV condition.

### Hormonal contraception and PV

Hormonal oral contraceptive pills (OCP) have been claimed to be associated with an increase in PV incidence and severity.<sup>27</sup> OCPs infrequently lead to vaginal dryness and dyspareunia. Only a minority of the millions of women who use OCPs complain of dyspareunia. Furthermore, many women with level 3 PV do not use OCPs.

### Excluding other causes of vulvar pain

The first part of the consensus terminology contains a list of recognized causes of vulvar pain, including *Candida* and bacteriologic vaginal infections, dermatoses, deformities, birth lacerations, and past trauma.<sup>2</sup> These should be excluded before a diagnosis of vulvodynia can be made.

### Colposcopic examination

Experts of vulvar disease differ in opinions as to whether colposcopic examination of the vulva, commonly referred to as “vulvoscopy”, should be a part of vulvar examination. The traditional purpose of colposcopy after acetic acid application is to evaluate the cervix in a patient with abnormal pap test, looking for intraepithelial neoplasia. On the vulva, naked eye examination may suffice in many cases. However, colposcopy is performed by many experts to magnify the vestibule and look for vulvar lesions in women with human papilloma virus lesions, suspecting vulvar neoplasia in cases of PV. The exact painful vestibular foci can be localized with the aid of a colposcope, and a fissure may be found in the posterior fourchette. We found that when women with level 3 (severe) PV attempt intercourse, forced penile insertion leads numerous times to an erosion or ulcer (Figure 5) in the fourchette. This fissure sometimes bleeds with intercourse. It may be the most disturbing painful area and the presenting symptom of PV.

In addition, colposcopic magnification can aid in excluding the presence of intraepithelial neoplasia, inflammation, infection, or any other dermatologic diseases of the vulva. Erythema is a nonspecific finding, and although it was one of the classic “Friedrich’s clinical criteria” for diagnosing PV,<sup>16</sup> it should not be used as a criterion for diagnosing PV.

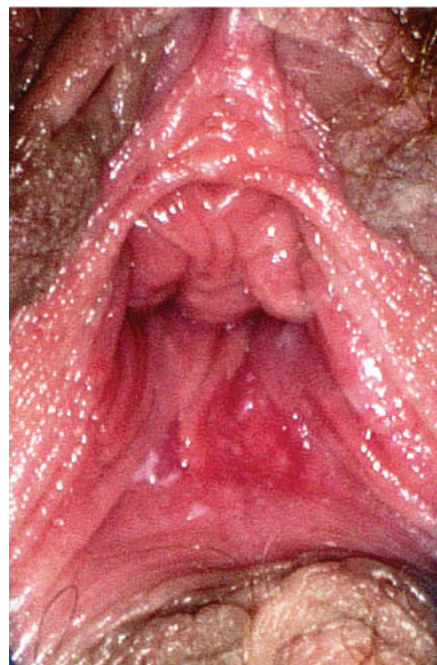
### Speculum examination

Performing a speculum examination of the vagina and cervix is often difficult or impossible because of entry sensitivity. It may be deferred until after the patient is more relaxed or improved with treatment. If a speculum examination was performed, any abnormal discharge should be evaluated for vaginitis. Women who are lactating, on birth control pills, or menopausal may have atrophic vaginal mucosa, which may be sensitive and cause or exacerbate vestibular sensitivity. However, the presence of any vaginal infection or atrophy does not exclude PV. They may coexist with PV, rather than being the cause of it.

Pelvic manual examination is essential for initial evaluation because it may help to determine which associated factor is present and needs attention. Inserting one finger to the vagina is less painful than two fingers, and it can suffice to evaluate the vagina, cervix, uterus, bladder, and pelvic musculoskeletal structures.

Digital pelvic examination is very important and should include the following:

- A gentle palpation of the urethra and bladder trigone. Tenderness of the bladder may be suggestive of either a urinary tract infection, a painful bladder syndrome (formerly interstitial cystitis), or endometriosis infiltration.
- Palpation of the deep pelvic musculoskeletal structures for the presence of tender points and hypertonicity. If these



**Figure 5.** Erosion in the 6 o’clock area of the vestibule, which is frequently caused by forceful intercourse in women with PV. It may bleed and hurt for a few days  
PV: Provoked vulvodynia

are detected, a hypertonic floor muscle dysfunction may be suspected, and a referral to pelvic floor assessment and possible rehabilitative physical therapy are recommended.

- The area around the ischial spine should be touched to detect the pudendal nerve. Tenderness of the pudendal nerve may suggest that the reason for the pain is pudendal neuralgia or pudendal nerve entrapment.
- The uterus and adnexa are palpated and moved to rule out pelvic inflammatory disease.
- If endometriosis is suspected, a recto-vaginal examination may reveal nodularity and sensitivity of endometriosis.

Repaired lacerations or episiotomies should be examined for sensitivity that may result from traumatic neuromas that can also be a source of pain in women who have had prior vaginal surgery. However, the notion that birth lacerations and episiotomy scars are a cause of dyspareunia is a myth. Postpartum dyspareunia results from the new onset of PV, while the scar tissue itself is not sensitive at all because the nerve nociceptors have been torn and destroyed in these foci.

### Assessment of the pelvis

Some women with PV may have an increase in pelvic floor muscle tone.<sup>28</sup> Interestingly, when the patient is asked to contract the introitus during a pelvic examination, the examiner hardly feels any contraction of the introital muscles, e.g., the bulbocavernosus muscle. However, the inner parts of the levator ani are usually contracted. The exact mechanism by which the instability of the pelvic floor is associated with PV is unclear. Nevertheless, detecting a musculoskeletal factor associated with PV requires physical therapy rehabilitation of the pelvic floor muscles.

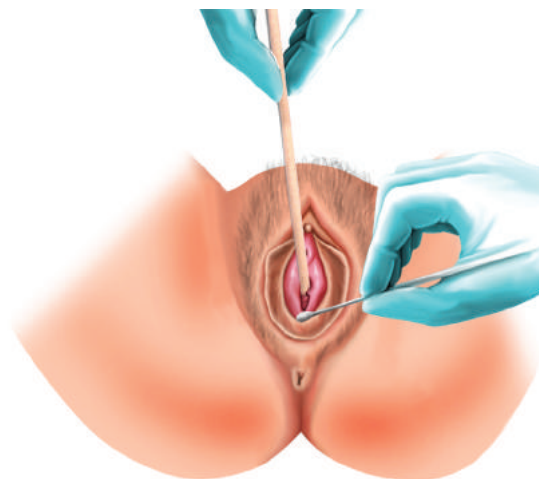
Furthermore, our group described another pelvic floor abnormality in women with PV; the inability of lax uterosacral ligaments (USLs) to support the adjoining T11/L2 and S2-4 nerve plexuses may cause PV.<sup>29,30</sup> We documented the involvement of these nerve plexuses in PV,<sup>31,32</sup> and showed in a randomized, control, crossover study that support of the USLs leads to temporary relief of the PV.<sup>30</sup> Hence, our group suggests that temporal support of the posterior vaginal fornix with a wide cotton swab or the posterior speculum blade, and repeating the Q-tip swab test<sup>30</sup> (Figure 6) should be a part of the routine examination of every patient with suspected PV. Diminution or disappearance of the vestibular sensitivity with this maneuver attests to the role of lax USLs in the pathogenesis of PV.

### Pathology of PV

A biopsy is not required for the diagnosis of vestibulodynia; however, as detailed in a previous publication in *Pelviperineology*,<sup>4</sup>

the four pathological features typical for vestibulodynia in biopsy are as follows:

- Stromal hyperinnervation: the stromal nerve cell surface area was found to be 10 times that of controls ( $p=0.01$ ).<sup>33</sup>
- Intraepithelial innervation: PGP 9.5 immunoreactive stain



**Figure 6.** Q-tip swab test is performed, while the wide swab stick is in the posterior fornix

shows intraepithelial nerve fibers only in women with PV. The fibers penetrate the basal membrane and continue vertically for more than half the distance to the epithelial surface.<sup>34</sup>

- Stromal inflammation localized around the minor vestibular minor glands.<sup>4</sup>
- Increased number of stromal mast cells. Our group showed that 90% of patients with PV have more than eight mast cells per high power field.<sup>33</sup> The detection of mast cells may be performed using Giemsa staining or immunohistochemistry detecting CD117 (c-kit) antigen.

### Serum testing

A reciprocal relationship between estrogen and vaginal innervation was observed in rodents.<sup>28</sup> In women with one of the conditions associated with vulvodynia - genitourinary syndrome of menopause (formerly atrophic vaginitis), a decreased serum estradiol level and a high level of follicle-stimulating hormone may be found. Elevated serum hormone-binding globulin and decreased free testosterone and estradiol levels may be detected in women with PV using OCP.<sup>28</sup>

### Is any additional testing required?

In most cases, vestibular examination is sufficient, and no other test is required to diagnose PV. However, additional testing may be necessary in the following women:

- In women with associated deep dyspareunia or deep pelvic pain, vaginal ultrasound examination and possibly magnetic resonance imaging studies should be carried out to diagnose endometriosis.
- Diagnostic laparoscopy may be necessary if a significant evidence of deep endometriosis is present.
- If nerve entrapment or compression is suspected, Tesla 3 magnetic resonance imaging using “nerve protocol” may be contributory.
- Colonoscopy and computed tomography scan with orally ingested contrast material may be used to rule out pathology of the lower gastrointestinal tract.
- Cystoscopy may be performed to diagnose painful bladder syndrome (interstitial cystitis) if PV is associated with lower abdominal pain, dysuria, etc.
- An electromyogram may be utilized to assess the tone and strength of the levator ani muscles when an evidence of hypertonic pelvic floor dysfunction is present.

**Determining the associated factor**

The paradigm shift that came about with the introduction of the consensus terminology and the associated factors of vulvodynia necessitates determining the management according to the factor associated with PV.

Based on the workup detailed above, we can determine the specific factors associated with vulvodynia in most cases (Table 4). In the event that a few factors seem to be associated with PV, an effort should be made to establish one cardinal

factor. Treating the main associated factor often times leads to resolution of other minor factors, so the therapeutic effort should concentrate on the main associated factor and not be “multi-disciplinary.” This is the case where a neuroproliferative PV is successfully treated by vestibulectomy; frequently any associated psychological factor is resolved without exclusive treatment.

Moreover, we further argue that one of the untoward befalling in the history of this condition occurs when health care providers link every dyspareunia with a psychological cause – “it is in your head” or as having a “multi-disciplinary” etiopathology, offering a fixed treatment program without concerning the unique characteristics of the specific presentation. This approach repeatedly blocks any breakthrough in the study of this perplexed condition.

**CONCLUSION**

Diagnosing PV should be conducted according to a structured plan. Diagnosis is based on the understanding of the associated factors of PV as described in the consensus terminology. Informing the patient of the diagnosis of PV usually relieves a lot of uncertainty from her after many years of suffering from unexplained extreme pain with each attempted vaginal intercourse. It is a required step to tailoring a successful treatment.

**Ethics**

**Peer-review:** Externally peer-reviewed.

Table 4. Determinants of provoked vulvodynia associated factors		
Associated factor <sup>13</sup>		Determinants <sup>28</sup>
<b>Comorbidities and other pain syndromes</b>		Painful bladder syndrome, fibromyalgia, irritable bowel syndrome, and temporomandibular disorder
<b>Genetics</b>		A familial history of vulvodynia. Polymorphism c.945G>C (rs222747) of the gene <i>TRPV1</i> and a SNP in the promoter region of the gene of <i>NGF</i> (rs11102930)
<b>Hormonal factors</b>		Long term oral contraceptive pills usage or genitourinary syndrome of the menopause <sup>27</sup> Low serum Estradiol or high serum level of follicular stimulating hormone <sup>28</sup>
<b>Inflammation</b>		Biopsy showing an increased number of mast cells, reduced systemic number of natural killer cells. Repeated history of proven vulvovaginal candidiasis <sup>23</sup>
<b>Musculoskeletal</b>		Pelvic muscle instability, myofascial sensitivity, Uterosacral ligaments laxity <sup>29,30</sup>
<b>Neurologic mechanisms</b>	Central (spinal and brain-related)	Structural and functional magnetic resonance imaging studies demonstrating an increased grey matter volume in the basal ganglia, sensorimotor cortices and the hippocampus.
	Peripheral neuro-proliferation	Biopsy revealing hyperinnervation by PGP 9.5 stain <sup>4,33,34</sup>
<b>Psychosocial factors</b>		Impaired mood, interpersonal, coping roles, and sexual function
<b>Structural defects</b>		Perineal descent

SNP: Single nucleotide polymorphism, TRPV1: Transient receptor potential cation channel subfamily V member 1, NGF: Nerve growth factor

## DISCLOSURES

**Conflict of Interest:** There are no conflicts of interest to declare.

**Financial Disclosure:** The authors declared that this study received no financial support.

## REFERENCES

- Bornstein J. Vulvar pain and vulvodynia. In: Bornstein J, ed. *Vulvar Disease*. 2019; 343-67. 1st ed. Cham, Switzerland: Springer Nature.
- Bornstein J, Goldstein AT, Stockdale CK, et al. 2015 ISSVD, ISSWSH, and IPPS consensus terminology and classification of persistent vulvar pain and vulvodynia. *J Lower Gen Tract Dis* 2016; 20: 126-30.
- Bornstein J. The consensus terminology of persistent vulvar pain and vulvodynia. *Pelviperineology* 2018; 37: 3-5.
- Bornstein J, Palzur E. Provoked vulvodynia: a peripheral neurological pain syndrome. *Pelviperineology* 2020; 39: 68-76.
- Bornstein J, Maman M, Abramovici H. Primary versus secondary vestibulitis - one disease, two variants. *Am J Obstet Gynecol* 2001; 184: 28-31.
- van Lankveld JJDM, Granot M, Weijmar Schultz WCM, et al. Women's sexual pain disorders. *J Sex Med* 2010; 7: 615-31.
- Reed BD, Harlow SD, Sen A, et al. Prevalence and demographic characteristics of vulvodynia in a population-based sample. *Am J Obstet Gynecol* 2012; 206: 170.e1-9.
- Reed BD, Haefner HK, Sen A, Gorenflo DW. Vulvodynia incidence and remission rates among adult women: a 2-year follow-up study. *Obstet Gynecol* 2008; 112: 231-7.
- Reed BD, Crawford S, Couper M, Cave C, Haefner HK. Pain at the vulvar vestibule: a web-based survey. *J Low Genit Tract Dis* 2004; 8: 48-57.
- Harlow BL, Stewart EG. A population-based assessment of chronic unexplained vulvar pain: have we underestimated the prevalence of vulvodynia? *J Am Med Womens Assoc (1972)* 2003; 58: 82-8.
- Arnold LD, Bachmann GA, Rosen R, Rhoads GG. Assessment of vulvodynia symptoms in a sample of US women: a prevalence survey with a nested case control study. *Am J Obstet Gynecol* 2007; 196: 128.e1-6.
- Harlow B, Kunitz C, Nguyen R, Rydell S, Turner R, MacLehose R. Prevalence of symptoms consistent with a diagnosis of vulvodynia: population-based estimates from 2 geographic regions. *Am J Obstet Gynecol* 2014; 210: 40.e1-8.
- Bornstein J, Preti M, Simon JA, et al. A multisocietal definition consensus (International Society for the Study of Vulvovaginal Disease, the International Society for the Study of Women Sexual Health, and the International Pelvic Pain Society). *J Low Genit Tract Dis* 2019; 23: 161-3.
- Wagenlehner FME, Frohlich O, Bschiepfer T, Weidner W, Perletti G. The integral theory system questionnaire: an anatomically directed questionnaire to determine pelvic floor dysfunctions in women. *World J Urol* 2014; 32: 769-81.
- Turk DC, Dworkin RH, Allen RR, et al. Core outcome domains for chronic pain clinical trials: IMMPACT recommendations. *Pain* 2003; 106: 337-45.
- Friedrich EG Jr. Vulvar vestibulitis syndrome. *J Reprod Med* 1987; 32: 110-4.
- Pukall CF, Binik YM, Khalifé S, Amsel R, Abbott FV. Vestibular tactile and pain thresholds in women with vulvar vestibulitis syndrome. *Pain* 2002; 96: 163-75.
- Reed BD, Plegue MA, Harlow SD, Haefner HK, Sen A. Does degree of vulvar sensitivity predict vulvodynia characteristics and prognosis? *J Pain* 2017; 18: 113-23.
- Pukall CF, Binik YM, Khalifé S. A new instrument for pain assessment in vulvar vestibulitis syndrome. *J Sex Marital Ther* 2004; 30: 69-78.
- Marinoff SC, Turner ML. Vulvar vestibulitis syndrome. *Dermatol Clin* 1992; 10: 435-44.
- Foster D, Kotok M, Huang L, et al. The tampon test for vulvodynia treatment outcomes research: reliability, construct validity, and responsiveness. *Obstet Gynecol* 2009; 113: 825-32.
- Reed BD, Harlow SD, Plegue MA, Sen A. Remission, relapse, and persistence of vulvodynia: a longitudinal population-based study. *J Womens Health (Larchmt)* 2016; 25: 276-83.
- Smith EM, Ritchie JM, Galask R, Pugh EE, Jia J, Ricks-McGillan J. Case-control study of vulvar vestibulitis risk associated with genital infections. *Infect Dis Obstet Gynecol* 2002; 10: 193-202.
- Farmer MA, Taylor AM, Bailey AL, et al. Repeated vulvovaginal fungal infections cause persistent pain in a mouse model of vulvodynia. *Sci Transl Med* 2011; 3: 101ra91.
- Bornstein J, Livnat G, Stolar Z, Abramovici H. Pure versus complicated vulvar vestibulitis: a randomized trial of fluconazole treatment. *Gynecol Obstet Invest* 2000; 50: 194-7.
- Marinoff SC, Turner ML. Hypersensitivity to vaginal candidiasis or treatment vehicles in the pathogenesis of minor vestibular gland syndrome. *J Reprod Med* 1986; 31: 796-9.
- Burrows LJ, Basha M, Goldstein AT. The effects of hormonal contraceptives on 33 female sexuality: a review. *J Sex Med* 2012; 9: 2213-23.
- Bergeron S, Reed BD, Wesselmann U, Bohm-Starke N. Vulvodynia. *Nat Rev Dis Primers* 2020; 6: 36.
- Petros P, Bornstein J. Re: vulvar vestibulitis may be a referred pain arising from laxity in the uterosacral ligaments: a hypothesis based on three prospective case reports. *Aust N Z J Obstet Gynaecol* 2004; 44: 484-5.
- Schonfeld M, Petros P, Bornstein J. Mechanically supporting uterosacral ligaments for the relief of provoked vulvodynia: a randomised pilot trial. doi: 10.22541/au.160029751.13887485
- Bornstein J, Zarfati D, Petros P. Causation of vulvar vestibulitis. *Aust N Z J Obstet Gynaecol* 2005; 45: 538-9.
- Zarfati D, Petros P. The Bornstein test-a local anaesthetic technique for testing uterosacral nerve plexus origins of chronic pelvic pain. *Pelviperineology* 2017; 36: 89-91.
- Bornstein J, Goldshmid N, Sabo E. Hyperinnervation and mast cell activation may be used as histopathologic diagnostic criteria for vulvar vestibulitis. *Obstet Gynecol Invest* 2004; 58: 171-8.
- Bornstein J, Cohen Y, Zarfati D, Sela S, Ophir E. Involvement of heparanase in the pathogenesis of localized vulvodynia. *Int J Gynecol Pathol* 2008; 27: 136-41.



# Minimal invasive and effective therapy of faecal incontinence with a preanal tape

● SIDI MUCTAR<sup>1</sup>, ● ANDREI I MÜLLER-FUNOGEA<sup>2</sup>, ● MARTIN KOWALLIK<sup>3</sup>, ● NICOLAS FISCHER<sup>4</sup>

<sup>1</sup>Department of Urogynaecology, Helios Kliniken Krefeld, Lutherplatz, Germany

<sup>2</sup>Department of Gynaecology, St-Antonius Hospital Eschweiler, Germany

<sup>3</sup>Department of Coloproctology, Magen-Darm-Zentrum Wiener Platz, Cologne, Germany

<sup>4</sup>Department of Urology, Universitätskliniken Köln, Cologne, Germany

## ABSTRACT

**Objective:** The existing surgical therapy modalities for the treatment of faecal incontinence do not provide satisfactory results. Our understanding of the pelvic floor anatomy and physiological biomechanics of the anal canal are the basis for the theoretical development and practical therapy of faecal incontinence.

**Materials and Methods:** According to the Integral Theory System and similarly to a suburethral sling, a preanal sling is placed under the pelvic floor.

**Results:** The presented operation was successfully done on three patients beyond treatment for their faecal incontinence.

**Conclusion:** We present a simple and functional surgical method for the treatment of faecal incontinence.

**Keywords:** Anatomy; faecal incontinence; sphincter; minimal invasive surgery; rectum

## INTRODUCTION

Faecal incontinence is defined by involuntary, uncontrolled faecal loss. The prevalence of faecal incontinence is high. In the literature the prevalence is: 7-15% in the general population, in hospitals up to 30% and in nursing homes up to 70%.<sup>1</sup> The number of unreported cases is probably higher, as patients do not report it spontaneously and most doctors do not specifically ask about faecal incontinence routinely during the medical history survey. The causes that lead to faecal incontinence are manifold. Local anatomical changes affecting the sphincter ani, pelvic floor muscles, ligaments, fascia and their visceral and somatic innervations can be causes of faecal incontinence. Diseases of the peripheral and central nervous system can also

cause defecation problems and faecal incontinence. Accurate anamnesis, examinations such as perineal sonography, anorectal manometry, rectoscopy, digital rectal examination, as well as the dynamic pelvic floor magnetic resonance imaging (MRI), are important assessment tools for the anatomy and function of the anal canal.<sup>2</sup>

Therapy modalities vary from conservative to surgical. Bharucha et al.<sup>3</sup> list for the therapy of faecal incontinence “15 best practice advice”, of which 13 practices are classified as surgical interventions.<sup>3</sup>

This list shows that there is no best surgical solution for the treatment of faecal incontinence. It is therefore of uttermost importance to develop a reliable therapy for faecal incontinence.<sup>4</sup>

**Address for Correspondence:** Nicolas Fischer, Department of Urology, Universitätskliniken Köln, Cologne, Germany

**E-mail:** simplissimus@gmx.de **ORCID ID:** orcid.org/

**Received:** 20 October 2020 **Accepted:** 03 November 2020

We present a simple and functional surgical method for the treatment of faecal incontinence.

### MATERIALS AND METHODS

Three patients suffering from faecal incontinence were submitted to this new operation. All three underwent multiple conservative therapies and operations without satisfactory results. A colostomy was finally indicated for all these patients as the lesser evil choice. We offered our new operation as an alternative possibility for them to avoid colostomy.

We explained the anatomical and physiological principles of this operation, the operation itself and the preliminary experiments on corpses performed anteriorly. The operation is performed in dorsal lithotomy position with intraoperative antibiotic administration as a single-shot with metronidazole and ceftriaxone. The principles of this operation are based on the integral biomechanical movements of the anal sphincter and the pelvic floor muscles. The operation itself is performed below the pelvic floor on the sphincter ani while integrating the ligaments.

### Anatomy

Undisturbed and intentionally controlled flow and retention of stool through the anus are ensured by intact pubococcygeus (PCM), puborectalis (PRM), longitudinal anal (LAM) and sphincter ani muscles. For support, the sacrouterine ligaments (SUL), the rectovaginal fascias and the perineal body according to the musculo-elastic theory of Prof. Peter Petros play an important role in the function of the anorectal canal.<sup>5</sup> The PCM stretches from the bottom edge of the os pubis to the os coccygeus. It is divided in two components. The front component is responsible for opening and closing the bladder during micturition. The posterior component, the levator plate (LP), is responsible for opening the canal.

At the point where the two components connect, two circular openings are formed. The front opening is the hiatus genitalis, the posterior one is the hiatus analis. In the hiatus analis, the rectum runs downwards and merges with the sphincter ani. At this point, the rectum is connected anteriorly to muscle cords of the PCM. These run downwards and form the frontal LAM.<sup>6</sup> Posteriorly, the rectum is connected to branches of the LP. These branches form the posterior part of the LAM (Figure 1).

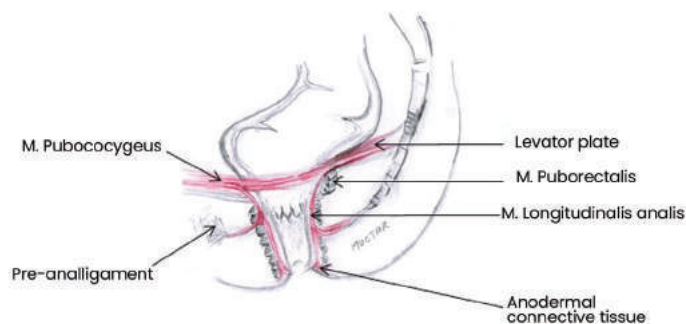
Below the PCM lies the PRM. It comes from the lower edge of the symphysis, circles around the posterior surface of the rectoanal compound and runs back in the opposite direction to the symphysis, where it is attached.

A very important muscle for the function of the canal, which is sometimes ignored, is the LAM. This muscle runs down through the hiatus analis, inter-sphincterically to the anodermal

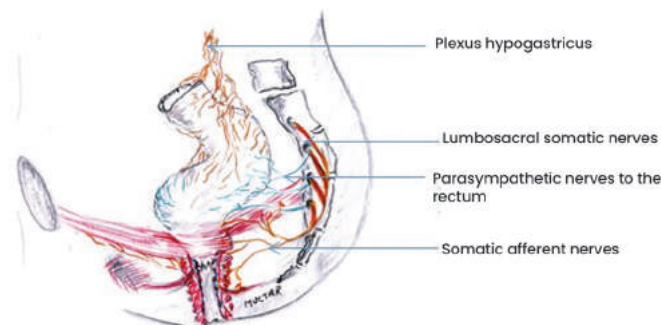
connective tissue, where it is attached. Parts of his muscle fibres emerge from the sphincter ani externus wall and run with the pre- and post- anal ligaments. They anchor anteriorly in the perineal body and posteriorly with the os coccygeus. The main function of the LAM is to widen the canal during defecation, while at the same time, the PRM relaxes and the PCM simultaneously clamps with the LP in the opposite direction. The sphincter ani and the pelvic floor muscles are innervated with somatic nerve branches of the N. pudendus. The rectum wall and its longitudinal and circular muscles are innervated with parasympathetic nerves (Figure 2).

### Physiology

In the literature, the causes of stool incontinence are manifold and reported as multifactorial. Based on the musculo-elastic theory, we present here a contribution to clarify the dynamics of the defecation process. The anal canal complex consists of the external and internal sphincters, the LAM, connective tissue, nerves, vessels and mucosa. The LAM runs topographically between external and internal sphincter. They function as a unit. They are innerved through somatic and visceral nerve branches. The anal canal complex as a defecation and retention unit includes the pelvic floor muscles, ligaments and fascia, which



**Figure 1.** Course of the LAM between the internal and external sphincter, through the pre- and postanal ligaments and anchoring to the anodermal connective tissue  
LAM: Longitudinal anal



**Figure 2.** Description of the innervation of the pelvic floor

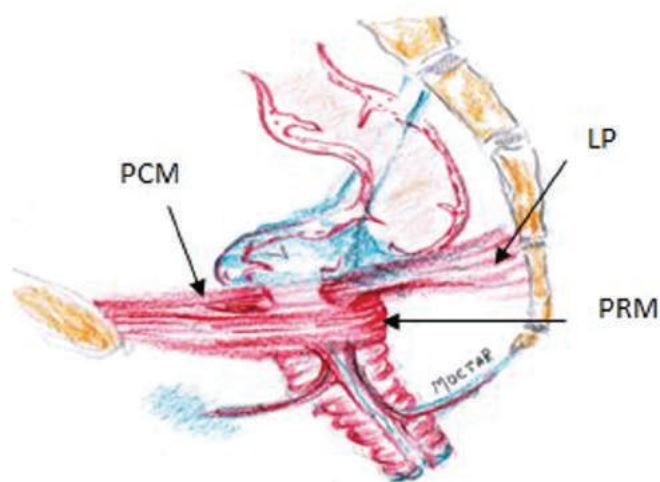


interact synchronously and temporarily with the sphincter ani. This unit can be disturbed by changes in position, lesions and degeneration of the individual components. From the results of the literature on diagnostics, such as dynamic MRI defaecography, rectal manometry, pudendal and tibial nerve conduction studies, the course of defecation is interpreted here as follows:

At rest, the PCM and the LAM are relaxed. The PCM, the internal sphincter ani and in combination with a relaxed ampoule recti, they are minimally stretched, so that no air or stool can be lost incidentally.<sup>7</sup>

During defecation, the PCM is contracted bidirectionally. The PCM has two components. The anterior part of the PCM moves forward towards os pubis (Figure 3). The LP moves posteriorly towards the os sacrum. Thus, the LAM, which originates from these muscles and runs caudally between the internal and external anal sphincter is stretched. This stretching expands the anal canal circumference, hence opening the canal.

This opening is supported by the relaxation of the PRM and the external sphincter ani. This is followed by the expulsion of the faeces from the ampoule recti, which contracts during defecation. A contraction of the puborectal muscle pulls the cranial part of the anal canal forward, while the lower part of the anal canal, fixed by the pre- and post-anal ligaments, is only slightly displaced cranially. The position and function of the anal canal are ensured by ligaments and connective tissue [pre- and post- anal ligaments, SUL/rectovaginal fascias (RVF)], which are drawn in blue (Figure 3). If ligaments and connective tissue are weakened or damaged, the muscles cannot fully perform their



**Figure 3.** Shows the inclination of the anal canal towards the front in a situation of a filled ampoule recti  
PCM: Pubococcygeus muscle, LP: Levator plate, PRM: Puborectalis muscle

assigned functions. The consequences are prolapse of the pelvic organs up to stool and/or urine loss.<sup>8</sup> When the puborectal muscle is taut, it pulls the anal canal forward by 20°. This forward inclination, which can also be seen dynamically during exertion or cough in perineal sonography, led us to believe that stabilizing the anal canal against the traction of the puborectal muscle could lead to a sufficient change in pressure in the lumen of the anal canal. This insight led to the preanal surgery method we describe and has proven to be effective for treating stool incontinence due to insufficient sphincter pressure.

Own observations are confirmed in various studies according to which lesions or weakening of LAM alone or in combination with the SUL can cause dysfunctions of the rectoanal canal such as constipation or incontinence.<sup>9</sup> Therefore, in stool incontinence with clinically detectable prolapse genitalis or in rectoceles the correction of ruptures or relaxations of the SUL should also be considered.

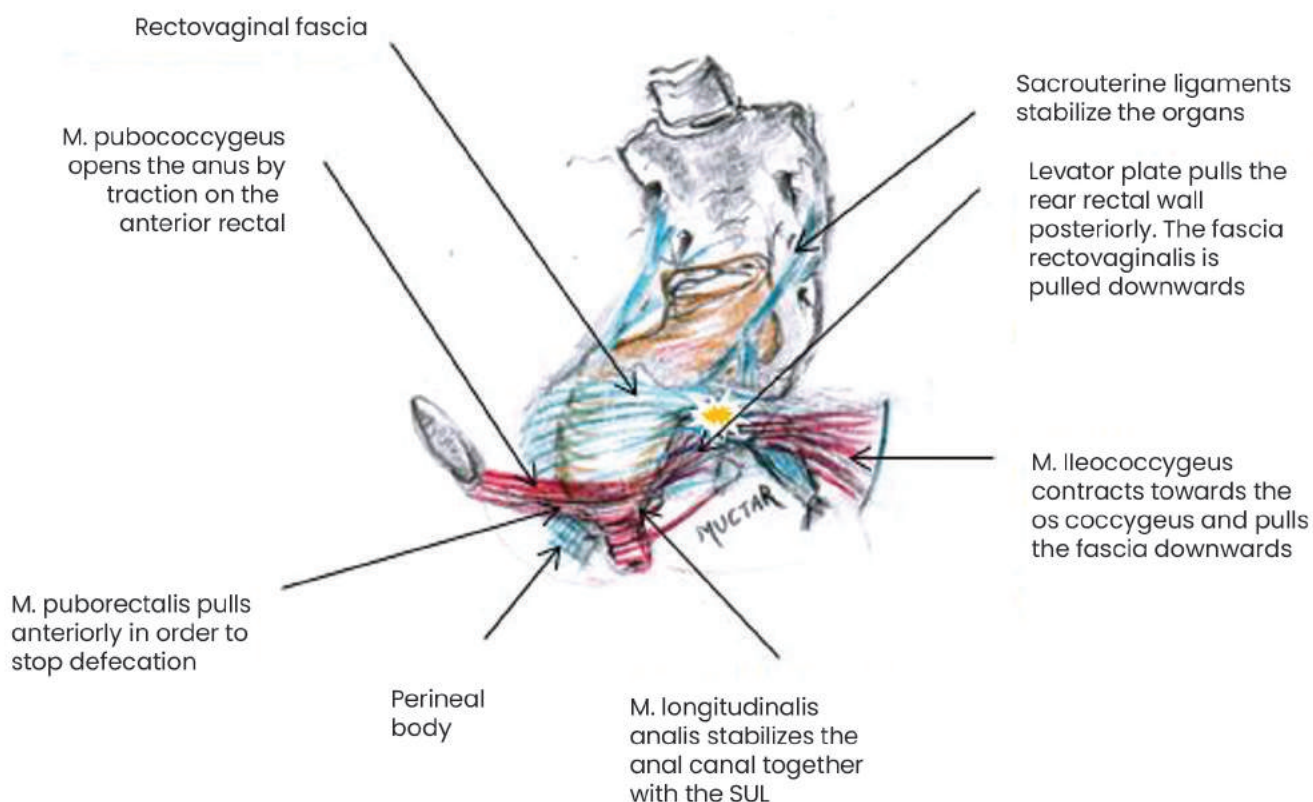
Figure 4 demonstrates the physiology and pathophysiology of stool continence. The yellow mark shows where all muscle forces meet for the physiological closure of the rectal canal. If the bowel movement is interrupted, the ileococcygeus muscle contracts towards the os coccygeus. Together with the LP, it pulls the rectovaginal fascia diagonally backwards so that the rectoanal angle is stressed. The PRM is contracted and narrows the anal canal. SUL, RVF and PB form a unit to harmonize the function of the pelvic floor muscles.

Seen from above, the PCM is the first muscle layer of the pelvic floor muscles. It consists of two components. The anterior part lies between the os symphysis and the rectum, the posterior component, also known as the LP, lies between the rectum and the os coccygeus. When holding and during defecation, both components can move in the same direction as required or independently pull in opposite directions. This explains why we can only initiate defecation or micturition as well as both at the same time.

As soon as there is an urge to defecate, the PFM and anal sphincter muscles will act according to their function. Under normal physiological conditions, the stool can be held or emptied at will.

Helpful diagnostic tools include anorectal tonometry, perineal and endoluminal anal sonography for assessing the anatomy and function of the sphincter. The dynamic pelvic floor MRI supports the assessment of both the anatomical structural intricacies as well as the functional anatomy of the pelvic floor and the pelvic organs.

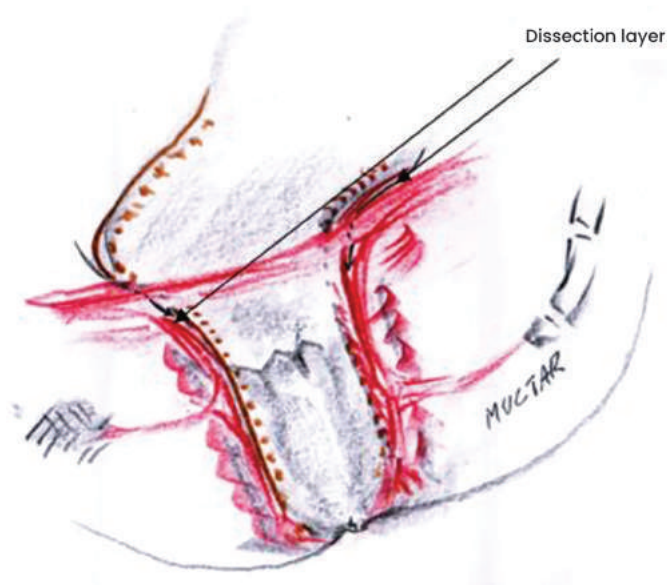
There are different methods to graduate the severity of faecal incontinence. However, in the hands of the experienced



**Figure 4.** Shows the physiology and pathophysiology of stool continence. The yellow mark shows where all muscle forces meet for the physiological closure of the rectal canal  
SUL: Sacrouterine ligaments

investigator, digital rectal examination is a safe and sufficient method for estimating the tonus of the sphincter ani muscle.<sup>10</sup> This, in combination with a comprehensive history, is an important indicator in decision-making for further examinations as well as for the treatment of sphincter ani incontinence.

The results of surgical treatment for deep-seated rectal cancer have recently improved considerably due to advances in technology. However, the consequences of the operation have not been optimally resolved. Obviously, deep rectal resection carries the risk of postoperative stool incontinence.<sup>11</sup> The illustration (Figure 5) shows the fine anatomy of the anal canal. Accordingly, the narrow space along the anal canal between the LAM and the LRM (longitudinal rectal muscle) should be accurately dissected during the operation. In our understanding of the dynamics and physiopathology of the recto-anal complex, this space is the path of dissection for deep rectal resection to ensure continence. The LAM is an arbitrarily controlled component. The LRM is a component controlled by the parasympathetic nervous system. Both muscles are very important units for anal continence. With deep rectal resection one should consider the relationship between muscles and avoid parasympathetic nerve branches.



**Figure 5.** The illustration shows the fine anatomy of the anal canal and the dissection layer of the operation. The illustration shows the fine anatomy of the anal canal. The narrow space along the anal canal between the LAM and the LRM should be accurately spared during resections for low rectal tumors  
LAM: Longitudinal anal muscle, LRM: Longitudinal rectal muscle

## Surgical technique

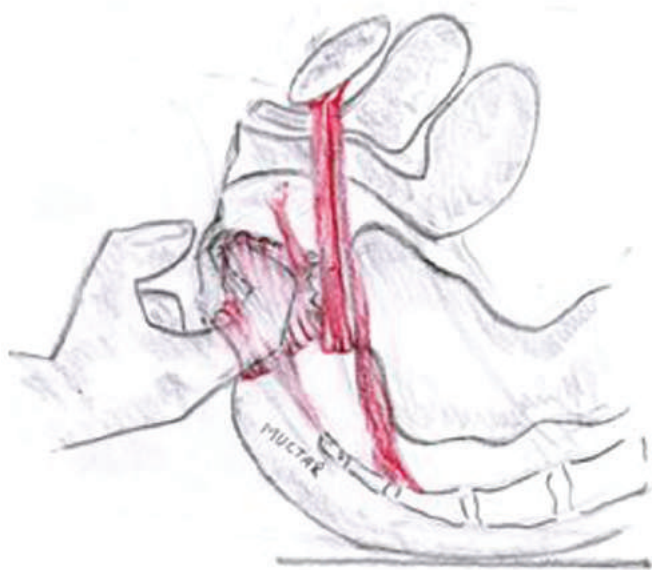
Before performing this innovative surgical technique in vivo, we first performed an experimental operation on a female corpse at an urogynaecological workshop. In the following the U-shaped pre-anal tape system as a sphincter support was carried out in three highly faecal incontinent patients. The operation takes place below the pelvic floor. Therefore, the organs that lie above the pelvic floor are not endangered by the operation. An additional advantage of this technique is in addition to the fixation of the canal, that a stabilization of the pelvic floor can be achieved.

## Operation description

The operation is carried out in dorsal lithotomy position with intraoperative antibiotic intravenous administration as a single-shot of Metronidazole and Ceftriaxone. The index is inserted into the anal canal to assess the resting pressure of the canal. The finger then pushes the middle portion of the canal forward so that the correct cutting site on the perineum can be estimated (Figure 6).

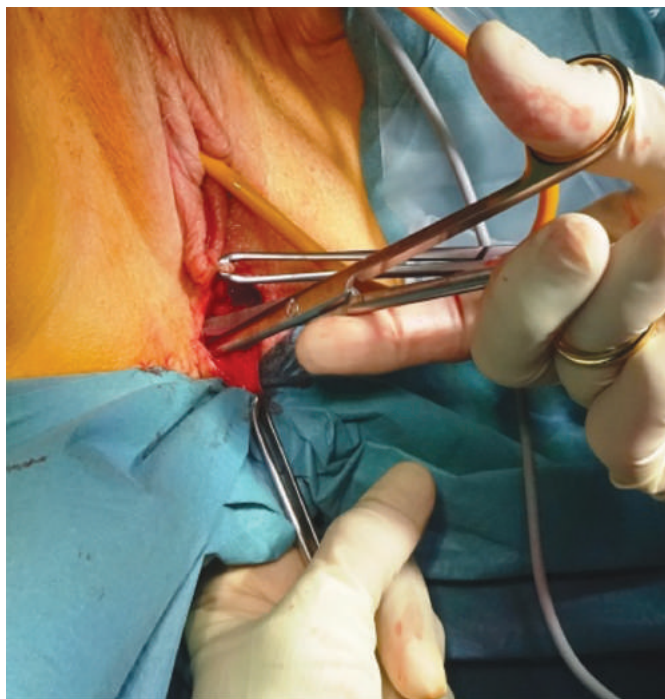
A paraanal cavum is then dissected bilaterally below the pelvic floor with scissors. A tunnel to the spina ischiadica is then formed using digital blunt dissection, (Figure 7). The tape is attached three centimetres medially from the spina on the sacrospinal ligaments (Figure 8 and 9).

There are various techniques for fixing the tape at this point, depending on the system used. We use either an I-Stitch® or the TFS® system. The TFS® system has the advantage of being still adjustable after anchoring it to the sacrospinal ligaments, so

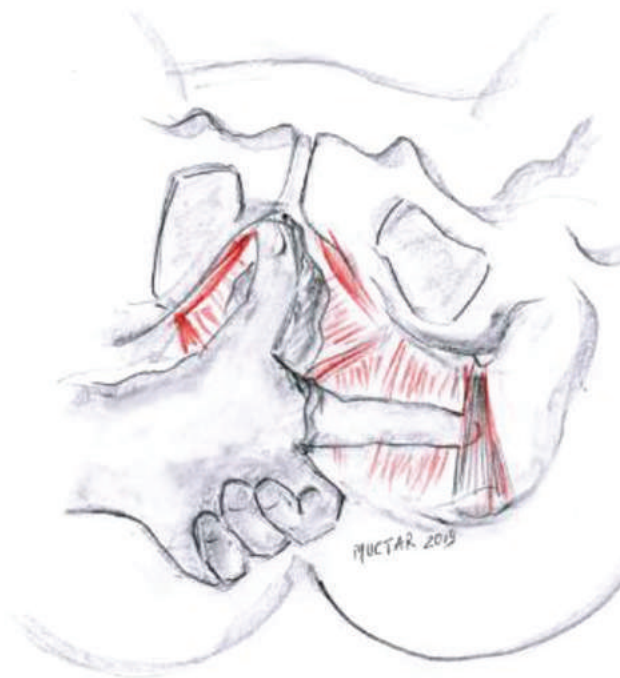

**Figure 6.** Assessing the location of the incision on the perineum with the thumb

that the tension can be set to the desired pressure. The required pressure can be estimated digitally or, better using manometry at 40-60 cmH<sub>2</sub>O (Figure 10). Alternatively, the tape can be applied through a pararectal access as in prolapse- and rectocele correction. Here, the procedure takes place below the pelvic floor as well.

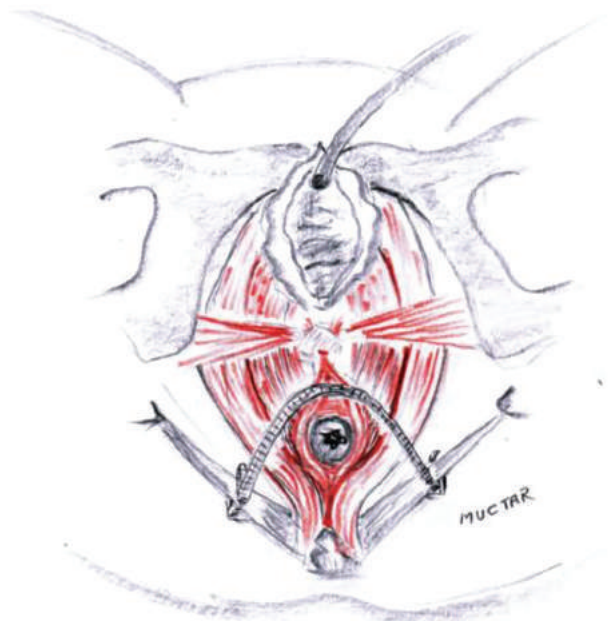


**Figure 7.** Dissection of the paraanal space with scissors

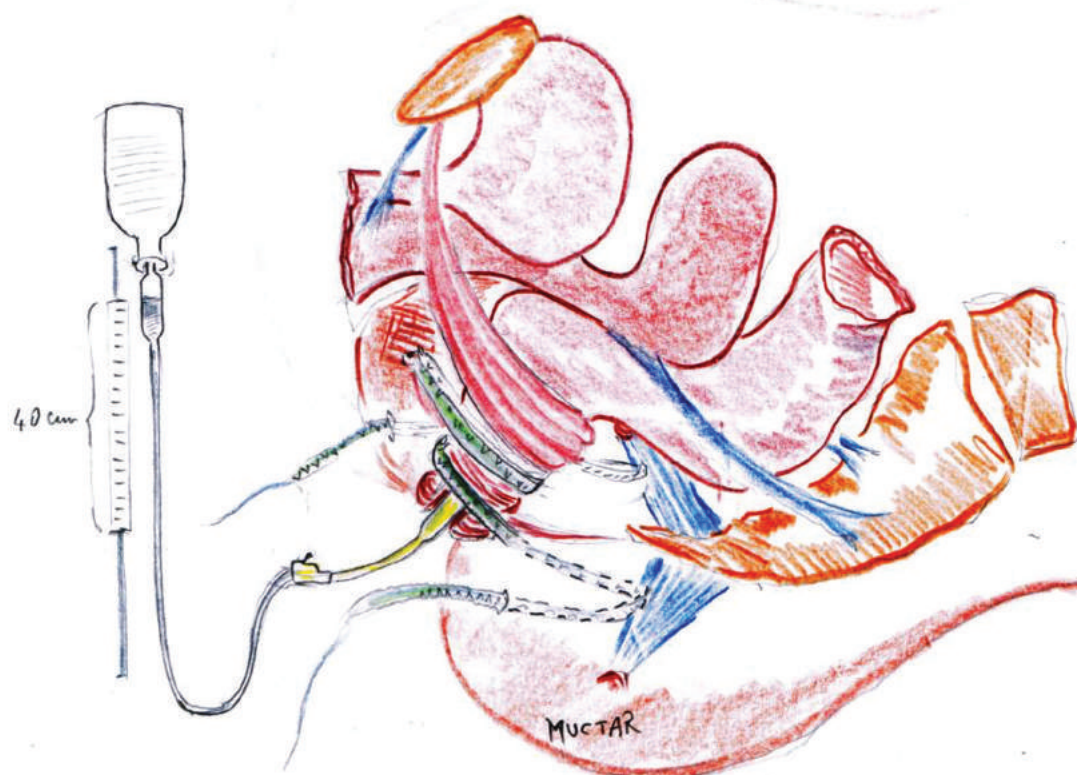


**Figure 8.** Palpation of the sacrospinal ligament with a finger and choosing a suitable position for the tape. Cave: The finger runs below the Pelvic floor muscles

For the execution of this surgical technique we used medically approved non-coated polypropylene tapes, such as the suburethral tape [trans vaginal tape (TVT) or transobturator tape (TOT)] in urine incontinence. No additional approval of the ethics committee was therefore required.



**Figure 9.** Final position of the tape on the front circumference of the anal canal. The wound is then closed



**Figure 10.** A transanal manometer is used to assess the intra-anal pressure. Alternatively, this can also be done by placing a finger in the anal canal. This latter method depends on the experience of the surgeon

## Patients

Three patients underwent this operation. All three of them suffered from faecal incontinence and were ultimately to be submitted to a colostomy. Prior to our operation, they experienced unsuccessful conservative, dietary and surgical measures and were declaredly beyond treatment. Before colostomy as a final procedure, we offered the operation aiming at a support of the anal canal with a U-shaped sling. All patients approved after extensive informed consent.

## RESULTS

The sphincter tonus to graduate the severity of faecal incontinence was estimated by the digital rectal exam and in combination with a comprehensive medical history, was an important indicator in the decision-making process for the treatment of sphincter ani incontinence.

Through intensive study of the dynamic pelvic floor MRI, we were able to observe how the pelvic floor muscles interact with the sphincter ani. From these observations, we developed a theory of a functionally oriented surgical method, and the operation on a corpse was found to be simple and feasible. In addition to a second-degree recurrent rectocele with a weak perineal body, one patient (patient 2) also had a general connective tissue weakness, known as Marfan syndrome. Intraoperatively,

we found in this patient that her pelvic connective tissue and sacrospinal ligaments were not sufficiently resistant to securely attach the anchor. In this case, we performed a modified version of the U-tape attaching it additionally on the posterior anal circumference. The intraanal pressure measurement showed sufficient pressure for holding stool. Postoperatively, this patient developed complete stool retention. The following day, we were able to detect an almost normal pressure of the anus during the rectal digital examination. However, during the defecation attempt, we noticed a narrowing of the canal, which dissolved at rest. Therefore, we had to readjust the tension of the tape. The patient was discharged the following day without complications. The postoperative follow-up after four months showed no negative effect of the tape on the canal. The patient is still continent to date.

Both two other patients did not show any complications postoperatively. Four months after demission, they were both continent and satisfied with the results. During postoperative inspection and digital examination, we could not detect any anatomical or pathological changes in the canal.

## DISCUSSION

Stool continence is ensured by synchronous interaction of muscles, ligaments and fascias. These are the PRM, the PCM, the LAM, the SUL, the perineal body and the sphincter ani (Figure 3). All these components are innervated by somatic nerve branches of the N. pudendus and vegetative nerve branches on both sides (Figure 4). Other components such as the compliance of the rectum volume and the mental perception of the stool process have a major influence on the regulation of the bowel motion.

The position and relationships of the pelvic organs to each other can be recognized and assessed excellently by perineal sonography in dorsal lithotomy position. The dynamics and the directions of movement of the anorectal section are easily interpretable.

The canal is tilted forward at rest around 20°. It is secured in this position by the pre- and postanal musculoelastic ligaments as well as the LAM muscles. In the relaxed state, the pelvic floor muscles and the pre- and postanal ligaments secure the position and inclination of the canal forwards. Under tension, the PRM muscle loop pulls together with the preanal ligament on the ano-rectal angle, which narrows the rectum and pulls the anus forwards. The preanal ligament is firmly connected with the perineal body. Loosening of the ligament is usually caused by lesions of the perineal body, such as trauma at birth. The loosening of the preanal ligaments in combination with other components functionally important for undisturbed defecation

can lead to destabilization of the topography of the canal and subsequently to stool incontinence. These observations, supported by perineal sonography and dynamic pelvic floor MRI, led us to a theory aiming at the stabilization of the canal. Therefore, in non-sphincterian stool incontinence with clinically detectable prolapse genitalis or in rectoceles the correction of ruptures or relaxations of the SUL should also be considered. The literature states that common surgical methods for the treatment of this type of stool incontinence such as fillers, muscle interponates, artificial sphincters or sacral neuro stimulation do not show statistically good and reliable results.<sup>12</sup> We have found both in corpse preparation and *in vivo*, that the prototype we have designed in extension to the Integral Theory System to stabilize the pre-anal ligament leads to a stabilization and increase of pressure.

According to the integral theory of Prof. Peter Petros and Prof. Ulmsten, stress urinary incontinence could be treated through stabilization of the urethra by strengthening the pubourethral ligaments. The TVT as a minimally invasive procedure was introduced 30 years ago.<sup>13</sup> Similarly, the preanal tape works as a minimally invasive therapy for stool incontinence. The fixation and repositioning of the canal by means of a tape below the pelvic floor muscles leads to reliable stool continence.<sup>14</sup>

The aim of the operation is to stabilize the anal canal with a broadly open U-shaped pre-anal tape fixed to the sacrospinal ligaments. Access is provided by a perineal section. The fixation of the preanal ligament by this technique also leads to the lifting and stabilization of an existing pelvic floor muscle relaxation. The tape position is easily verifiable so that it may be simply removed in case of possible early or late complications.

## CONCLUSIONS

The preanal tape is a simple, fast and effective method in the treatment of faecal incontinence especially with atone sphincter ani because it drives correctly the closing forces of the pelvic floor muscles to the rectum. Without providing long-term results, we hope to have provided a small contribution to the existing treatment options. Studies to develop a suitable proprietary device for the aims of this technique were already started by us.

## Ethics

**Informed Consent:** All patients approved after extensive informed consent.

**Ethics Committee Approval:** No additional approval of the ethics committee was therefore required.

**Peer-review:** Externally peer-reviewed.

## DISCLOSURES

**Conflict of Interest:** The authors have no conflicts of interest.

**Financial Disclosure:** The authors declared that this study has received no financial support.

## REFERENCES

1. Frieling T. Incontinence - Etiology, diagnostics and Therapy. Dtsch Med Wochenschr 2016; 141: 1251-60.
2. Prichard DO, Lee T, Parthasarathy G, Fletcher JG, Zinsmeister AR, Bharucha AE. High-resolution Anorectal Manometry for Identifying Defecatory Disorders and Rectal Structural Abnormalities in Women. Clin Gastroenterol Hepatol 2017; 15: 412-20.
3. Bharucha AE, Rao SSC, Shin AS. Surgical Interventions and the Use of Device-Aided Therapy for the Treatment of Faecal Incontinence and Defecatory Disorders. Clin Gastroenterol Hepatol 2017; 15: 1844-54.
4. Saldana Ruiz N, Kaiser AM. Faecal incontinence - Challenges and solutions. World J Gastroenterol 2017; 23: 11-24.
5. Petros PP, Swash M. A Musculo-Elastic Theory of anorectal function and dysfunction in the female. Pelviperineology 2008; 27: 86-7.
6. Muro S, Yamaguchi K, Nakajima Y, et al. Dynamic intersection of the longitudinal muscle and external anal sphincter in the layered structure of the anal canal posterior wall. Surg Radiol Anat 2014; 36: 551-9.
7. Bharucha AE, Fletcher JG, Harper CM, et al. Relationship between symptoms and disordered continence mechanisms in women with idiopathic faecal incontinence. Gut 2005; 54: 546-55.
8. Petros PE. Cure of urinary and faecal incontinence by pelvic ligament reconstruction suggests a connective tissue etiology for both. Int J Urogynecol 1999; 10: 356-60.
9. Muctar S, Schmidt WU, Batzill W, Westphal J. Functional anatomy of the female pelvic floor: interdisciplinary continence and pelvic floor surgery. Urologe A 2011; 50:785-91.
10. Tantiplachiva K, Rao P, Attaluri A, Rao SS. Digital rectal examination is a useful tool for identifying patients with dyssynergia. Clin Gastroenterol Hepatol 2010; 8: 955-60.
11. Rubinkiewicz M, Zarzycki P, Witowski J, et al. Functional outcomes after resections for low rectal tumors: comparison of Transanal with laparoscopic Total Mesorectal excision. BMC Surg 2019; 19: 79.
12. Brunner M, Bittorf B, Matzel K. Modern Strategies for the Treatment of Faecal Incontinence. Zentralbl Chir 2019; 144:190-201.
13. Petros PE, Ulmsten U. An Integral Theory of female urinary incontinence. Acta Obstet Gynecol Scand 1990; 153: 1-78.
14. Muctar S. Atlas der urogynäkologischen und proktologischen Operationstechniken. 1st edition. Georg Thieme Verlag, 2018.

### Multidisciplinary UroGyneProcto Editorial Comment

**To improve the integration among the three segments of the pelvic floor, some of the articles published in Pelviperineology are commented on by Urologists, Gynecologists, Proctologists/Colo Rectal Surgeons or other Specialists, with their critical opinion and a teaching purpose. Differences, similarities and possible relationships between the data presented and what is known in the three fields of competence are stressed, or the absence of any analogy is indicated. The discussion is not a peer review, it concerns concepts, ideas, theories, not the methodology of the presentation.**

**Uro... Gyneco... Procto... Other...**

**Uro...** The correction of fecal incontinence by applying a preanal tape represents an interesting extension of the integral theory of Peter Papa Petros to the posterior compartment of the pelvic floor. The mini-invasiveness of the procedure is quite appealing, though the understanding of the principle according to which this solution should be effective is not immediate. It seems that this technique may produce the same initial sensations of amazement experienced by urologists in the 90s with the proposal of applying a suburethral tape in women with stress urinary incontinence, a technique that was then quickly acquired worldwide. For various causes, stress urinary incontinence derives essentially from the laxity of the vagina or its supporting ligaments due to an intrinsic alteration of collagen. In this context, the pelvic floor muscles do not perform the function of producing direct forces with a stretching of the pelvic organs, as usually happens thanks to the pubococcygeus muscle (PCM), the levator ani and the longitudinal striated muscle of the anus, resulting in failure to stabilize the sphincter activity of the urethra. Similarly, the anal canal complex, as a defecation and retention unit, includes pelvic floor muscles, ligaments and fascia which interact synchronously with the anal sphincter. In this way, the fixation of a tape to the sacrospinal ligaments restores the harmonious functioning of the PCM and internal sphincter of the anus which in resting conditions are minimally stretched in such a way as to prevent the involuntary loss of stool. The intuition of

the authors in applying some principles of the pathophysiology of urinary continence to the posterior pelvic floor is absolutely fascinating, though it requires clinical confirmation over time and with a more significant number of cases.

SALVATORE SIRACUSANO

Professor of Urology, University of L'Aquila, Italy

salvatore.siracusano@univr.it

**Procto...** Anal continence is an extremely complex function based on many factors, some still not fully understood. Unlike urinary continence, the anus must be able to contain and expel a solid, liquid and gaseous content at a desired time and place, a much more demanding task than that of the urinary excretory system. Muctar and Coll.'s research fills with enthusiasm and hope those who trust the Integral Theory (IT) that has allowed both the understanding of the importance of the ligaments of the female pelvis in the onset of urinary incontinence, and to correct it in an apparently very simple way. "In pelvic floor dysfunctions it is typical that anorectal, bladder and pain symptoms often are coexistent. This is because the same ligaments and muscles within the pelvis are responsible for the different functions while ligamentous laxities or shrinkage are responsible for dysfunctions which often are co-existing" (Bernhard Liedl, personal communication). For the treatment of faecal incontinence we have experienced the frustration of experimenting with many surgical techniques, even very expensive ones such as the electrostimulated graciloplasty or the artificial sphincter, with very poor results. It was also tried to apply a sling to support the puborectalis muscle following its course (Latorre F, ....Cervigni M. Pelviperineology 2013; 32: 9-13), without any significant long term success having not correctly interpreted the principles of IT. The conclusion was drawn that, apart from the reconstruction of the sphincters interrupted

by a trauma of various types, the solutions to try to improve the quality of life of patients with fecal incontinence consist mainly in rehabilitation or in Trans Anal Irrigation (TAI). The aim of the operation described in this article is to stabilize the anal canal with a broadly open U-shaped pre-anal tape fixed to the sacrospinal ligaments, so the two backward vectors can better rotate the rectum around the U sling to close it. This work now opens up an extremely interesting path, albeit with the limitation of having only been tested in a small number of female patients. Among the many important elements of the research of Muctar and Coll., in addition to the cleverness of the technique, should be noted the multidisciplinary nature of the Authors who have tried this approach, colorectal surgeons and urogynecologists: a truly interdisciplinary technique. And, once again, Liedl considers that "we are now moving from being guided by Integral Theory to a true Integral Practice increasingly confirmed by evidence-based knowledge. After all, in the footsteps of Karl Popper, the function of a good theory is to offer us a model that must always be corroborated by experimental evidence." We have created more and more evidence for cure of women from their co-existing symptoms by appropriate surgery. So rather than on a theory we should concentrate on the scientific basis of functional anatomy, pathophysiology, surgical principles, which all should be integral".

GIUSEPPE DODI

Colorectal Surgeon, University of Padova, Italy

giuseppe.dodi@unipd.it

---

**Address for Correspondence:** Editorial staff, Padova 35100 Italia, Padova, Italy

**E-mail:** editorial.staff@pelviperineology.org

**Received:** 09 November 2020 **Accepted:** 09 November 2020

©Copyright 2020 by the International Society for Pelviperineology / Pelviperineology published by Galenos Publishing House.



# Magnetic resonance imaging of pudendal nerve: technique and results

✉ VITTORIO PILONI<sup>1,2</sup>, ✉ MATTIA BERGAMASCO<sup>1</sup>, ✉ ANDREA CHIAPPERIN<sup>1</sup>, ✉ MATTEO MAZZUCCO<sup>1</sup>,  
✉ TOMMASO FELICI<sup>2</sup>, ✉ JESSICA ANDREATINI<sup>2</sup>, ✉ NOEMI NUCERA<sup>2</sup>, ✉ ELENA FREDDI<sup>2</sup>

<sup>1</sup>Affidea-Iniziativa Medica, Padua, Italy

<sup>2</sup>Diagnostica Marche, Ancona, Italy

## ABSTRACT

**Objective:** To update the ongoing contribution of magnetic resonance imaging (MRI) in clinical practice

**Materials and Methods:** The imaging series of pelvic MRI examinations carried out in 580 consecutive patients (401 women, 179 men, mean age  $51 \pm 5.3$  year and  $40 \pm 4.4$  year, range: 18-87 and 24.62 year, respectively) in two different diagnostic centres from March 2012 (centre A) and April 2017 (centre B) to October 2020 in patients with chronic pelvic pain, were retrospectively reviewed for evidence of features of pudendal nerve injury. Ten volunteer asymptomatic nulliparous females (mean age:  $24 \pm 2.1$  years, range: 23-27 years) were also included as control group.

**Results:** Pudendal nerve injury could consistently be documented on specific MR pulse sequences as hyperintensity and distortion of the nerve pathway in up to 454 (78.27%) of patients and in none of the control group, indicating the high reliability of the diagnostic criteria and leading to implementation of an established MR imaging protocol.

**Conclusion:** MRI is promising for clinical practice and research in pudendal neuropathy.

**Keywords:** MR-neurography; chronic pelvic pain syndromes; pudendal nerve entrapment

## INTRODUCTION

Since its first description in 1992 and subsequent years,<sup>1,4</sup> magnetic resonance imaging (MRI) of pudendal nerve has rapidly gained wide acceptance by the medical community as a valuable tool for decision-making and therapy planning in patients with chronic pelvic pain syndromes.<sup>5</sup> The term “MR-neurography” has come into practical use to describe the direct depiction of nerves in the body using special modifications of the standard MR imaging technique which allow detection of the signal arising from inside the nerve itself rather than from the surrounding tissues. More specifically, given the intraneural

source of the signal, the images obtained during the examination were thought to provide important information about the internal state of the nerve such as the presence of irritation, nerve swelling, compression, pinch or injury. From the technical point of view, the basic principle for a successful examination includes suppression of the signal coming from the bright fat, so as to better depict the intrinsic signal from nerve water as a hyperintense linear structure. In addition, thanks to recent advances in technology, it has become possible to obtain also contemporary suppression of the signal of similar-appearing surroundings structures, namely the blood in the vascular

**Address for Correspondence:** Vittorio Piloni, Affidea-Iniziativa Medica, Padua, Italy and Diagnostica Marche, Ancona, Italy

**E-mail:** vittorio.piloni@libero.it **ORCID ID:** orcid.org/0000-0003-2447-3825

**Received:** 09 November 2020 **Accepted:** 09 November 2020

©Copyright 2020 by the International Society for Pelviperineology / Pelviperineology published by Galenos Publishing House.



tree,<sup>6</sup> thus eliminating any source of confusion during image interpretation. The current paper will describe the application and criteria for interpretation of a standardized MR-neurography examination which has been matured by us over a nine-year experience in two different imaging diagnostic centres in Italy.

### Imaging centres

At the beginning of March 2012, the MR neurography examination was implemented at the Diagnostic Centre of Affidea- Iniziativa Medica of Monselice, Padua, Italy (center A); subsequently, since April 2017 the same protocol was also applied at the Diagnostica Marche Imaging Center of Osimo Stazione, Ancona, Italy (centre B). All examinations were developed on a 1.5 T, horizontally oriented superconductive scanner (Philips, Multiva model, model 2014, Netherland A; Siemens model 2014, Germany, center B). Although performed by two different technical staffs (M B, A C, MM, centre A; T F, J A, N N, E F, centre B), image analysis and interpretation were conducted by the same radiologist (VP).

### Patient population

Overall, 580 consecutive patients (479 at centre A, 101 at centre B) were enrolled into the study. Of them, 401 were women and 179 men, mean age  $51\pm 5.3$  year and  $40\pm 4.4$  year, range: 18-87 and 24.62 year, respectively. Before imaging, all patients had had a complete physical examination by the referring physicians (urologists, gynecologists, colorectal surgeons, psychiatrists, neurophysiologists, anaesthetists, osteopaths) which was considered mandatory in order to select the optimal imaging protocol in singular cases. Clues for examination included chronic pelvic pain arising from the pelvic floor district, involving the genital area, root of the thighs, groins and gluteal region, more or less associated with one of the following, alone or combined with each another: recurrent cystitis, non bacteric prostatitis, sexual intercourse, direct trauma on the pelvic region from accidental fall and intense sport activity (biking), prolonged sitting position at work, chronic strain at stool, prior pelvic colorectal or lower urinary tract surgery and obstetric trauma. In the sexually active female patients, the issue of vulvodynia received more in depth attention with regard to the characterization of presenting symptoms (see Table 1). More specifically, current findings, compared with those of ten asymptomatic young volunteers as control, are the basis of an ongoing study which has been carried out in search of obtaining better subdivision of symptoms in different categories and discovering any potential correlation with the diagnostic yield of MR imaging.

Patients were instructed to reach the diagnostic room after rectal cleansing with a disposable enema on the day before. The imaging day, during the interview with the radiologist they are

**Table 1. List of symptoms associated with vulvodynia in Thirty-five, consecutive sexually active female patients of the current study**

Presenting symptom	n	%
<b>Pain at or after intercourse</b>	<b>27</b>	<b>77.1</b>
Exaggerate sensitivity (allodynia)	23	65.7
Inability to wear tight-fitting clothes	21	60
Pinprick	18	51.4
Burning and increased urinary frequency	17	48.5
Loss of sensation at penetration and of desire	15	42.8
Electric discharge	16	45.7
Spasm/fascicular contractions (vaginism)	14	40.0
Impatience with physical contact with foreign objects of any kind	12	34.2
Change in bowel habit	8	22.8
n: Number		

helped to fill a specific history-taking form, developed to collect data on symptoms onset, duration, characteristics, irradiations, either aggravating or relieving factors, and adverse impact on voiding, evacuation and sexual activity, if any. Finally, just before starting the examination, patients are asked to empty their bladder in the toilet adjacent to the diagnostic room.

### Image technique

After continuous refinements of the technical setting with the help of the specialist technician of the two manufacturers (Philips and Siemens, respectively), MR imaging was standardized so as to minimize the acquisition time while optimizing the examination's image quality and diagnostic capabilities, i.e. the line sharpness, organ definition and conspicuity of pathology. In particular, during image acquisition, special attention is deserved to obtain correct patient positioning on the diagnostic table in order to avoid any asymmetry which might adversely affect image reading. In practice, with no need for intravenous contrast administration, the body pelvis was firstly depicted by a high-resolution T2-weighted turbo spin echo pulse sequence in the axial, sagittal and coronal planes in all subjects, as reported in previous articles.<sup>7</sup> Optimal visualization of the anatomy in its entirety, including pelvic organs, neural pathways, fat recesses, muscles, fascia and ligaments was considered an integral part of the examination and of utmost importance to rule out any abnormality acting as trigger point responsible of chronic pain syndrome.<sup>8,9</sup> After this, a peripheral pulse device was applied on the 2<sup>nd</sup> finger of the left hand for cardiac gating and pudendal nerve imaging, using the same scan planes. In practice, for evaluating the nerve free of flow and motion artifact formation, a preparatory short-inversion-time inversion-recovery (STIR)

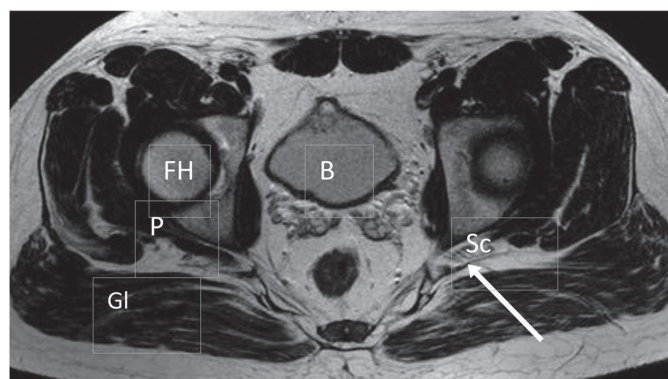
radio frequency pulse sequence is employed which selectively saturate spins located in regions outside the image volume. Such a cardiac-triggered STIR sequence, thanks to a segmented rapid acquisition with relaxation enhancement readout and inversion-recovery delay adjusted to null fat, eliminates signal from flowing blood. As result, by this technique the signal of fat and blood flow is suppressed while living intact that of the excess of water entrapped in the damaged nerve, thus leading to its direct visualization.

### Image analysis

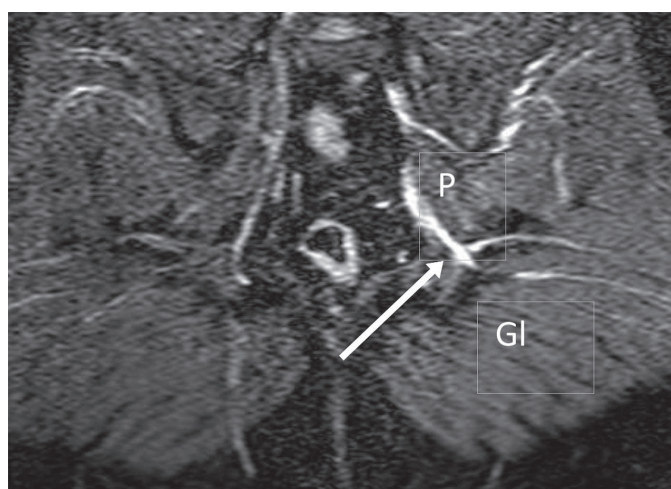
As clearly reported in the literature, basic criteria for the diagnosis of peripheral nerve neuropathy at MR imaging relies on evidence of **increased signal intensity** at the site of nerve damage, with or without presence of any anatomic distortion, entrapment and/or change in caliber. As such, after identification of the paths of the pudendal nerve along its entire course at the level of (1) greater and lesser sciatic foramens, (2) ischial spines and (3) Alcock canal, great relevance by the radiologist is deserved to the analysis of various muscles and vessels in the region of interest. The above in search of any change in their shape, morphology, thickness and signal intensity as potential source of nerve trapping (Figure 1 a and b). Thereafter, the second and most important task, is to detect any sign of signal hyperintensity along the nerve pathway. For this, unlike what occurred at the beginning with our preliminary experience,<sup>7</sup> routine use of the double inversion recovery fat sat and black blood pulse sequences technique, which selectively suppresses the signal of fat and flowing blood, proved critical when assigning the judgment of nerve damage with superior diagnostic confidence (Figure 2 and 3). As it is known, black blood pulse sequences are not affected as STIR sequences by the so called “magic angle artifact” which consists of an increase in signal intensity which occurs when nerve’s collagen orientation to the constant magnetic induction field approaches 55°,<sup>10</sup> thus simulating disease.

### RESULTS

Overall, despite the gender disproportion (69.1% females, 30.9% males), mean age and range of the population examined were not significantly different (mean age: 51±5.3 year and 40±4.4 year, range: 18-87 and 24.62 year, respectively). Conversely, the total amount of examinations performed at centre A overtly exceeded that of centre B (479 vs 101). Regardless of the different duration of the diagnostic activity — almost 5 years longer at center A — a possible explanation must be sought in the different economic cost for the patient, which was only 36.15 euros when covered by the National Health System and no more than 200 euros in case of lack of it at centre A, as opposed to 320



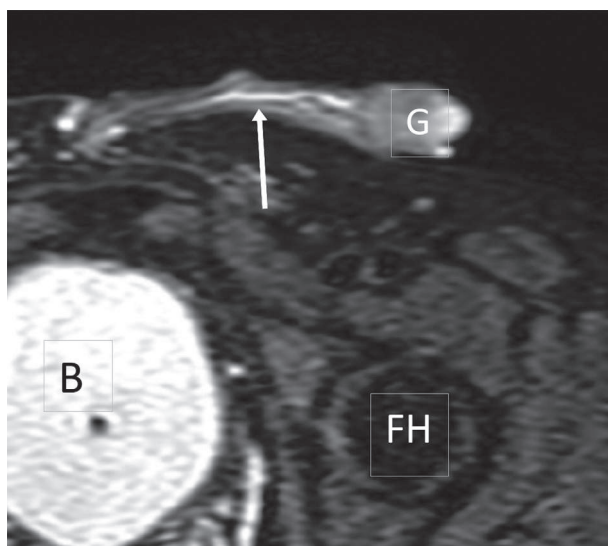
**Figure 1a.** T2 w TSE axial MRI of the pelvis of a forty nine year-old man with history of prior intense biking activity with chronic pain at the left gluteal region extended to the scrotal area and lower left leg: the left piriformis muscle is almost totally replaced by fat (arrow) with entrapment of sciatic and pudendal nerve at the exit of the lesser sciatic foramen TSE: Turbo spin echo, MRI: Magnetic resonance imaging, FH: Femoral head, Gl: Gluteus max muscle, B: Bladder, P: Piriformis muscle, Sc: Sciatic nerve



**Figure 1b.** On the coronal double IR FAT sat\_BB pulse sequence the sciatic nerve (arrow) shows distortion, with increase of signal intensity and caliber

IR: Inversion-recovery, Gl: Gluteus max muscle, P: Piriformis muscle

euros at centre B, due to totally private assistance. Interestingly, however, the trend analysis (Figure 4) of pure quantitative activity reveals that the most striking difference between the two centres concerns the last two years, a period to be considered parallel. As such, different causes should be hypothesized, including the superior collaborative attitude of various referring physicians and their increased interest and curiosity toward any current advance in diagnostic technology, to name a few. Traditionally, both characteristics are known to be more pronounced in the North of Italy (centre A) where physicians keep particular attention to the issues of clinical and social impact resulting



**Figure 2.** Thirty-four year-old man with LUTs and history of acute pain at intercourse, allodynia, pain in the region of corpus spongiosum of urethra and hyperemia of the navicular fossa of the penis. At MR neurography with pulse sequence, typical appearance of increased signal intensity was shown along the course of the dorsal nerve of penis (arrow)

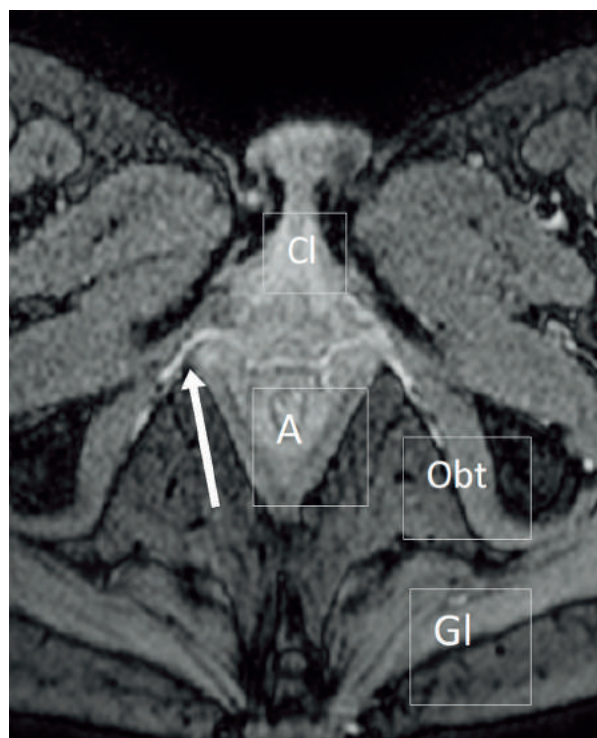
LUT: lower urinary tract symptom, MR: Magnetic resonance, B: Bladder, FH: Femoral head, G: Glans of penis

from adopting any single medical action, namely that of cost-benefit aspect associated with use of innovative technology. On the other hand, the analysis of the diagnostic yield of the examination has shown quite similar results in centre A and B, as follows: (1) Damage of pudendal nerve along the Alcock canal affecting the labial and clitoral branches (female) and scrotal or dorsal penis nerve (male), was the most frequent finding and accounted for 71 and 58 % of cases vs 69 and 55% at centre A and B, respectively; (2) Involvement of the gluteal and sciatic nerves at their encroachment with the greater or lesser sciatic foramen ranked second with 51 and 48% of cases vs 46 and 52%, followed by (3) increased signal intensity of the nerve in close proximity of the ischial spine in 39 and 41% of cases vs 43 and 38%, respectively.

The changes described above were not seen in anyone of the control group.

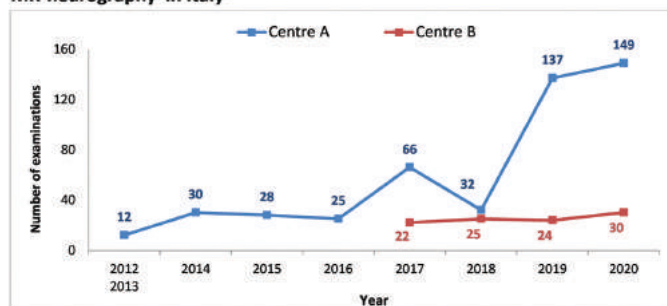
## CONCLUSIONS

The expanding role of MRI places it at the side of neurophysiological tests for the assessment of peripheral nerve pathology.<sup>11</sup> While neurophysiologic testing is required to differentiate between demyelination and axonal degeneration by measuring the electrical activity of nerves according to different parameters, such as latency, amplitude and conduction velocity, the application of MRI, allows direct visualisation of the



**Figure 3.** Forty year-old woman with long standing history of cystitis since childhood and more recent recurrent episodes of pain during intercourse foreplay, followed by urethral burning just after it. At T2 w TSE MRI (not shown), a Bartolin cyst of 8 mm in diameter was found on the right side together with the typical pattern of increased signal intensity involving the posterior labial branches of both sides (arrow) on double IR FAT sat \_ BB pulse sequences TSE: Turbo spin echo, MRI: Magnetic resonance imaging, Obt: Obturator internus muscle, Cl: Clitoris, A: Anal canal, Gl: Gluteus max muscle, IR: Inversion-recovery

**MR-neurography in Italy**



**Figure 4.** Graph showing the trends of time of the MR-neurography examinations from the beginning of activity in centre A (Monselice, Padua) and centre B (Osimo Stazione, Ancona): total number 479 and 101, respectively. Due to the small number of examinations, the activity of 2012 and 2013 at centre A is cumulative MR: Magnetic resonance

peripheral nervous system providing information concerning morphological alteration of the nerve and surrounding tissues. In addition, it can be very useful in monitoring of the response

to therapy. At present, MR neurography which uses fat and flow suppression pulse sequences to remove signal from non-neural structures has become available for routine investigation of pudendal nerve pathology. In the future, the use of diffusion weighted imaging sequences, i.e. **tractography**, which represents the directional motion of intraneural water by colour-coded maps, will provide further information about orientation and degree of architectural organization of the nerve. As such, MR imaging will properly be used to assess also the status of innervated musculature, thus helping in diagnosis, localization of disease and recognition of the degree of nerve damage.

## Ethics

**Ethics Committee Approval:** Retrospective study.

**Informed Consent:** For this type of study formal consent is not required.

**Peer-review:** Externally peer-reviewed.

## DISCLOSURES

**Conflict of Interest:** The authors have no conflicts of interest.

**Financial Disclosure:** The authors of the publication did not receive any financial support by any grant/research sponsor.

## REFERENCES

1. Howe FA, Filler AG, Bell BA, et al. Magnetic resonance neurography. *Magn Reson Med* 1992; 28: 328-38.
2. Filler AG, Kliot M, Howe FA, et al. Application of magnetic resonance neurography in the evaluation of patients with peripheral nerve pathology. *J Neurosurg* 1996; 85: 299-309.
3. Filler AG, Maravilla KR, Tsuruda JS. MR neurography and muscle MR imaging for image diagnosis of disorders affecting the peripheral nerves and musculature. *Neurologic Clinics* 2004; 22: 643-82.
4. Kim S, Choi JY, Huh YM, et al. Role of magnetic resonance imaging in entrapment and compressive neuropathy - what, where, and how to see the peripheral nerves on the musculoskeletal magnetic resonance image: part 1. Overview and lower extremity. *Eur Radiol* 2007; 17: 139-49.
5. Filler AG. Diagnosis and management of pudendal nerves entrapment syndrome: impact of MR neurography and open MR-guided injections. *Neurosurg Q* 2008; 18: 1-6.
6. Mani V, Itskovich VV, Szimtenings M, et al. Rapid extended coverage simultaneous multisection black-blood vessel wall MR imaging. *Radiology* 2004; 232: 281-8.
7. Piloni V, Bergamasco M, Bregolin F, et al. MR imaging of the pudendal nerve: a one-year experience on an outpatient basis. *Pelviperineology* 2014; 33:54-9.
8. Slocumb JC. Neurological factors in chronic pelvic pain: trigger points and the abdominal pelvic pain syndrome. *Am J Obstet Gynaecol* 1984; 149: 536-43.
9. Benson JT, Griffis K. Pudendal neuralgia, a severe pain syndrome. *Am J Obstet Gynecol* 2005; 192: 1663-8.
10. Chappel KE, Robson MD, Stonebridge-Foster A, et al. Magic angle effects in MR neurography. *Am J. Neuroradiol* 2004; 431-40.
11. Lee JC, Yang CC, Kronam BG, et al. Neurophysiologic testing in chronic pelvic pain syndrome: a pilot study. *Urology* 2001; 58: 246-50.



# Prevalence of malignant uterine pathology in utero-vaginal prolapse after vaginal hysterectomy

EDGARDO CASTILLO-PINO<sup>1</sup>, VALENTINA ACEVEDO<sup>1</sup>, NATALIA BENAVIDES<sup>1</sup>, VALERIA ALONSO<sup>1</sup>,  
WASHINGTON LAURÍA<sup>2</sup>

<sup>1</sup>Department of Obstetrics and Gynaecology, Urogynaecology and Pelvic Floor Unit, School of Medicine, University of the Republic, Hospital de Clínicas “Dr. Manuel Quintela”, Montevideo, Uruguay

<sup>2</sup>Department of Obstetrics and Gynaecology, School of Medicine, University of the Republic, Hospital de Clínicas “Dr. Manuel Quintela”, Montevideo, Uruguay

## ABSTRACT

**Objective:** The aim of this study was to establish the prevalence of malignant uterine pathology after vaginal hysterectomy (VH) due to asymptomatic uterovaginal prolapse.

**Materials and Methods:** A descriptive observational cross-sectional study including 110 women with VH indication for hysterocele greater than or equal to POP-Q stage II with negative Pap smear still valid, and with normal transvaginal ultrasound in the past year. Patients with abnormal uterine bleeding or suspected premalignant or malignant uterine disease were excluded. All participants signed an informed consent document. The mean age was 64 year old (SD  $\pm$ 8.84), 85.5% of them being menopausal.

**Results:** 78.2% of histopathological findings did not present any uterine pathology. Endometrial hyperplasia without atypia was found in 11 cases (10%) and endometrial polyps without atypia in 12 cases (10.9%). There were no cases of hyperplasia with atypia. Uterine leiomyoma (25.5%) and focal and diffuse adenomyosis (23.6%) were also found. Only one case had endometrial cancer (0.9%) and there were no cases of cervical cancer.

**Conclusion:** The risk of uterine malignancy after VH due to utero-vaginal prolapse is low. This result may have been affected by the assessment in the year prior to surgery, in keeping with recommendations of ruling out abnormal uterine bleeding and considering Venous thromboembolism (VTE) assessment and cytology of the cervix in the preoperative period. Information regarding the risk of premalignant and malignant pathology of the uterus must be included in the pre-surgery information in the form of a consent document.

**Keywords:** Pelvic organ prolapse; utero-vaginal prolapse; vaginal hysterectomy; uterine preservation; risk of malignancy

## INTRODUCTION

Pelvic organ prolapse (POP) is a common health problem<sup>1</sup> affecting 30 to 50% of women,<sup>2,3</sup> and its prevalence increases with age and parity.<sup>4</sup> Its incidence continues to increase as a

result of the aging of the world's populations and higher rates of obesity in some populations.<sup>4</sup> POP has a negative impact on quality of life of women and it is associated with physical, psychological and sexual problems.<sup>5</sup>

**Address for Correspondence:** Edgardo Castillo-Pino, Department of Obstetrics and Gynaecology, Urogynaecology and Pelvic Floor Unit, School of Medicine, University of the Republic, Hospital de Clínicas “Dr. Manuel Quintela”, Montevideo, Uruguay

**E-mail:** castillopino@gmail.com **ORCID ID:** orcid.org/0000-0003-0241-9625

**Received:** 25 May 2019 **Accepted:** 15 October 2020

Pelvic floor repair surgery is the main therapeutic tool for POP treatment. One of its surgical treatment options is vaginal hysterectomy (VH). The vaginal approach facilitates anatomical entry into the perineum and pelvis, resulting in easy access for the repair of vaginal relaxation. Once pelvic floor reconstruction surgery through the vagina has been defined, the surgical tactic should be selected considering the preservation or exeresis of the uterus.<sup>6</sup> This tactic should be planned with the aim of restoring normal anatomy and adequate support of the vaginal walls and apex.

Utero-vaginal prolapse (UV-POP) is the primary indication for most VHs in Uruguay,<sup>6,7</sup> and worldwide.<sup>8,9</sup> At present, VH is one of the most commonly performed surgical procedures to treat UV-POP and, generally, it is combined with other pelvic floor reconstruction procedures.<sup>10</sup> Hysterocele is usually accompanied by other conditions, such as cystocele, enterocele, rectocele, or relaxation of the pelvic floor. All these conditions must be corrected in the same surgical procedure. Tissue laxity facilitates the performance of hysterectomy through the vagina.

The vaginal removal of the uterus has a very long history, and references have been found, for instance, to conditions in which it had to be removed—in whole or in part—in Soranus of Ephesus, who reported that some authors indicated that it should be removed when the prolapsed uterus was of a blackish hue.<sup>11</sup> Since the first regulated VH was performed in the nineteenth century,<sup>12</sup> VH has been both revered and discredited, but it is still around today.

The reasons for preserving the uterus in women with UV-POP may be the patient's request or the gynaecologist's conviction about the advantages and disadvantages of conservative management.<sup>13-15</sup> Some authors argue that UV-POP is the result rather than the cause of POP, and hysterectomy associated with dissection of the pelvic floor could increase complications.<sup>14,15</sup> Other authors have voiced their concern about the possibility of undiagnosed pathologies or the risk of developing future diseases, such as cancer, if the uterus is not excised.<sup>16,17</sup>

The dissenting opinions in this regard make it necessary to have open discussion with the patient about the pros and cons of hysterectomy or hysteropexy, so that the final decision would be informed, conscious and consensual.

The aim of this study was to establish the prevalence of malignant and premalignant uterine pathology in the histopathological findings in patients who have undergone VH due to UV-POP in a sample of women in our area.

## MATERIALS AND METHODS

A cross-sectional descriptive observational and prospective study was carried out. Patients seeking consultation who were assisted

by the Pelvic Floor Unit medical team between April 1, 2017, and March 31, 2019, were selected. The study was approved by the Ethics Committee of the Hospital de Clínicas of Medical School of Montevideo, University of the Republic. All the participants signed a consent document after being briefed about the study.

The sample included patients with asymptomatic prolapsed uterus greater than or equal to POP-Q stage II with an oncological cervical cytology study with negative Pap stain two years prior to VH and with normal transvaginal ultrasound (TVU) in the past year.

The Pelvic Organ Prolapse Quantification (POP-Q) system uses certain anatomical references such as the hymen, anterior vaginal wall, posterior vaginal wall, total vaginal length, urogenital hiatus, perineal body and cervix or vaginal apex as guiding points. All these references are expressed in cm and measured in proximal (above) or distal (below) in relation to the hymen and are designated as negative or positive respectively. Four prolapse stages from I to IV are established in which the fundamental considerations are the prolapse guiding points and their relation to the hymen expressed in cm and the total length of the vagina.<sup>18</sup>

Patients were excluded if they had UV-POP with a history of abnormal uterine bleeding, a pathological Pap smear or a history of cervical dysplasias or premalignant endometrial lesions, a TVU with an endometrial line greater than 10 mm, a history of malignant ovarian tumours, use of tamoxifen or hormone replacement therapy, and those who did not give their consent for the study.

Out of a total of 133 patients assisted by the Unit team during the study period, 110 women (82.7%) were selected in accordance with the inclusion criteria, and 23 patients (17.3%) were excluded. Of the 23 cases excluded, 11 had a history of genital haemorrhage with premenopausal (three cases) or postmenopausal (eight cases) metrorrhagia, five patients had been diagnosed with cervical dysplasia or squamous intraepithelial lesion (SIL), four of whom were low-grade SIL (L-SIL) and 1 was high-grade SIL (H-SIL), five women had an endometrial line ultrasound measurement greater than 10 mm, and two cases had had clinical and ultrasound diagnoses of adnexial tumour.

The vaginal repair surgery was performed by the same team in all cases. All patients underwent a VH associated with vaginal repair surgery. Vaginal apex suspension was performed to the uterosacral ligaments in all patients in accordance with the McCall culdoplasty technique.<sup>19</sup>

In cases with coexisting stress urinary incontinence, the middle-urethral sling (MUS) technique was associated.<sup>20,21</sup> All extracted uteri were sent for histopathological study.

The following histopathological variables were analysed: presence of endometrial atrophy, endometrial hyperplasia with and without atypia, endometrial cancer, leiomyoma, focal and diffuse adenomyosis, chronic endocervicitis, L-SIL and H-SIL, as well as cervical carcinoma.

The statistical analysis was performed using the Excel 2013 Microsoft Office spreadsheet. For the qualitative variables in the cases where pathologies were detected, a frequency calculation was performed and expressed as absolute frequencies and relative percentage frequencies. For the quantitative variables, the mean, the standard deviation and range were calculated.

## RESULTS

The mean age was 64 years old with a standard deviation of  $\pm 8.84$ , with an age range between 46 and 83 years. The mean body mass index (BMI) was 26.56 kg/m<sup>2</sup> with a standard deviation of  $\pm 3.23$ , with a range between 20.1 and 33.9 kg/m<sup>2</sup>. Most of the patients (85.5%) were postmenopausal (Table 1). None of the patients had family history of endometrial cancer. Smoking was observed in 21.8% of cases. Hypertension was observed in 16.3% and diabetes in 11%. All women presented cystocele associated with hysterocele, while in 13.6% of them it was associated with high rectocele, and with enterocele in 1.8% (Table 1). 4.5% required a MUS technique.

Regarding the hysterocele stage according to POP-Q, 20% was stage II, 51.8% stage III and 28.2% stage IV (Table 2).

As to the histopathological findings, 78.2% of cases did not have any pathology whatsoever. Amongst patients with endometrial pathology, 11 cases (10%) exhibited hyperplasia without atypia and 12 (10.9%) presented endometrial polyp without atypia. No cases of endometrial hyperplasia with atypia were observed. In some patients, an associated benign myometrial pathology was observed, such as uterine leiomyoma in 25.5%, and focal and diffuse adenomyosis in 23.6% of cases (Table 3). In regard

**Table 1. Results**

Variables	Absolute frequency	Relative frequency (%)
Premenopause	16	14.5%
Postmenopause	94	85.5%
Associated cystocele	110	100%
Associated high rectocele	15	13.6%
Associated enterocele	2	1.8%
Bilateral adnexectomy	2	1.8%
Associated MUS surgery	5	4.5%
Hysterocele	110	100%
MUS: Middle-urethral sling		

to malignant pathology, only one (0.9%) of the patient exhibited endometrial cancer, and none of the patients showed a malignant or pre-malignant pathology of the cervix or ovaries (Table 3). The ovaries were included in only two cases (1.8%) during the surgery with normal histological findings.

One case of endometrial cancer was found in a 71-year-old woman with stage IV hysterocele according to POP-Q, asymptomatic, with TVU showing a 1 mm endometrial line, who underwent a VH and bilateral adnexectomy. The histopathological result reports a moderately differentiated adenocarcinoma that extensively infiltrates the cervix and the myometrium as far as the serosa (stage II - 2009 FIGO). Both annexes had a normal histopathological examination.

## DISCUSSION

This study estimated the prevalence of malignant and premalignant uterine pathology in patients with UV-POP who

**Table 2. Hysterocele stage**

Hysterocele stage	Absolute frequency	Relative frequency (%)
POP-Q Stage II	22	20%
POP-Q Stage III	57	51.8%
POP-Q Stage IV	31	28.2%
POP-Q: Pelvic Organ Prolapse Quantification		

**Table 3. Histopathological findings**

	Absolute frequency (n=110)	Relative Frequency (%)
<b>Uterus</b>		
Leiomyomas	28	25.45%
Adenomyosis	26	23.63%
Endometrial atrophy	78	70.9%
EH without atypia	11	10%
EH with atypia	0	0
Polyp without atypia	12	10.9%
Endometrial cancer	1	0.9%
<b>Cervix</b>		
Chronic EC	45	40.9%
Low-grade SIL	0	0
High-grade SIL	0	0
Cervical cancer	0	0
<b>Ovaries</b>		
Normal	2	1.8%
Pathological	0	0
EH: Endometrial hyperplasia, EC: Endocervicitis, SIL: Squamous intraepithelial lesion, n: Number		

underwent VH. All the patients included were asymptomatic, with normal TVU and Pap smears. The prevalence of endometrial cancer was 0.9% and that of cervical cancer was 0%.

However, the inclusion of all precancerous conditions had a prevalence of 21.8%. The premalignant lesions that were observed within the endometrium were hyperplasia and polyps without atypia. No case of atypia was observed. A lesional association with leiomyoma and adenomyosis of approximately 25% was found.

This makes it necessary to consider the importance of a clinical examination and a TVU at a time very close to the surgical procedure lest a detectable pathology is found only after surgery. Anyway, surgical behaviour would not vary in the cases analysed.

According to international literature, the incidence of malignant and premalignant endometrial pathology in asymptomatic women who undergo hysterectomy due to UV-POP ranges between 0.7 and 4.2%.<sup>16,17,22,23</sup>

In a retrospective study<sup>16</sup> the authors included 644 women, 421 of whom were postmenopausal with asymptomatic POP, with 11 patients found to have an organic endometrial pathology (2.6%). As to these cases, only one case of endometrial cancer and 10 cases of hyperplasia were observed.

In another retrospective study<sup>17</sup> unsuspected endometrial cancer was found in four cases (0.8%) out of 517 asymptomatic patients who underwent VH, not to mention the high incidence of hyperplasia.

In another retrospective study,<sup>22</sup> three cases of premalignant and malignant endometrial pathology were observed in 456 asymptomatic patients (0.7%).

These three studies include women with asymptomatic UV POP with no preoperative endometrial assessment.

## CONCLUSIONS

The conclusion is that it is necessary to assess the endometrium before POP surgery by means of TVU followed by an endometrial biopsy in cases of thickened endometrium.

In a retrospective study where they considered the preoperative assessment, Grigoriadis et al.<sup>23</sup> found 14 histopathological abnormalities in the uteri of 333 asymptomatic women who underwent VH (4.2%) and concluded that the incidence of premalignant and malignant gynaecological pathology is low but not negligible.

There is no agreement on the most appropriate course of action in the cases of asymptomatic patients with a thickened endometrium.<sup>24</sup> In a cohort study<sup>25</sup> the authors conclude that in

asymptomatic postmenopausal women with an endometrium  $\geq 11$  mm, an endometrial biopsy should be performed.

Our research considered the value of the TVU, especially in order to assess the risk of unexpected premalignant and malignant endometrial pathology. One of the limitations of our study is that the number of patients analysed is relatively small, but it may be useful for future research in which other risk factors such as smoking and medical comorbidities are considered in addition to age and BMI. One of the strengths of this study is the prospective and cross-sectional design, in addition to the assessment of the risk of not diagnosing a premalignant and malignant pathology of the uterus through clinical assessment and Pap and TVU studies in the preoperative period.

It may be concluded that the prevalence of premalignant and malignant uterine pathology is low, at 0.9%. This leads to the reinforcement of the idea of the importance of a clinical history with no abnormal uterine bleeding, endometrial assessment by TVU close to the date of the surgery and cytological assessment of the cervix through a Pap smear which will allow adequate preoperative diagnosis in the case of a hysterocele. A briefing regarding the risk of premalignant and malignant pathology should be included in the information provided during the preoperative period in the form of a consent document. When conservative management, such as a surgical procedure for uterine fixation (hysteropexy) is chosen, it is imperative to make a careful preoperative assessment to rule out –with the exceptions shown by all studies– a precancerous or cancerous condition of the uterus.

## Ethics

**Ethics Committee Approval:** The study was approved by the Ethics Committee of the Hospital de Clínicas of Medical School of Montevideo, University of the Republic (Date 2017, March 5).

**Informed Consent:** All the participants signed a consent document after being briefed about the study.

**Peer-review:** Editorial choice.

## DISCLOSURES

**Conflict of Interest:** The authors have no conflicts of interest.

**Financial Disclosure:** The authors declared that this study has received no financial support.

## REFERENCES

1. Beck RP, McCormick S, Nordstrom L. A 25-year experience with 519 anterior colporrhaphy procedures. *Obstet Gynecol* 1991; 78: 1011-8.
2. Samuelsson EC, Victor FT, Tibblin G, Svardsudd KF. Signs of genital prolapse in a Swedish population of women 20 to 59 years of age



- and possible related factors. *Am J Obstet Gynecol* 1999; 180: 299-305.
3. Sliker-ten Hove MC, Pool-Goudzwaard AL, Eijkemans MJ, Steegers-Theunissen RP, Burger CW, Vierhout ME. The prevalence of pelvic organ prolapse symptoms and signs and their relation with bladder and bowel disorders in a general female population. *Int Urogynecol J Pelvic Floor Dysfunct* 2009; 20: 1037-45.
  4. Nyggard I, Bradley C, Brandt D. Pelvic organ prolapse in older women: prevalence and risk factors. *Obstet Gynecol* 2004; 104: 489-97.
  5. Grigoriadis T, Athanasiou S, Giannoulis G, Mylona SC, Laurantou D, Antsaklis A. Translation and psychometric evaluation of the Greek short forms of two condition specific quality of life questionnaire for women with pelvic floor disorders: PFDI-20 and PFIQ-7. *Int Urogynecol J* 2013; 24: 2131-44.
  6. Castillo-Pino E. Prolapso de los órganos pélvicos. In: Castillo E, Malfatto G, Pons J, eds. *Uroginecología y Disfunciones del Piso Pélvico*. 2007; 273-86. Primera edición. Montevideo: Oficina del Libro FEFMUR.
  7. Sotero G, Sosa C, Dominguez A, Martinez J. Via de la histeretomia: flujograma de decisiones. *AGO* 2003; 41: 17-20.
  8. Kovac SR. Guidelines to determinate the route of hysterectomy. *Obstet Gynecol* 1995; 85: 18-23.
  9. Cosson M, Querleu D, Subtil D, Switala I, Buchet B, Crepin G. The feasibility of vaginal hysterectomy. *Eur J Obstet Gynecol Reprod Biol* 1996; 64: 95-9.
  10. Lucero M, Shah AD. Vaginal hysterectomy for the prolapsed uterus. *Clin Obstet Gynecol* 2010; 53: 26-39.
  11. Temkin O. *Soranus's Gynecology*. 1956; 207. Baltimore: The Johns Hopkins University Press.
  12. Sauter: Die giinzliche Extirpation der Gebarmutter ohne selbst, entstandenen oder Riinstlich bewirkter Vorfall vorgenommen und gliiicklich vollfiihrt mit niiherer Anleitung, wie diese Operation gemacht werden kann. Constanz, 1822.
  13. Hefni MA, El-Toukhy TA. Long-term outcomes of vaginal sacrospinous colpopexy for marked uterovaginal and vault prolapse. *Eur J Obstet Gynecol Reprod Biol* 2006; 127: 257-63.
  14. Romanzi LJ, Tyagi R. Hysteropexy compared to hysterectomy for uterine prolapse surgery: does durability differ? *Int Urogynecol J* 2012; 23: 625-31.
  15. Dietz V, van der Vaart CH, van der Graaf Y, Heintz P, Schraffordt Koops SE. One year follow-up after sacrospinous hysteropexy and vaginal hysterectomy for uterine descent: a Randomized study. *Int Urogynecol J* 2010; 21: 209-16.
  16. Frick AC, Walters MD, Larkin KS, Barber MD. Risk of unanticipated abnormal gynecologic pathology at the time of hysterectomy for uterovaginal prolapse. *Am J Obstet Gynecol* 2010; 202: 507.e1-4.
  17. Renganathan A, Edwards R, Duckett JR. Uterus conservative prolapse surgery what is the chance of missing a malignancy? *Int Urogynecol J* 2010; 21: 819-21.
  18. Bump RC, Mattiasson A, Bø K, et al. The standardization of terminology of female pelvic organ prolapse and pelvic floor dysfunction. *Am J Obstet Gynecol* 1996; 175: 10-7.
  19. McCall ML. Posterior culdoplasty: surgical correction of enterocele during vaginal hysterectomy. A preliminary report. *Obstet Gynecol* 1957; 10: 595-602.
  20. Ulmsten U, Petros P. Intravaginal slingplasty (IVS): an ambulatory surgical procedure for treatment of female urinary incontinence. *Scand J Urol Nephrol* 1995; 29: 75-82.
  21. Delorme E. [Transobturator urethral suspension: mini-invasive procedure in the treatment of stress urinary incontinence in women]. *Prog Urol* 2001; 11: 1306-13.
  22. Wan OY, Cheung RY, Chan SS, Chung TK. Risk of malignancy in women who underwent hysterectomy for uterine prolapse. *Aust N Z J Obstet Gynaecol* 2013; 53: 190-6.
  23. Grigoriadis T, Valla A, Zacharakis D, Protopapas A, Athanasiou S. Vaginal hysterectomy for uterovaginal prolapse: what is the incidence of concurrent gynecological malignancy? *Int Urogynecol J* 2015; 26: 421-5.
  24. Breijer MC, Peeters JA, Opmeer BC, et al. Capacity of endometrial thickness measurement to diagnose endometrial carcinoma in asymptomatic postmenopausal women: a systematic review and meta-analysis. *Ultrasound Obstet Gynecol* 2012; 40: 621-9.
  25. Smith-Bindman R, Weiss E, Feldstein V. How thick is too thick? When endometrial thickness should prompt biopsy in postmenopausal women without vaginal bleeding. *Ultrasound Obstet Gynecol* 2004; 24: 558-65.



# Teaching module for three midurethral sling complications

## Knowledge of urethral closure/opening mechanisms and pathogenesis of SUI informs management of “difficult” cases

© Bernhard Liedl<sup>1</sup>, © Klaus Goeschen<sup>2</sup>

<sup>1</sup>Zentrum für Rekonstruktive Urogenitalchirurgie, Urologische Klinik-München, Planegg, Germany

<sup>2</sup>Department of Urogynaecology, University of Hannover, Hannover, Germany

### ABSTRACT

We begin this teaching module with a short summary of the mechanism of urethral closure as originally presented in the 1990 “Integral Theory of Female Urinary Incontinence”, the relative roles of muscles and ligaments, how they coordinate to effect urethral closure and evacuation and then relate how these mechanisms impact on surgical technique. Following this, we present three different clinical problems. We have invited comments from surgeons from the International Society of Pelviperineology who are experienced experts in the midurethral sling as to how they would manage these problems.

**Keywords:** Midurethral sling; complications; management

### INTRODUCTION

The midurethral sling (MUS) is now the gold standard operation for cure of stress urinary incontinence. Between 1996 and 2019, it is estimated that 10,000,000 MUS operations have been performed.<sup>1</sup> It is our view that knowledge of urethral closure/opening mechanisms and pathogenesis of stress urinary incontinence (SUI) informs management of “difficult” cases. The pathogenesis of MUS surgery failure comes down to two questions; 1. How does a MUS restore continence? Why does continence fail when the sling is excised? The answers can be found in the initial experimental studies on which all MUS operations are based,<sup>2</sup> and which we summarize below.

#### Normal closure

In Figure 1, A forward vector “pubococcygeus muscle (PCM)” (large arrow) contracts against the pubourethral ligament (PUL) to close

distal urethra; two backward forces (posterior arrows) rotate the bladder around PUL and close the urethra at bladder neck,<sup>2</sup> Figure 1. <https://www.youtube.com/watch?v=3vjx2OvUYe0>

#### Pathogenesis

In Figure 1, A weak PUL lengthens on effort, “L”, cannot support the posterior urethral wall and vagina; both are pulled down to open the urethra from “C” closed, to “O” open. Because PUL is lax, the muscles which contract against it weaken;<sup>3</sup> they cannot close urethra on effort and urine is lost, SUI. Supporting a weak PUL with a hemostat, white arrow, lower ultrasound diagram, Figure 1, prevents PUL stretching (“L”) “<https://youtu.be/0UZuJtajCQU>” exactly as happens with a MUS. The vector closure forces (large arrows) now restored, contract optimally: funnelling disappears and urethra is closed distally and at bladder neck (Figure 1, right lower figure).

**Address for Correspondence:** Bernhard Liedl, Zentrum für Rekonstruktive Urogenitalchirurgie, Urologische Klinik-München, Planegg, Germany

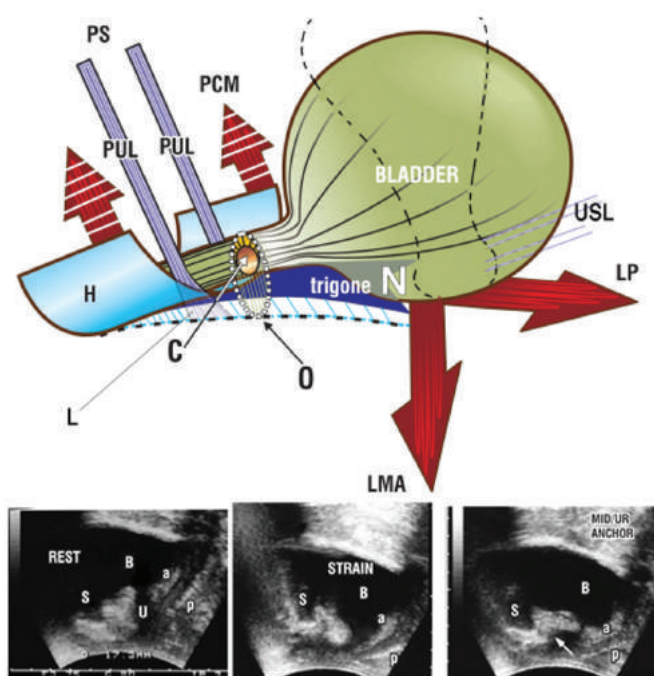
**E-mail:** [bernhard-liedl@t-online.de](mailto:bernhard-liedl@t-online.de) **ORCID ID:** [orcid.org/0000-0002-2646-823X](https://orcid.org/0000-0002-2646-823X)

**Received:** 13 September 2020 **Accepted:** 23 October 2020

©Copyright 2020 by the International Society for Pelviperineology / Pelviperineology published by Galenos Publishing House.

## Urethral opening (micturition)

With reference to Figure 1, the forward vector PCM relaxes (large broken arrow); the posterior vectors levator plate (LP)/longitudinal muscle of the anus (LMA) pull open the trigone and anterior vaginal wall (broken blue lines). The urethra is opened out. This exponentially reduces the resistance to urine flow inversely proportional to the 4<sup>th</sup> power of the radius (Poiseuille's Law). <https://www.youtube.com/watch?v=eiF4G1mk6EA&feature=youtu.be>



**Figure 1.** Pathogenesis of stress urinary incontinence Upper figure on effort, a weak PUL is stretched down by LP/LMA muscle forces to lengthen, "L". PUL+L cannot support the posterior trigone and posterior vaginal wall (broken lines) which are pulled down. Urethral cavity is forcibly opened out from C (closed) to O (open). Both closure mechanisms fail. Urine is lost - SUI.

**Lower figure transperineal ultrasound** reflects upper figure. At rest urethra is closed. On strain, note how the anterior "a" and posterior "p" vaginal walls are stretched back and down; urethra U is forcibly opened out (funnels) at bladder neck and distally. On placement of hemostat at midurethra, (white arrow) bladder neck and distal urethral closure are immediately restored.

B: Bladder; S: Symphysis; LP: Levator plate; LMA: Longitudinal muscle of the anus; SUI: Stress urinary incontinence; PUL: Pubourethral ligament

## How these mechanisms inform management of this case

Excision of tape weakens PUL which elongates, "L", Figure 1. Option 1: make a midline incision, excise intervening tissue, suture the two ends of tape together. Do under spinal. Insert

300 ml saline. Test by asking patient to cough; tighten further if required. Option 2: put in a 2<sup>nd</sup> tape. These options are preferable to a bladder neck sling which is traumatic, prevents the funnelling required to assist micturition. The patient (predictably) will get urinary retention. All bulking does is obstruct urethra. The mechanism of closure is closure by three directional forces acting against a competent PUL. <https://youtu.be/0UZuJtajCQU>.

## REFERENCES

1. Toozs-Hobson P, Cardozo L, Hillard T. Managing pain after synthetic mesh implants in pelvic surgery. *Eur J Obstet Gynecol Reprod Biol* 2019; 234: 49-52.
2. Petros PE, Ulmsten U. An Integral Theory of female urinary incontinence. *Acta Obstet Gynecol Scand* 1990; 69: 7-31.
3. Gordon AM, Huxley AF, Julian FJ. The variation in isometric tension with sarcomere length in vertebrate muscle fibres. *J Physiol* 1966; 184: 170-92.

## DEALING WITH COMPLICATIONS FROM MIDURETHRAL SLING SURGERY

In this section, we present the three complications. We have invited experienced surgeons from International Society of Pelviperineology to provide comments and discuss how they would manage each case.

### 1<sup>st</sup> clinical problem

The 1<sup>st</sup> clinical problem was originally presented in the journal *Int Urogynecol J*, 2020;31:1747-1754. It was reviewed by four International Urogynecological Association experts. Treatment by fascial sling was commonly considered and the literature review outlined the pros and cons of autologous fascia versus donor fascia for this specific case.

A 34-year old para 4 woman had a retropubic tension-free vaginal tape performed as an outpatient procedure and reported complete cure of her SUI. Three years later, she returned with the complaint of new vaginal pain during intercourse. A 1×1 cm mesh exposure was found midline in the vagina. Treatment with topical vaginal estrogen was initiated but unsuccessful. She subsequently underwent excision of the exposed mesh in the operating room. 3 cm of mesh from the midline to the right vaginal sulci was removed. At her post-operative visit, there was no evidence of mesh erosion, but the patient complained that her SUI had returned to baseline.

### Suggested managements

I think that the Hammock-suture is a good method to prevent tape exposure after suburethral tape placement. I know that

almost nobody performs that. But above the functional aspects of this part of the procedure it prevents surgeons to end up with the tape in the wrong layer.

In my experience topical estrogen does not help in mesh exposures of that size, so I would suggest to excise the exposed tape as far as possible to both sides right away. A second tape will help to restore continence in this patient, careful dissection is advised.

Prim. Dr. BURGHARD ABENDSTEIN  
burghard@abendstein.at

I guess that – once again – the laxity of PUL, probably hammock and with high possibility even of the back structures (LP, SUL and CL) have returned to baseline after tape excision. This is the most likely explanation for the recurrence of SUI. To solve this problem firstly the situation should be checked by simulated operations and secondly, if necessary, by repair of hammock and with PIVS.

The second possibility is as follows:

If simulated operations show symptoms of tethered vagina syndrome the remaining tape and scar tissue has to be removed and the laxity of the bladder neck area has to be restored by a muscle skin flap. In about 80% of these cases a concomitant PIVS is necessary. Furthermore about 80% of these patients need a new tension-free vaginal tape (TVT) or transobturator tape (TOT) 6 months later. In both cases the success rate is in a range of 80%.

Prof. Dr. KLAUS GOESCHEN  
klaus.goeschen@googlemail.com

In spite of the wide spectrum of options available for treatments of SUI, treatment fails in 10-15% of patients.<sup>1</sup> With removal of part of the tape, SUI recurs in about 20% of the cases.

How to best manage recurrent SUI after a failed MUS procedure is still a controversial issue. There are different treatment options such as pelvic floor muscle exercises, use of periurethral bulking injections, pubovaginal slings, a new MUS (retropubic or transobturator), an adjustable suburethral sling, salvage spiral slings or even an artificial urinary sphincter.

In a meta-analysis entitled “The surgical management of recurrent stress urinary incontinence: a systematic review”, Nikolopoulos KI, Betschart C and Doumouchtsis SK, from United Kingdom and Switzerland<sup>1</sup> showed that in general, all recurrent procedures have a lower success rate compared with those reported following primary procedures. Colposuspension have a pooled objective cure rate of 76% (95% CI±5.04), MUS procedures – 68.5% (95% CI±3.11), urethral bulking injections – 38% (95% CI±10.7).

We have recently reviewed our data on 40 women with recurrent SUI treated by retro-pubic MUS after failure of primary MUS, and

followed 38 for up to one year.<sup>2</sup> Thirty-five were cured of SUI (92.1%), and three remained with SUI after a year. Obviously, success rates may differ between centers, but, based on our data and considering the strengths and limitations of the various management approaches that we mentioned above, we recommend that retro-pubic MUS may be considered as the treatment of choice for recurrent SUI after failure of primary MUS.

Another issue that arises from this case is that the patient undergoing primary MUS for SUI should be informed about the possible recurrence rate of MUS, in particular when removal of a tape section may become necessary.

Prof. Dr. JACOB BORNSTEIN and Prof. Dr. MENAHEM NEUMAN  
mdjacob@gmail.com menahem.neuman@gmail.com

## REFERENCES

1. Nikolopoulos KI, Betschart C, Doumouchtsis SK. The surgical management of recurrent stress urinary incontinence: a systematic review. *Acta Obstet Gynecol Scand* 2015; 94: 568-76.
2. Abed R, Neuman M, Bornstein J. Outcome of retro-pubic SMUS procedures for recurrent female stress urinary incontinence after surgical failure. In press.

## 2<sup>nd</sup> clinical problem

Fifty-two years old patient who had a TOT 8 years ago. Referred to us for a vesical fistula to the right TOT insertion without SUI. Cystoscopy: transurethral passage of the sling. No vaginal erosion. We have fixed the problem with the total removal of the TOT including the part behind the ischiopubic ramus along the fistula, and reconstruction of the urethra with sutures and I performed a Martius flap to cover. Excellent anatomical result but recurrence of SUI. Physiotherapy failed. In this case, it seems difficult to try a second MUS as we would recommend in the other case. So, what now? Bulking agents or colposuspension?

Dr. PETER VON THEOBOLD  
vonthobald@gmail.com

Your clinical case is very interesting. With my resident, we are at the end of a published work about 37 patients with Martius flap after treatment of complication of tape.

In 9 patients I did Retropubic tape after Martius (tape between Martius flap and the vaginal wall). with no other complication and 70% excellent outcome. 3 patients need a second-time surgery by plication of the tape to get continence. Among the failure of the second tape, 2 patients got artificial sphincter.

Prof. Dr. EMANUEL DELORME  
delormee\_2000@yahoo.fr

I think the Martius flap would be protective. We had a similar case some years ago. We used a Martius graft and placed the tape

around the graft. It worked well, and the patient was continent a year later.

Prof. Dr. PETER PETROS  
pp@kvinno.com

Thank you, but the technique of Martius flap with or without fat is well-known by all of us. It means me the real question is: what is the advantage of Martius to treat the complications of tapes? Is the Martius the good indication to treat a complication of tape after removing of the tape and uretholysis?

The only answer would be a prospective randomized study between surgery of tape's complications with and without Martius flap... and we have not in the literature. Similarly, we can't answer the question with the surgery of visceral pelvic fistulas: no answer in the literature.

The only answer our study brings: it is easier and secure to do dissection to introduce a tape if there is a Martius flap after first-time surgery of tape' complication. But it is more difficult to adjust the tape.

Prof. Dr. EMANUEL DELORME  
delormee\_2000@yahoo.fr

I agree with Emmanuel. I use Marius Flap in case of urethrovaginal or rectovaginal fistula (only fat) or to reconstruct the vagina After too tight colporrhaphy or the perineum after repairs (mainly skin). It isn't efficient for SUI and makes adjusting of the tape difficult.  
Dr. PETER VON THEOBOLD  
vonthobald@gmail.com

As Peter von Theobald knows, bulking agents and colposuspension are no promising maneuvers for cure of SUI. In cases where the urethra is endangered to get injured by a re-operation we had good experiences by using an cystoscope in the urethra whilst dissection. The light shows us the border of the urethral wall and the structures in the surrounding.

I would recommend to start with a midline elliptical incision under cystoscopy to create a bridge (like Max Haverfield's description below). Then visualisation of the bladder neck and base on both sides with the cystoscope light and insertion of a transobturator tape out/in. Doing all the steps under visual light control reduces the danger of urethra or bladder perforation tremendously.

Prof. Dr. KLAUS GOESCHEN  
klaus.goeschen@googlemail.com

### 3<sup>rd</sup> clinical problem

This case was published in Pelviperineology in 2012.

Following a TVT MUS 4 years earlier, (initially deemed 85% successful), a 53-year woman presented with gradual deterioration of her incontinence. By mid 2009, the patient

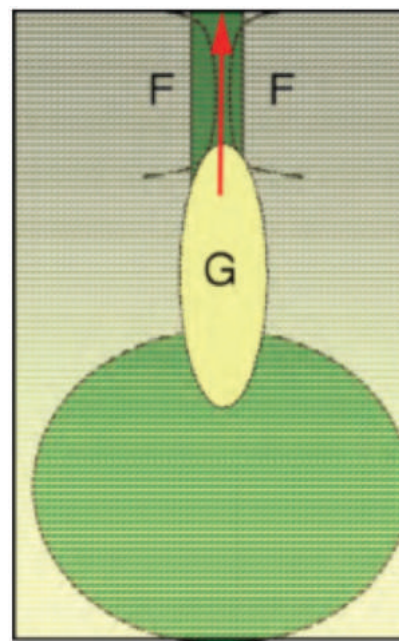
was leaking 800-1000 ml/24 hours. There was no urine leak at rest or at night, but she leaked on the slightest effort during the day. On ultrasound examination, the whole posterior urethral wall was opened out during straining, with observed urine loss. The maximal urethral closure pressure was 60 cm H<sub>2</sub>O, with no urodynamically detected detrusor overactivity.

At operation, the urethra was paper thin, 1,5 cm wide, fragile and attached to a wide loose TVT tape partly embedded in the urethral wall. Two small holes were made during tape removal and repaired. A "bridge/flap" of full thickness vaginal mucosa (3x1cm) Figure 2, was brought up to protect the thin urethral wall. A Tissue Fixation System (TFS) adjustable MUS was then inserted over the vaginal flap, then covered by approximation of the lateral vaginal edges to form a double layer, Figure 3. The patient was entirely cured at 12 months review, with no vaginal retention cysts evident. Though midurethral tapes generally enhance the urethral closure mechanisms, a loosely applied tape may fibrose in such a way as to "hold open" the urethra and prevent closure.

Dr. MAX HAVERFIELD  
ssleep@bigpond.com.au

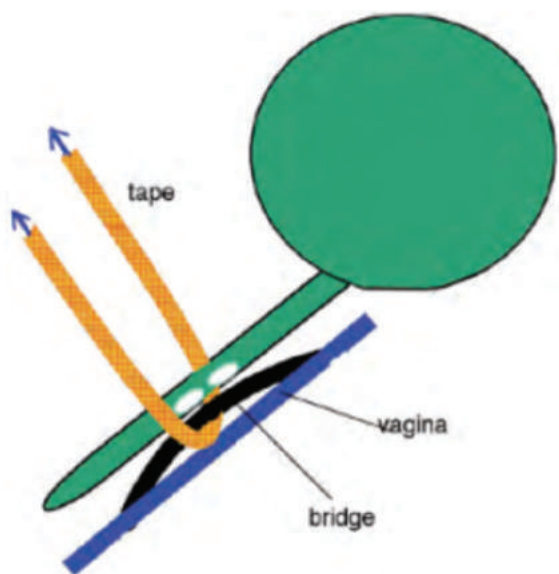
To insert the Tape over the bridge is an excellent idea and a simple and safe procedure.

His last comment "Though midurethral tapes generally enhance the urethral closure mechanisms, a loosely applied tape may



**Figure 2.** Creation of vaginal skin graft "G" ("bridge") to cover urethra. The sling sits over the graft. F=2 cm flaps created to cover the midurethral sling. Arrow indicates how the graft is pulled upwards.

F: Fascia, G: Graft



**Figure 3.** Tape and graft-sagittal view. The white ovals indicate the position of the holes. The vaginal graft (“bridge”) covers the urethra protecting it from the applied tape. Both are overlaid by the vaginal flaps “vagina”.

fibrose in such a way as to “hold open” the urethra and prevent closure” is in my opinion tremendous important for the success of MUS operations. If the tape is to “tension free” = loose, as mentioned by Max Haverfield, it can slip and create fibrosis with the consequences described above. If the tape is too fast, it compresses the urethra with the consequence of urine obstruction, urge and residual urine. Therefore, in order to find

the right “tension free” position of the tape after insertion, we always perform the following procedure:

If a combined repair of the pelvic floor is necessary (due to cystocele, entero/rectocele, with or without hysterectomy) the MUS operation is always the last step.

At the end of the MUS operation, that means after suturing all incisions (midline, paraurethral, possibly hammock an/or external urethral ligament incisions, additional incisions for cystocele, entero/rectocele) we fill the bladder with 300 ml saline, insert an Hegar 8 into the urethra, move softly the Hegar just a bit downwards and adjust the tape carefully to the urethra. After removing the Hegar we retropubically tap on the bladder from above. If no leaking is observed, the tape is in the right position. We cut the external tape ends and finalise the operation.

If tapping causes leaking, we insert the Hegar into the urethra again and repeat the procedure until leaking stops.

Prof. Dr. KLAUS GOESCHEN

klaus.goeschen@googlemail.com

### Ethics

**Peer-review:** Externally peer-reviewed.

### DISCLOSURES

**Conflict of Interest:** There was no conflict of interest. For this type of study formal consent is not required.

**Financial Disclosure:** The authors of the publication did not receive any financial support by any grant/research sponsor.

## AUTHOR INDEX

Valentina Acevedo .....	137	Bernhard Liedl .....	55, 142
Eren Akbaba .....	77	Paweł Malicki .....	24, 27, 34
Valeria Alonso .....	137	Maria Grazia Matarazzo .....	90
Jessica Andreatini .....	132	Matteo Mazzucco .....	132
Natalia Benavides .....	137	Andrea Meneghini .....	99
Mattia Bergamasco .....	132	Nicola Meneghini .....	99
Jacob Bornstein .....	68, 115	Sidi Muctar .....	123
Sandy Bornstein .....	115	Andrei I. Müller-Funogea .....	123
Aysun Camuzcuoğlu .....	77	Noemi Nucera .....	132
Hakan Camuzcuoğlu .....	77	Stefan Ollig .....	60, 85
Edgardo Castillo-Pino .....	137	Jacques Oosthuizen .....	50
Andrea Chiapperin .....	134	Eilam Palzur .....	68
Antonio Cianci .....	90	Peter Petros .....	40, 107, 115
Jarosław Ciechowski .....	24, 27, 34	Vittorio Piloni .....	132
Salvatore Di Pasqua .....	90	Fatih Pirinççi .....	77
Giuseppe Dodi .....	105, 132	Mary Lynne Van Poelgeest-Pomfret .....	65
Anne De Vries .....	85	Giuseppe Sarpietro .....	90
Tommaso Felici .....	132	Burak Sezgin .....	77
Maria Fiore .....	90	Salvatore Siracusano .....	132
Nicolas Fischer .....	123	Ahmet Akın Sivaslıoğlu .....	77
Elena Freddi .....	132	Francesco Sgalambro .....	90
Richard Gevirtz .....	13	Andreas Süsse .....	60
Klaus Goeschen .....	42, 55, 142	Michael Swash .....	107
İlker Gülbaşaran .....	96	Eda Adeviye Şahin .....	77
Franziska C. Hemptenmacher .....	60, 85	Jiasong Tang .....	18
Marek Jantos .....	2, 3	Aytekin Tokmak .....	96
Xiao Juan Lv .....	18	Gaetano Valenti .....	90
James Kent .....	50	Alexander Wagner .....	85
Dirk G. Kieback .....	60, 85	Celia Wilkinson .....	50
Martin Kowallik .....	123	Lin Zhang .....	18
Washington Lauría .....	137		

## SUBJECT INDEX

5-year results.....	60	Minimal invasive surgery .....	123
6 months results .....	85	Minimally invasive.....	85
Alpha-adrenergic blocker .....	96	Monofilament .....	85
Anatomy.....	99, 123	MR-neurography.....	132
Andreas Vesalius .....	99	Myofascial pain.....	3
Apical prolapse .....	77	Myofascial pain trigger points.....	13
Bilateral sacrospinous colposuspension .....	85	Native tissue repair.....	77
Biomechanical model .....	24	Neuroproliferation.....	68
Bladder pain syndrome.....	3	Nocturia .....	107
Bony pelvis.....	55	OAB.....	107
Care of the scar tissue.....	27	Operative therapy.....	60, 85
Catenary .....	24	Outcome.....	60, 85
Center of coordination (CC) .....	24	Padua anatomy theate .....	99
Center of fusion (CF) .....	24	Pain mapping .....	3
Cervical prolapse.....	85	Pelvic congestion syndrome.....	149
Chronic pelvic pain.....	3, 55, 107, 115	Pelvic floor dysfunction .....	34, 90, 115
Chronic pelvic pain syndromes.....	132	Pelvic floor magnetic stimulation .....	18
Chronic urogenital pain.....	3, 27, 34	Pelvic floor muscle strength .....	90
Complications .....	60, 85, 142	Pelvic organ prolapse .....	18, 55, 137
De Humani Corporis Fabrica .....	99	Pelvic pain.....	149
Densification .....	24	Pelvic sensitization .....	27
Dysuria .....	27	Perineometry .....	90
Electrical stimulation.....	18	Porosity .....	85
Episiotomy .....	27	Posterior fornix syndrome.....	55, 107
Faecal incontinence.....	123	Postpartum .....	18
Fascial manipulation .....	24, 27	Provoked vulvodynia .....	68, 115
Fascial manipulation .....	34	Pubococcygeus test.....	90
Fowler's syndrome.....	107	Pudendal nerve entrapment.....	132
Frontispiece.....	99	Pudendal nerve neuralgia.....	27
Haemorrhoids.....	50	Rectum .....	123
Heparanase .....	68	Renal nutcracker phenomenon .....	149
HexaPro mesh.....	85	Renal nutcracker syndrome .....	149
High uterosacral ligament suspension .....	77	Renal vein .....	149
Hygiene .....	50	Risk of malignancy .....	137
Hyperinnervation.....	68	Single incision.....	85
Internal dysfunction .....	24	Sphincter.....	123
Laparoscopy .....	77	Surgery .....	60, 85
Management.....	142	Surgery .....	85
Mast cell .....	68	Sympathetic muscle innervation .....	13
May-Thurner syndrome.....	149	Tape.....	85
Midurethral sling.....	142	Transperineal bilateral sacrospinous colpopfixation .....	60



## SUBJECT INDEX

Treatment .....	50	Vaginal hysterectomy .....	96, 137
Underactive bladder .....	107	Vaginal sling placement .....	60
Upright posture.....	55	Vaginal vault prolapse.....	60, 85
Urinary retention.....	96, 107	Venous congestion.....	149
Uterine preservation.....	137	Vestibulectomy .....	68
Uterine prolapse .....	85	Vestibulitis.....	115
Utero-vaginal prolapse .....	137	Vestibulodynia .....	115
Vaginal delivery .....	90	Vulvodynia .....	3, 34

A MINIMALLY INVASIVE  
AND EFFECTIVE BRIDGE BETWEEN  
CONSERVATIVE THERAPY AND SURGERY  
FOR BOWEL INCONTINENCE

secca®



**EFFICIENT**

Performed in an outpatient setting

**SAFE**

Less than 1% complication rate\*

**EFFECTIVE**

Up to 84% of patients experienced  
significant improvement\*

**QUICK RECOVERY**

Return to normal activities in a few days

SECCA PATIENTS } experienced  
**84%** } significant  
improvement

Greater  
Quality  
of Life

**Less than 1%**  
complications




Distributore esclusivo:

**INNOVA**  
medica

Surgical technique adaptable to the individual anatomy  
for the treatment of female stress incontinence with

# SERASIS® JK-Tape®



## Advantages

extra slim tape for  
incontinence surgery

suitable for urethras of all  
lengths and mobility




anatomically adapted  
geometry

adjustability

lies reliably flat beneath  
the urethra, thanks to buffer  
zones

reduces the risk of a  
'tethered tape'

keeps its shape under tension



SERAG-WIESSNER GmbH & Co. KG  
Zum Kugelfang 8 - 12  
95119 Naila/Germany

+ 49 9282 937-0  
+ 49 9282 937-9369

info@serag-wiessner.de  
www.serag-wiessner.de

